

immediate management of the obstetric fistula

kees waaldijk

babbar ruga fistula hospital

the management of the obstetric fistula starts the moment the leaking of urine is manifest

- prevention of the fistula is a utopia for at least another century
- prevention of the woman from becoming an outcast is very well feasible by the immediate management by:
catheter and/or early closure
- waiting 3 months is malpractice since one allows the woman to become an outcast by pure neglect of the fistula

the management of the obstetric fistula starts the moment the leaking of urine is manifest

if no fistula expertise available:

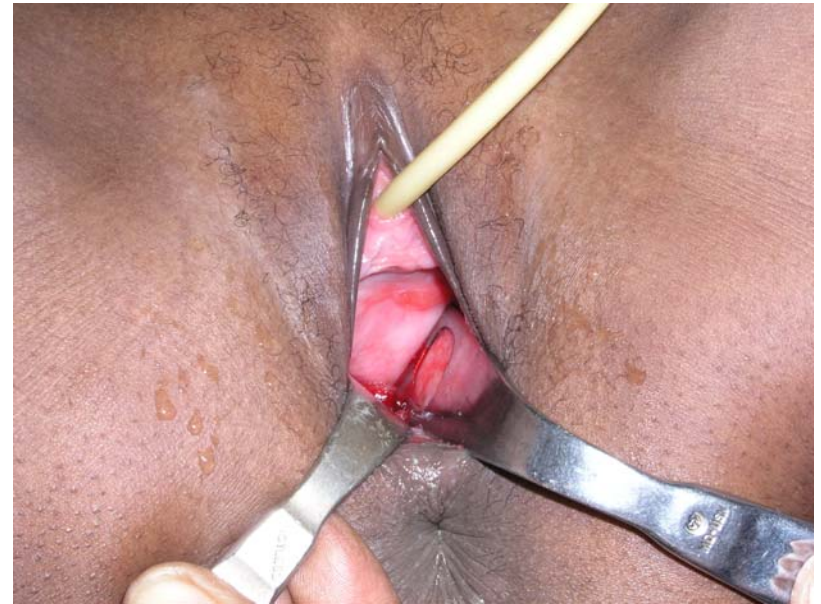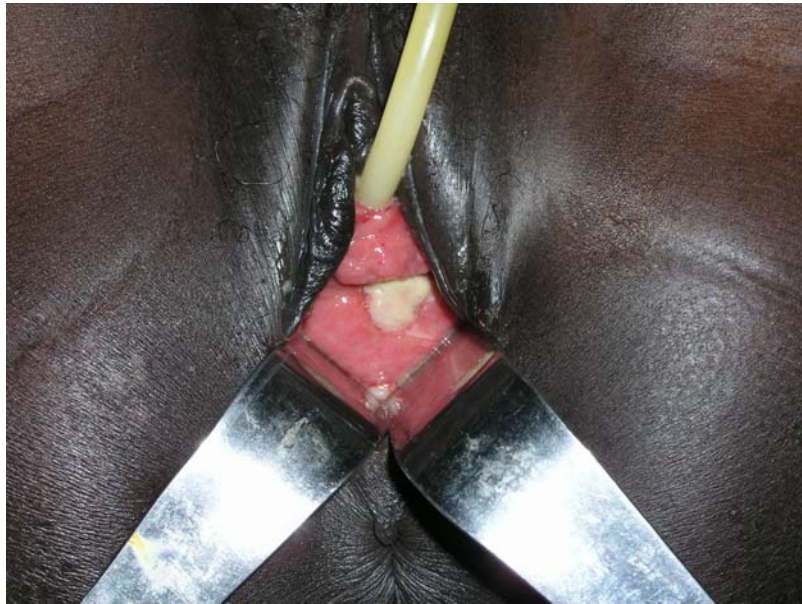- do not waste valuable time
- insert FOLEY catheter Ch 18 for 4 weeks
- high oral fluid intake of 6-8 liters per day
- ensure free urine drainage preferably free into pot
- no routine antibiotics since it is pressure necrosis
- antibiotics only on indication, e.g. puerperal sepsis
- immediate mobilization of patient, if necessary with stick
- oral iron preparations; sytemic if needed
- high protein diet

the management of the obstetric fistula starts the moment the leaking of urine is manifest

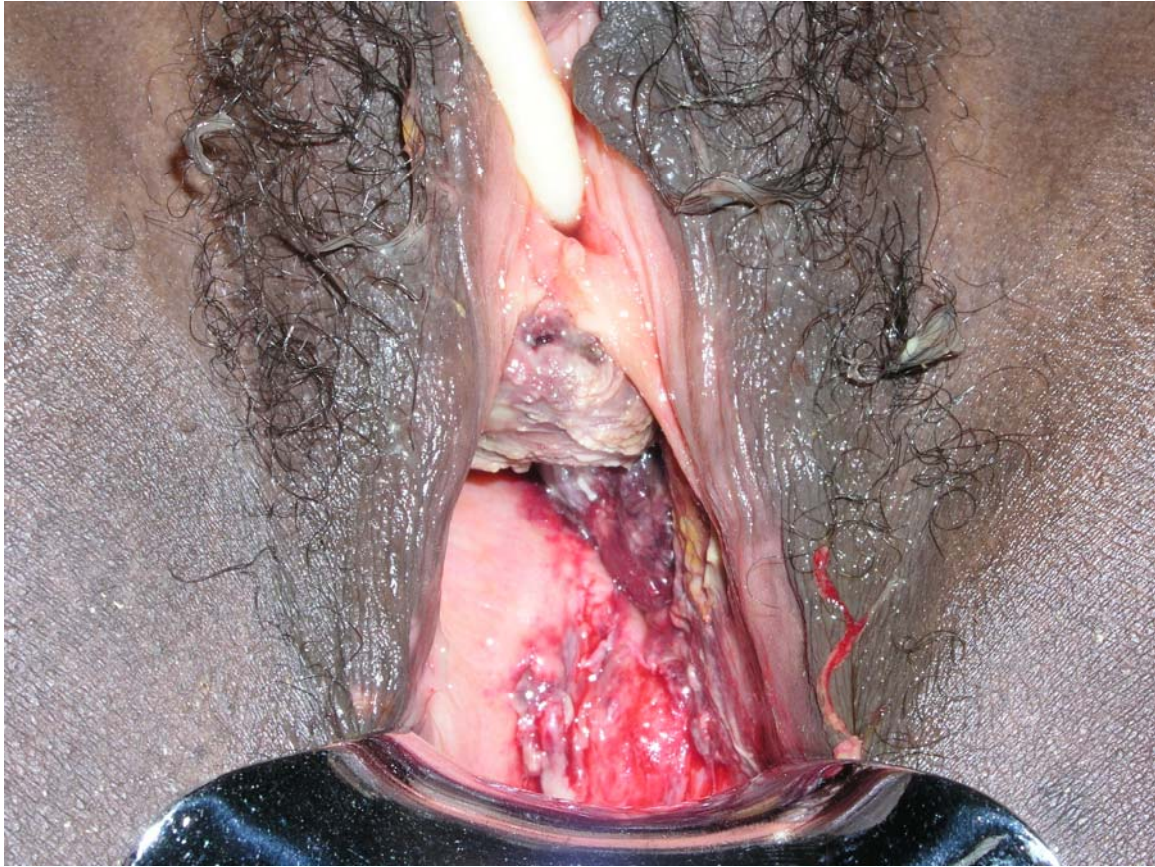
if surgical expertise available

- vaginal examination for assessment
- insert FOLEY catheter Ch 18
- examine patient_fistula once a week
- if it seems healing leave catheter in situ
- if not healing excise slough and prepare for early closure
- as soon as wound clean perform an early closure
- mobilize patient at all times
- attend to the other needs of the patient

indwelling bladder catheter and high oral fluid intake

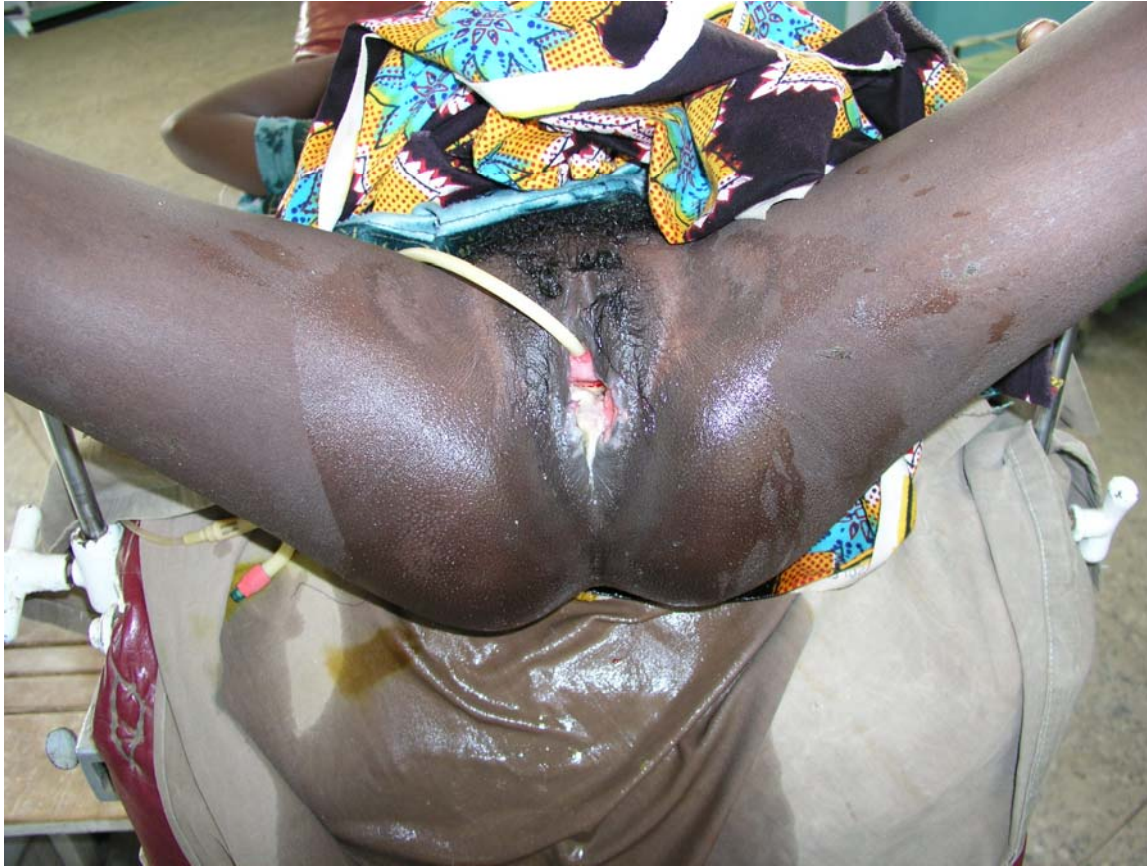

indwelling FOLEY catheter



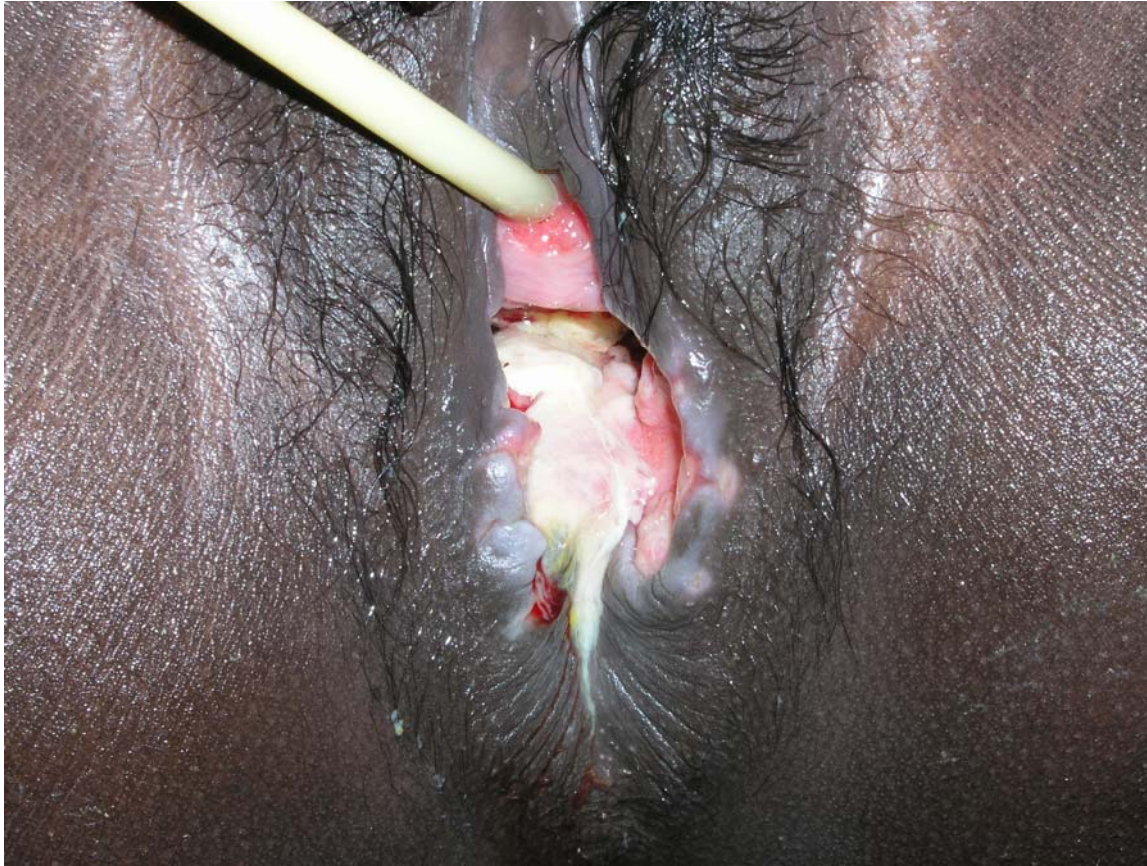catheter treatment

slough sphincter ani rupture



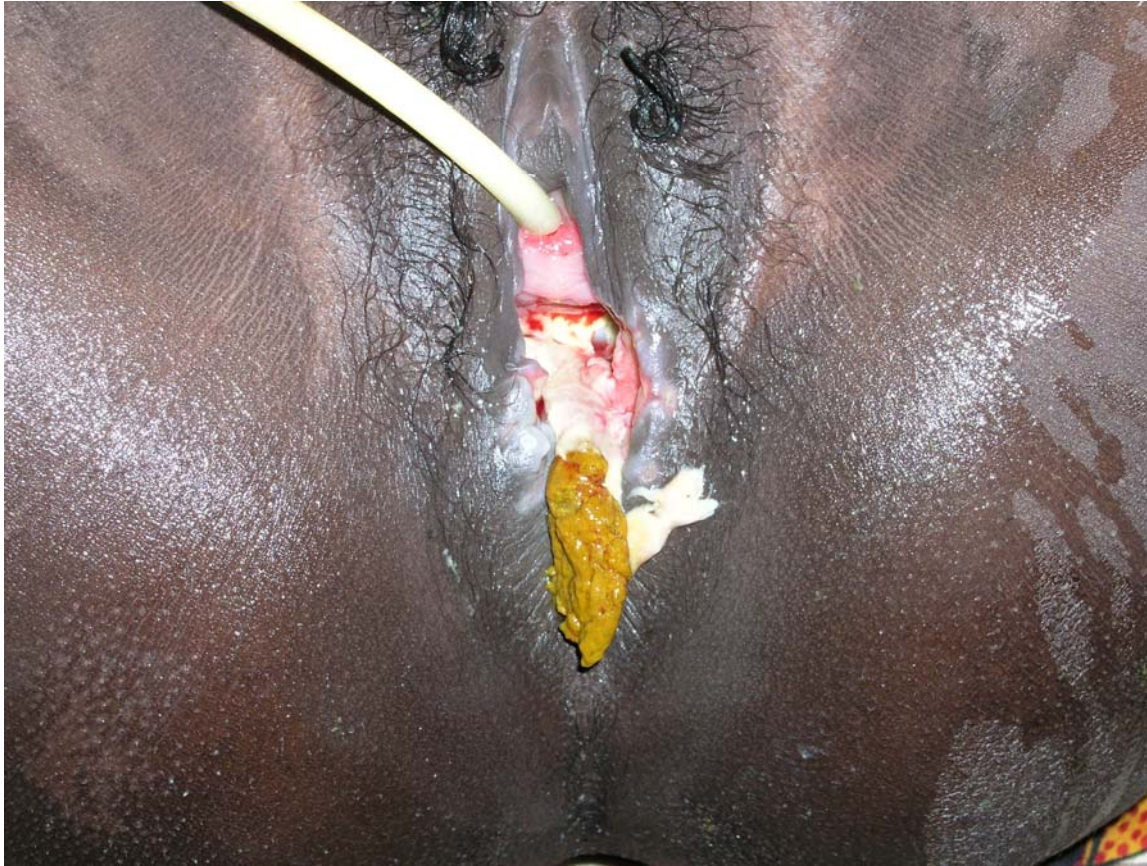catheter treatment

slough sphincter ani rupture



catheter treatment

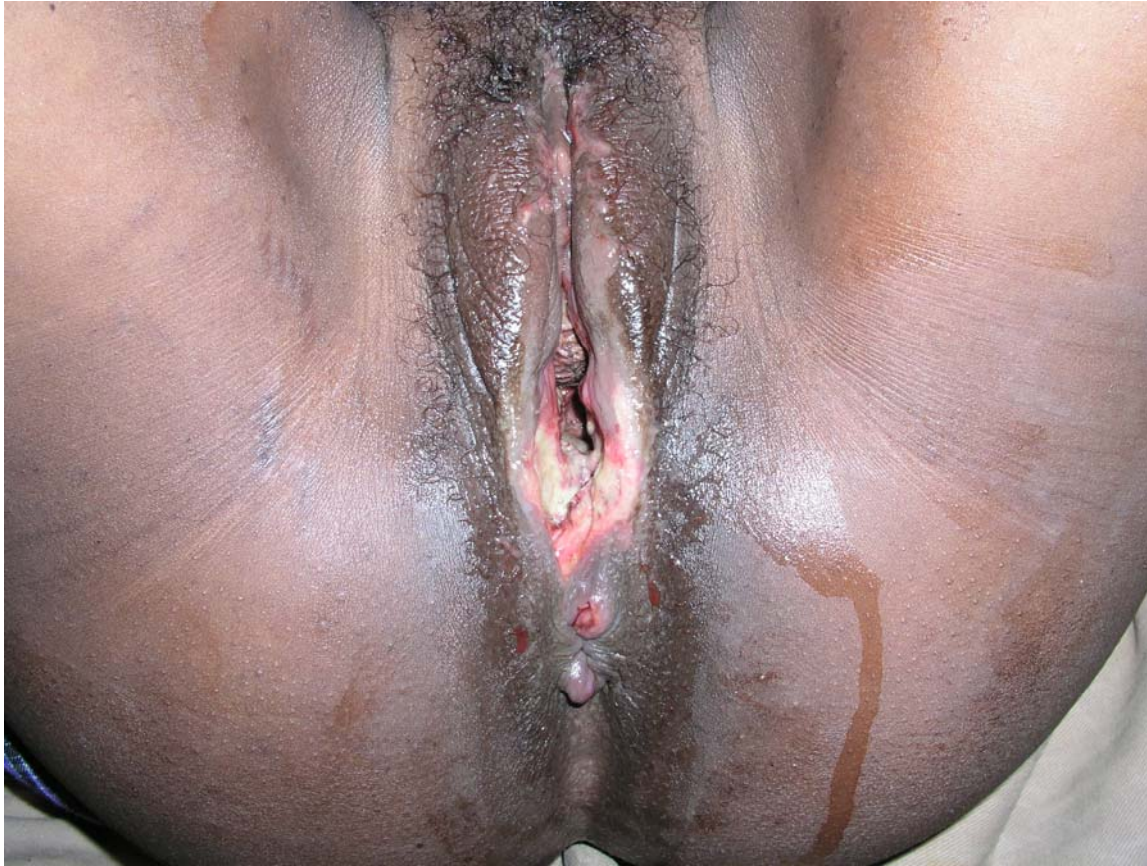excision of slough sphincter ani rupture



catheter treatment

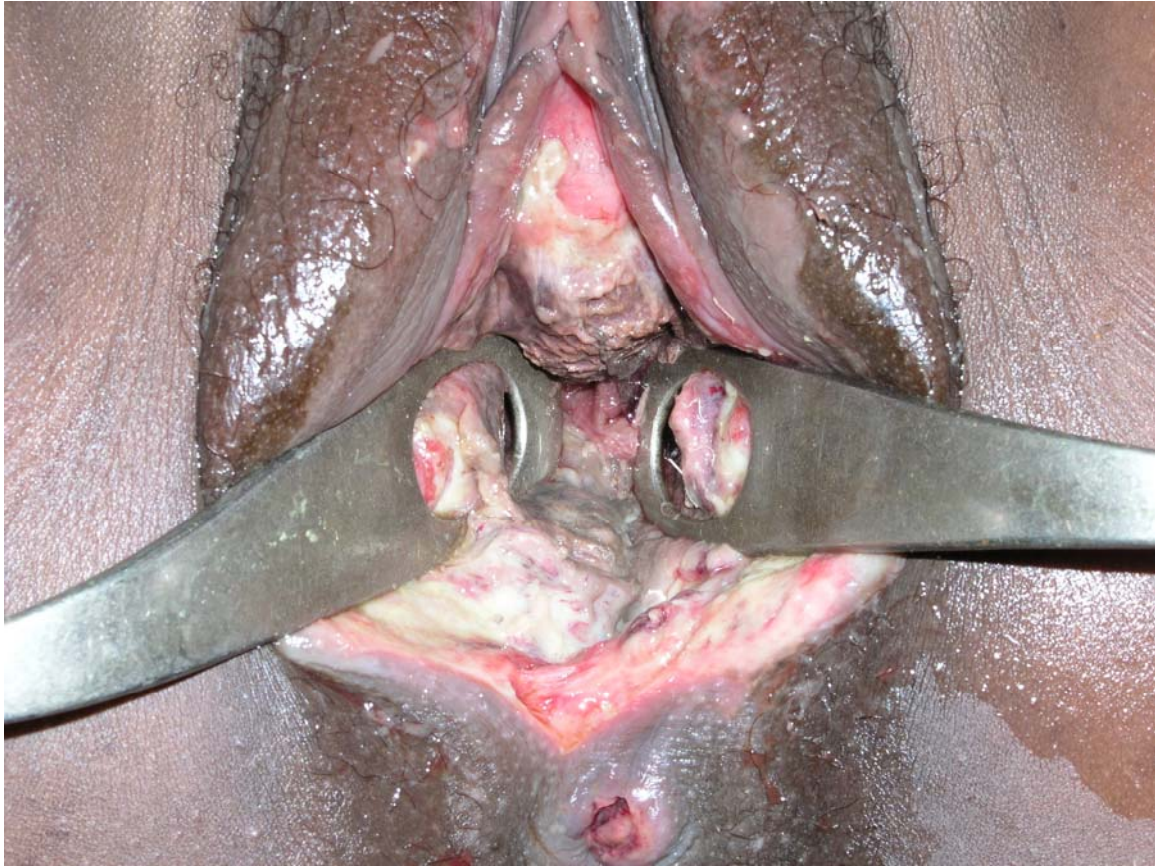
necrosis

saddle anesthesia



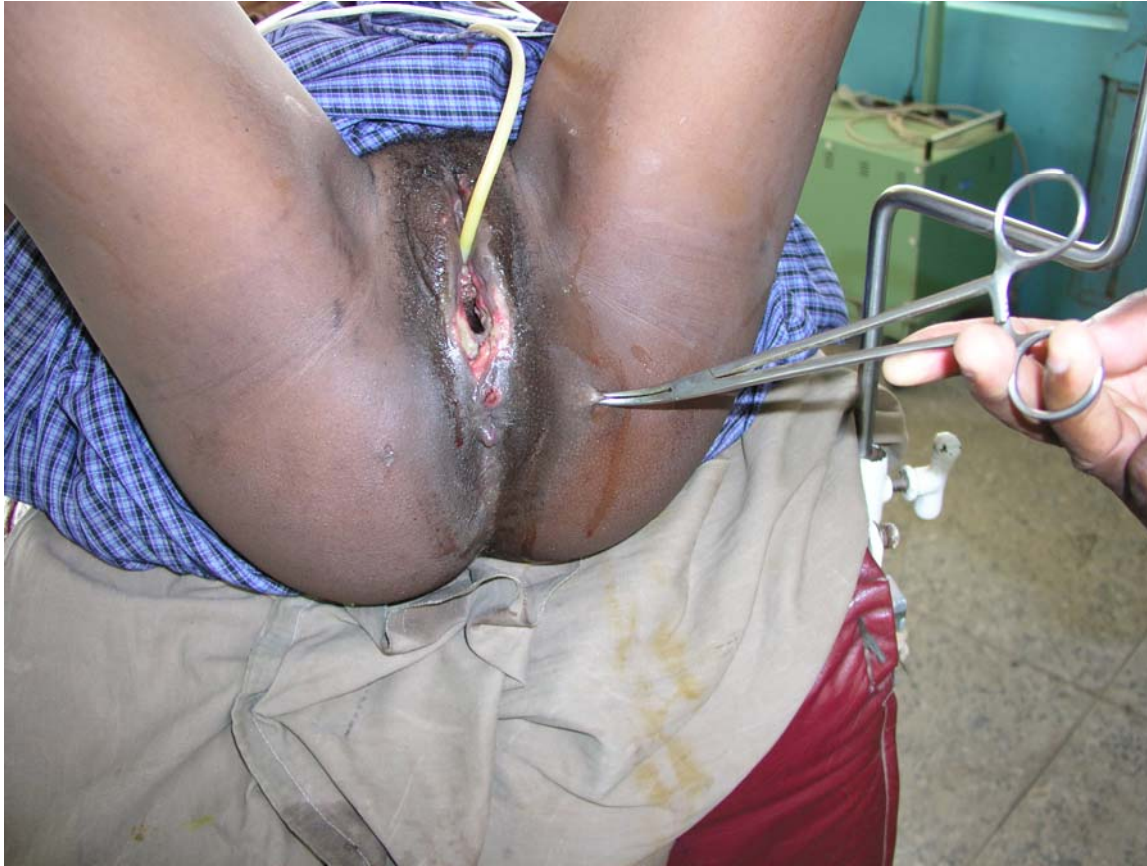catheter treatment

necrosis



catheter treatment

saddle anesthesia



postpartum atonic bladder

leaking urine as if a fistula

- leaking urine thru external urethra opening
- suprapubic mass
- anterior vagina wall bulging into vagina
- bladder overdistended
- more than 750 and up to 2,500 ml of urine in bladder
- vesicalization of proximal urethra

- with/without anterior vagina wall trauma_fistula
- with/without stool_flatus incontinence

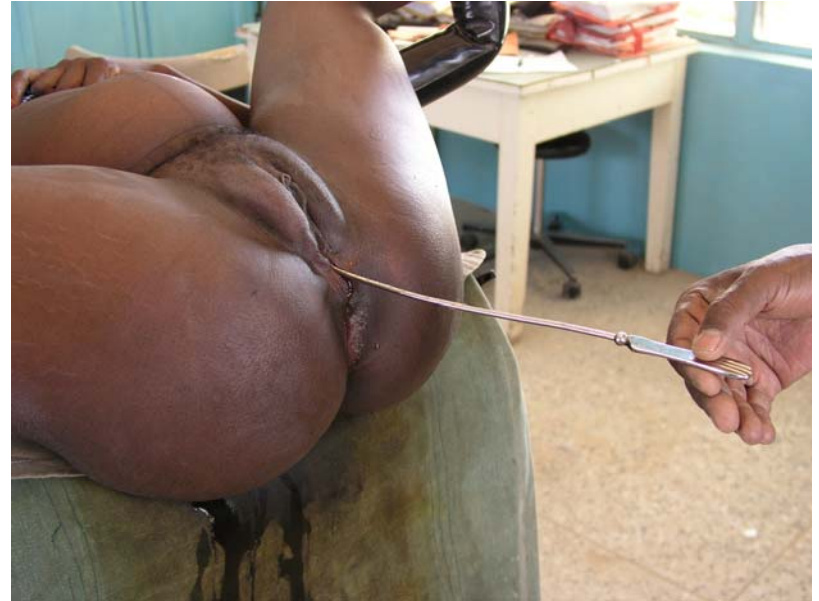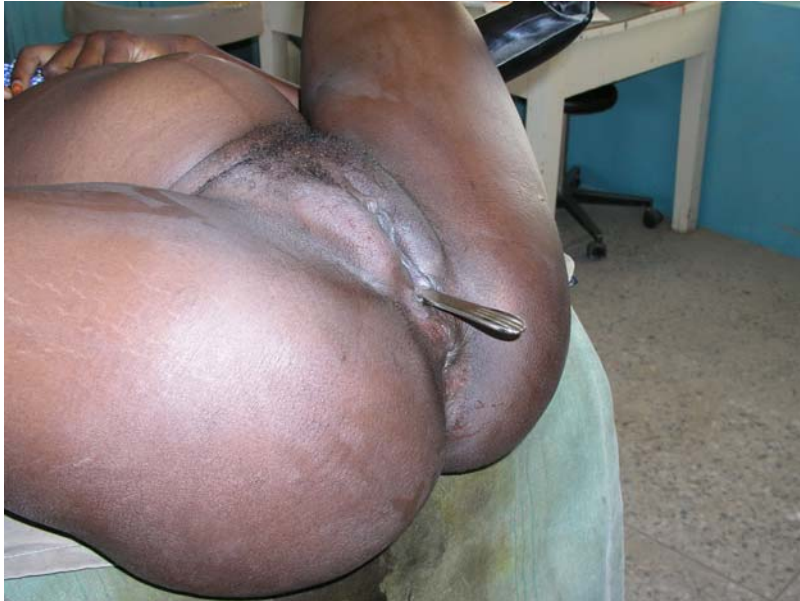atonic bladder

suprapubic mass



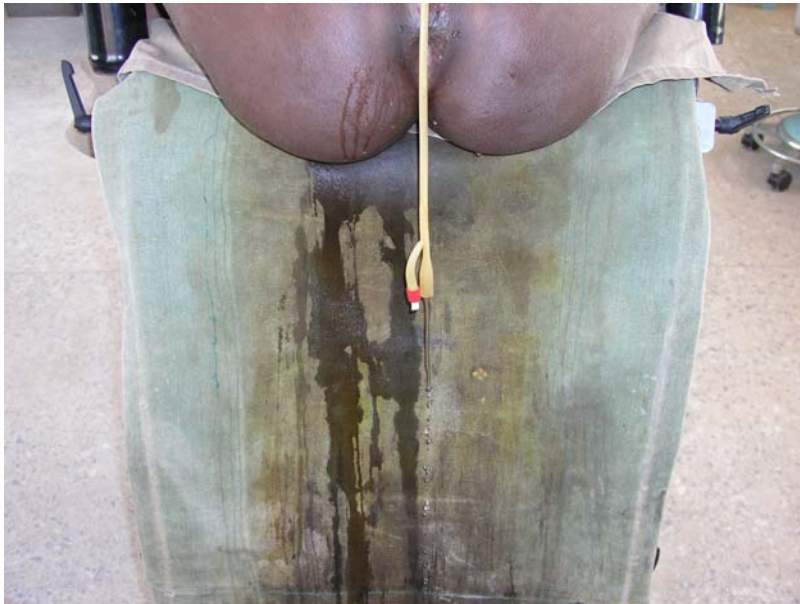atonic bladder

bladder overdistended



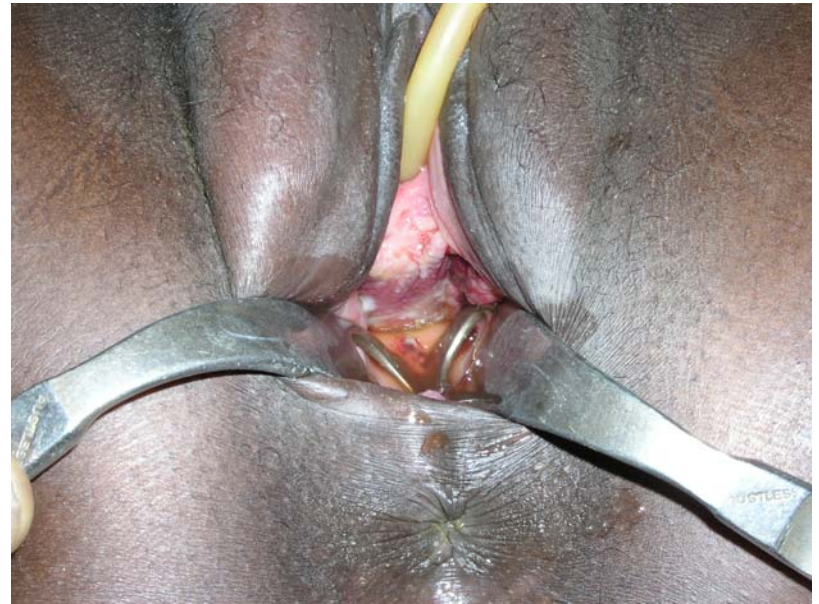atonic bladder

bladder overfilled



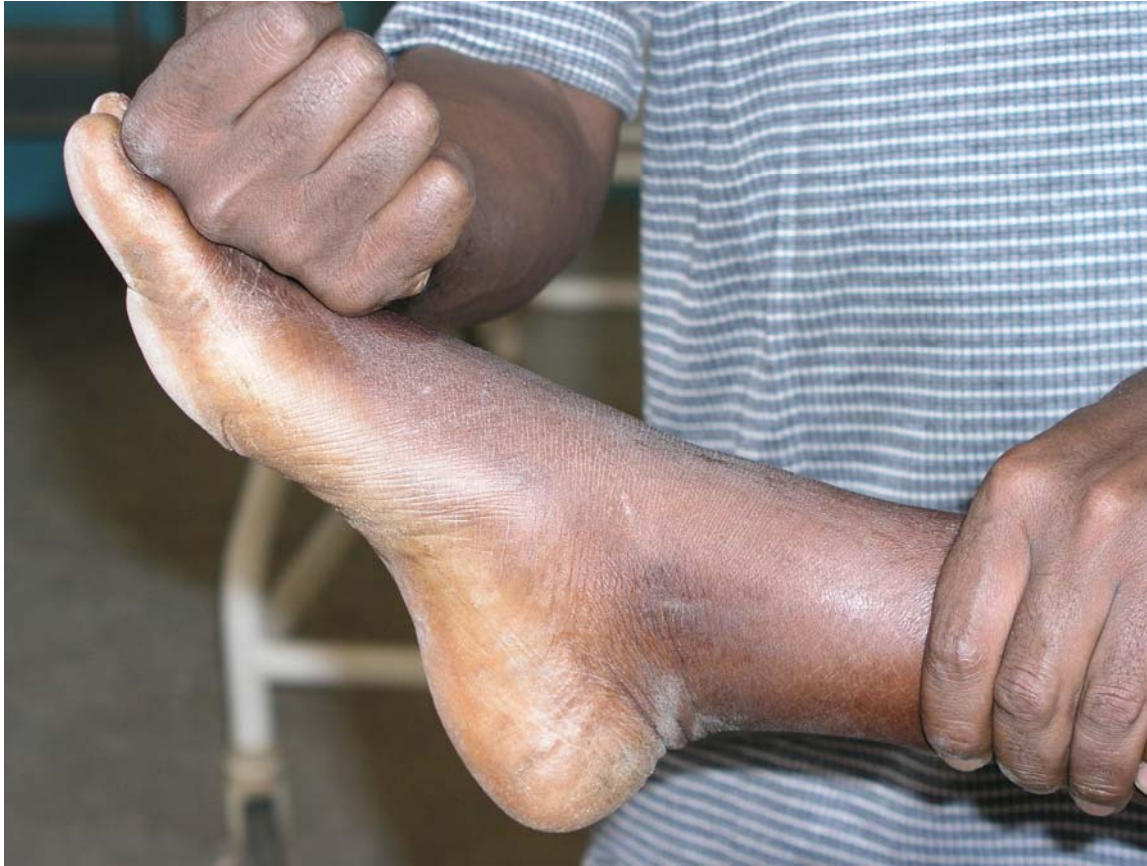atonic bladder

vulva_anterior vagina wall trauma



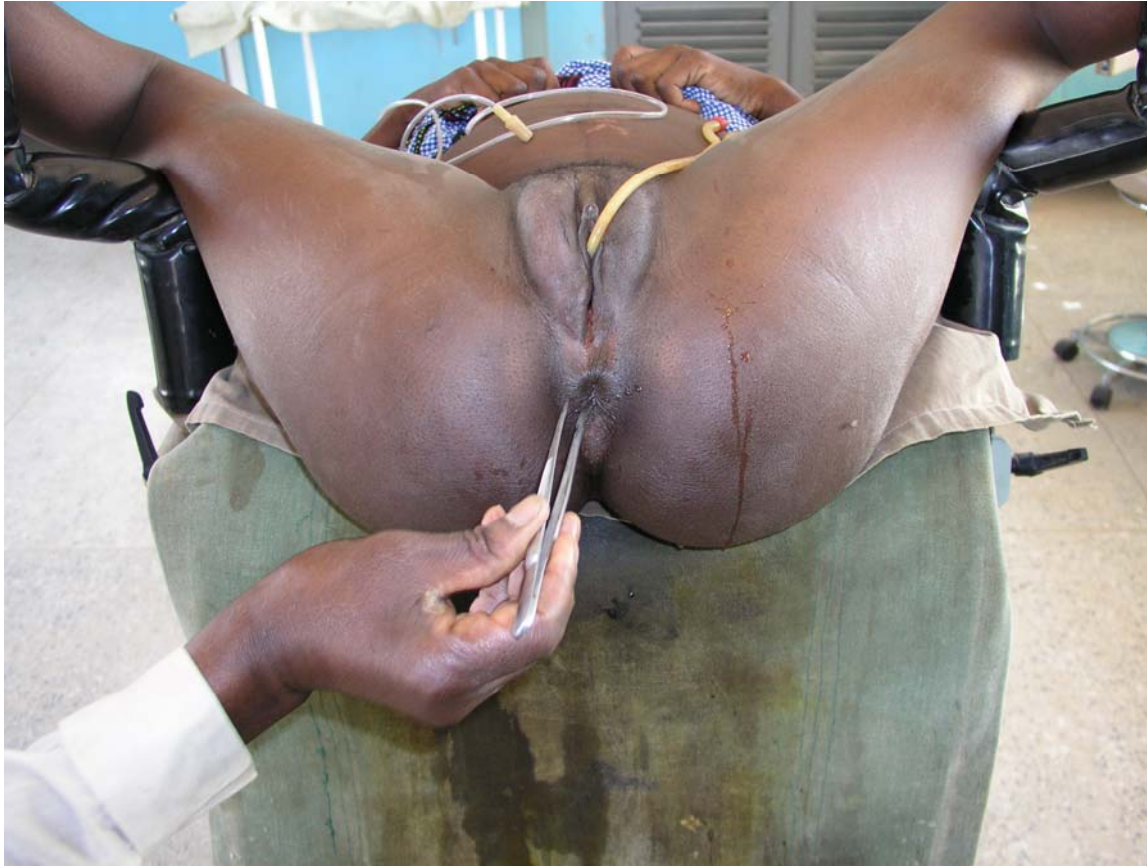atonic bladder

drop foot



atonic bladder

anal reflex

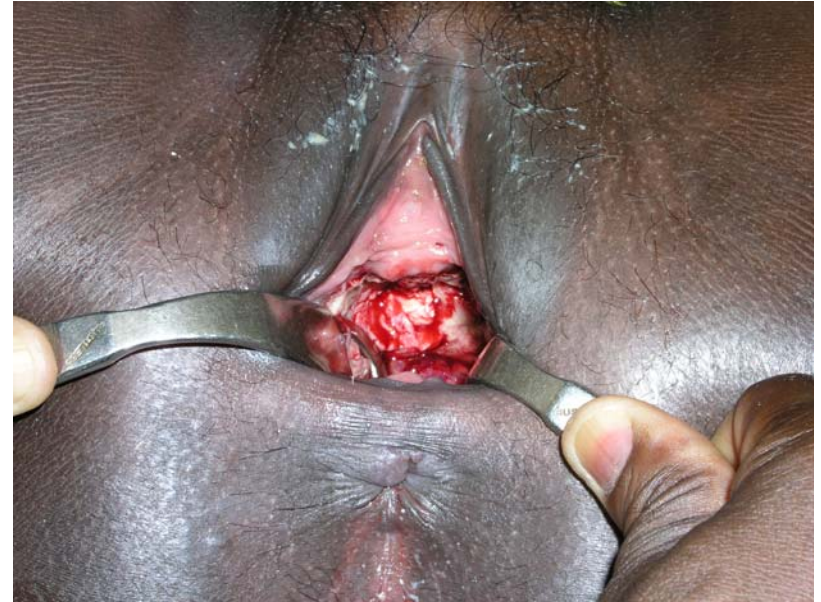
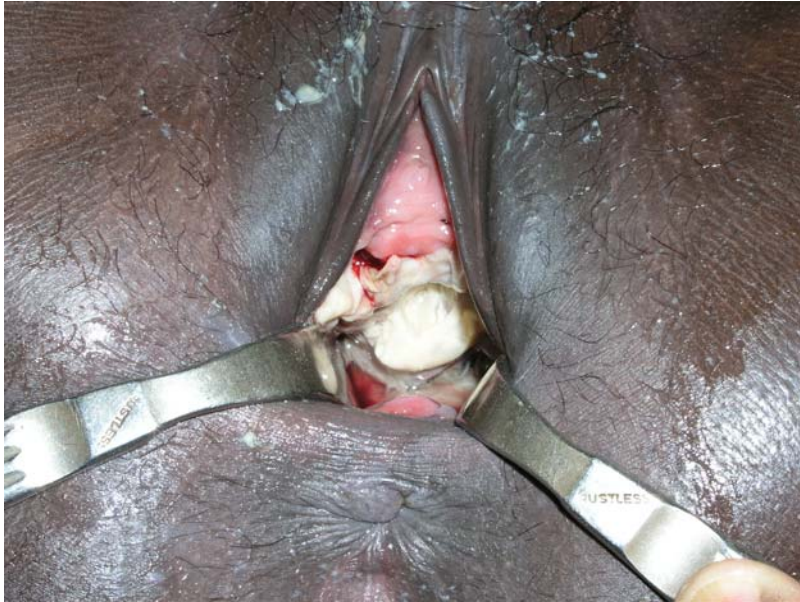
atonic bladder

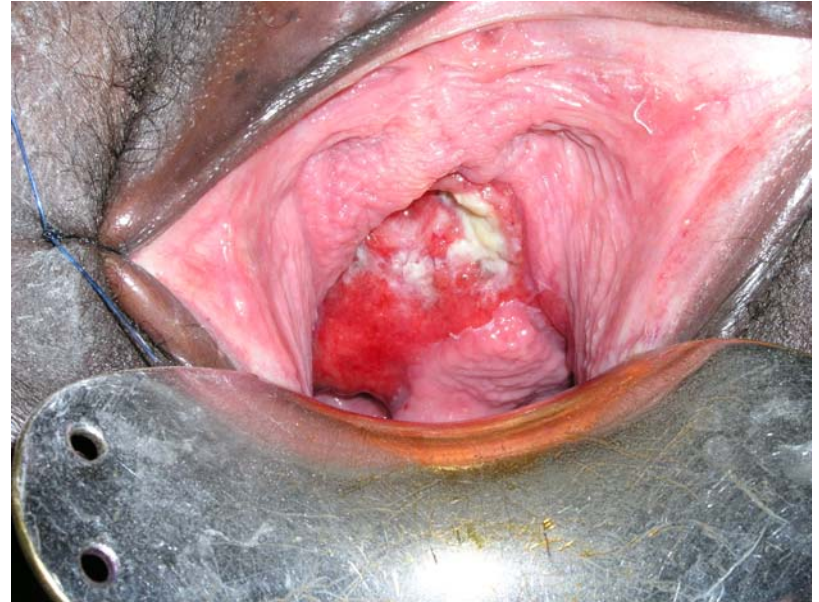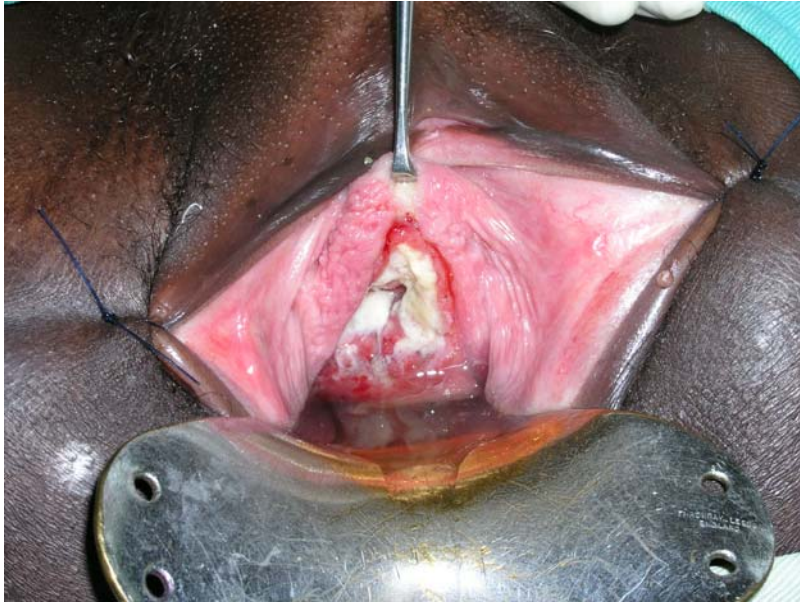treatment

- detrusor muscle cannot contract due to mechanical overstretching with/without sacral plexus trauma
- FOLEY catheter Ch 18 for at least 6 weeks
- high oral fluid intake of 6-8 liters per day in order to prevent ascending infection
- immediate bladder drill upon catheter removal

excision of slough

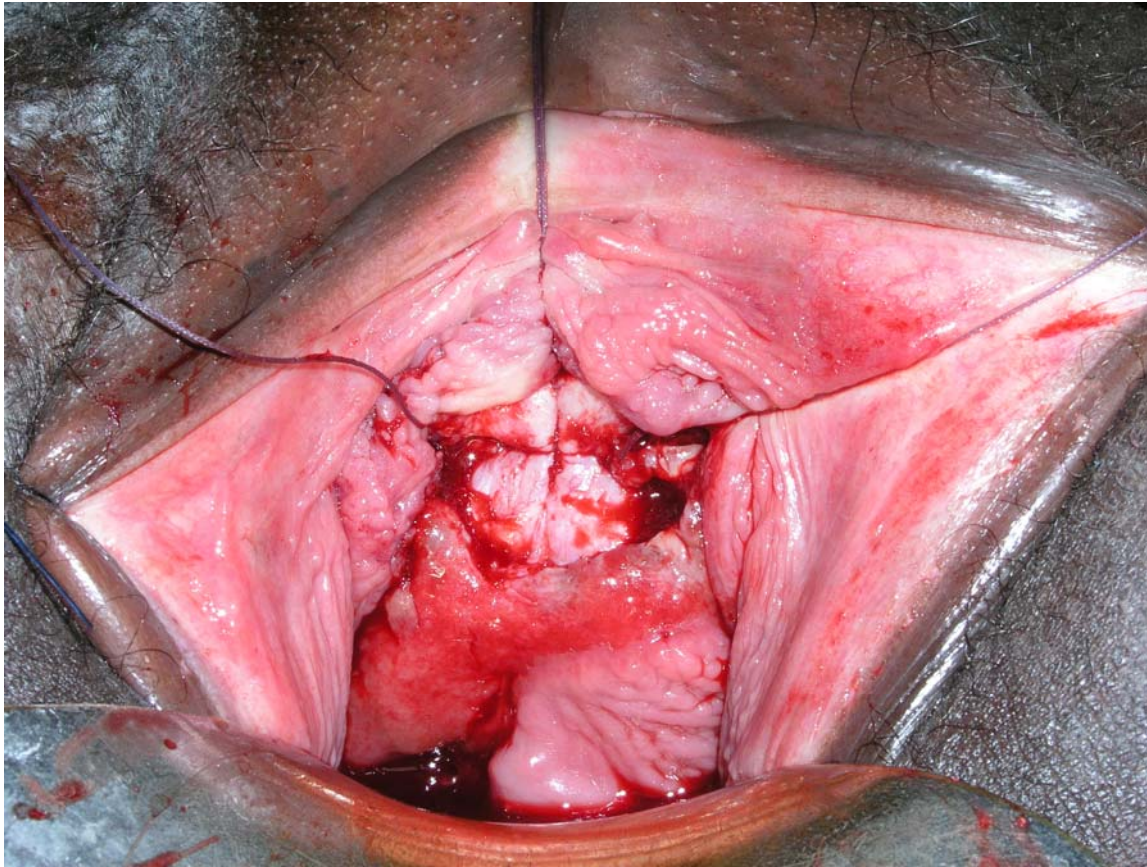


early closure



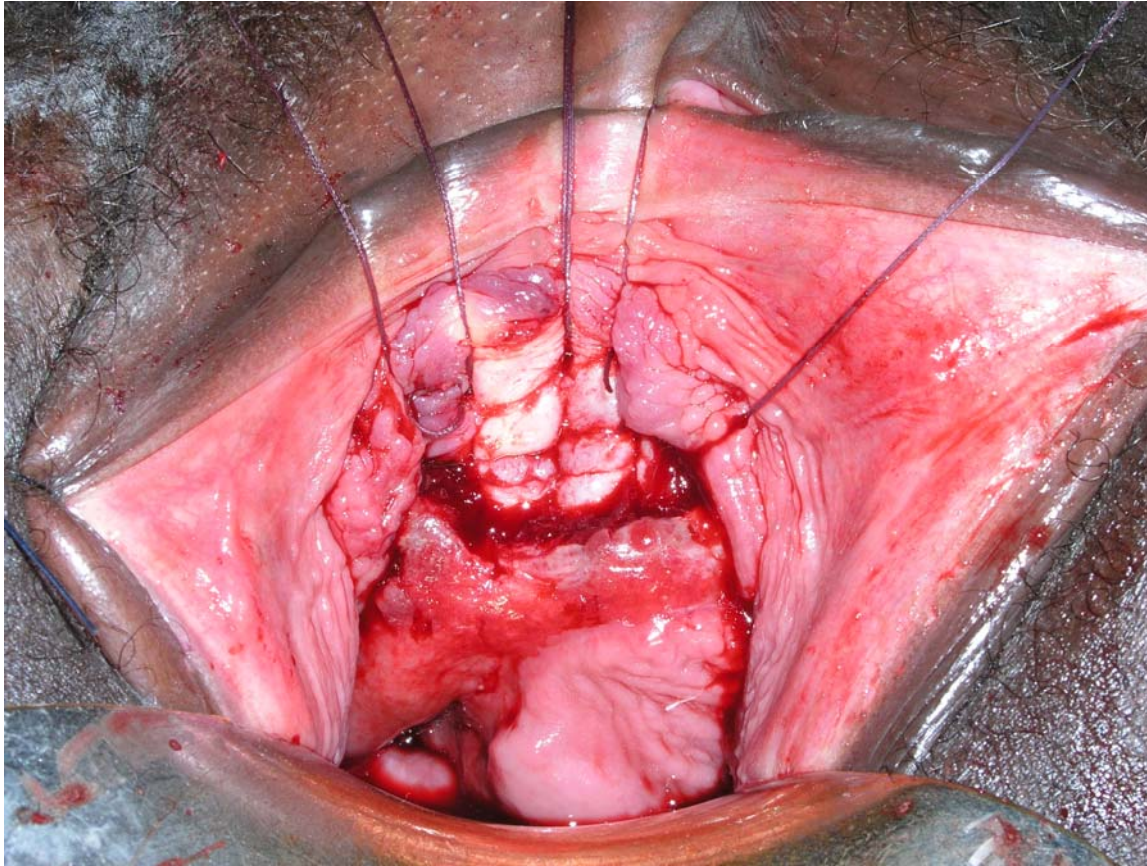
early closure

transverse bladder/urethra closure one layer inverting



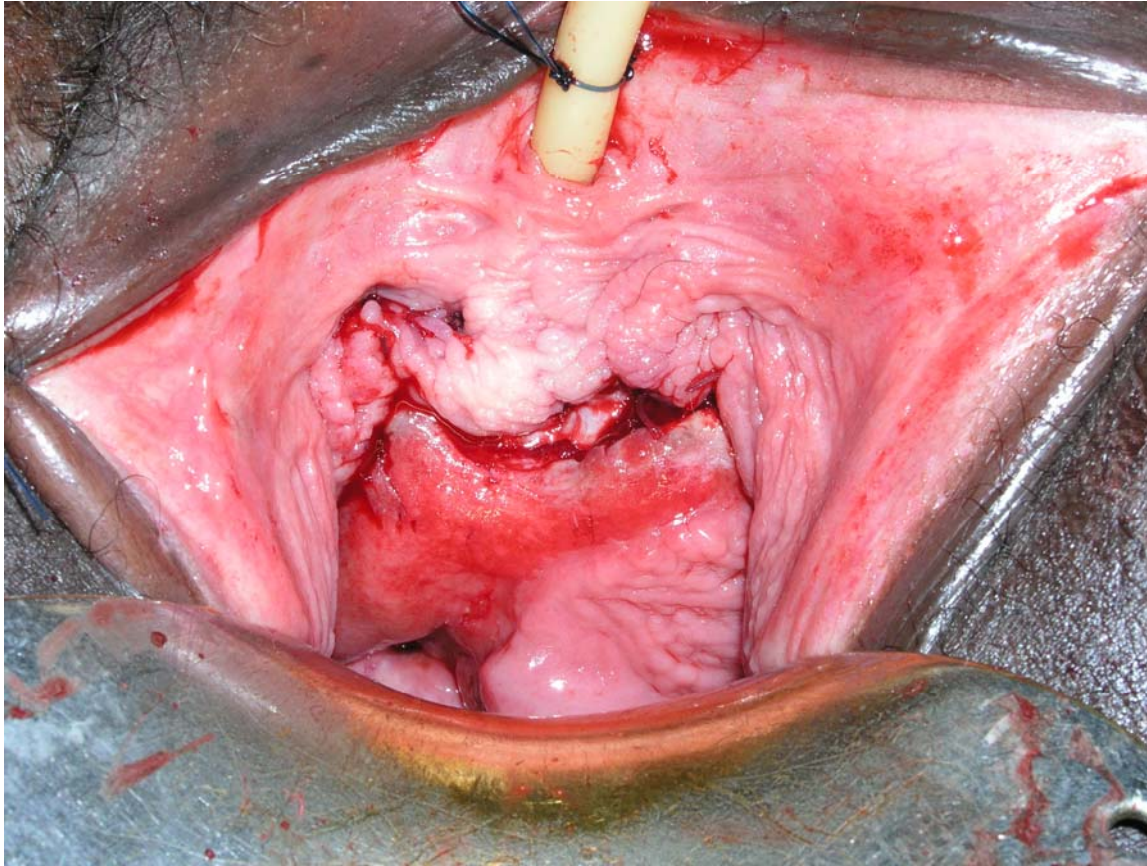
early closure

transverse bladder/urethra closure one layer inverting



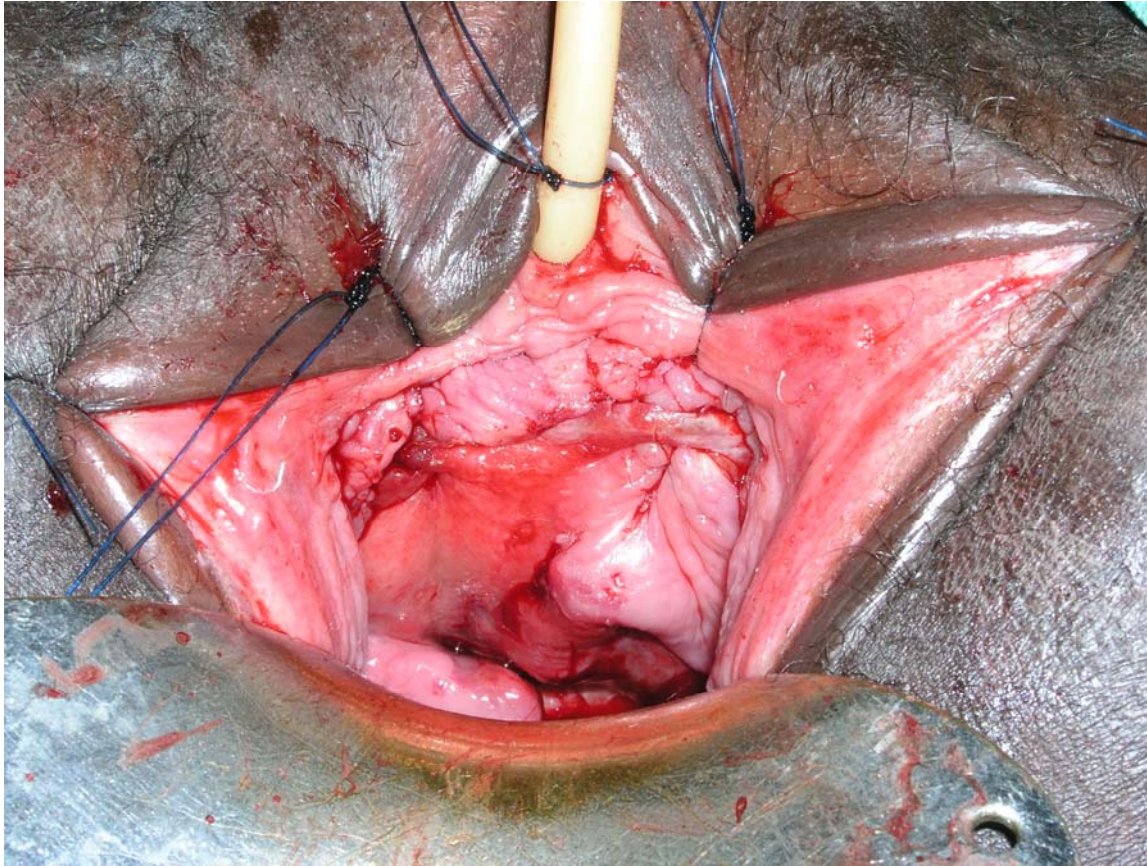
early closure

anterior vagina wall already adapted



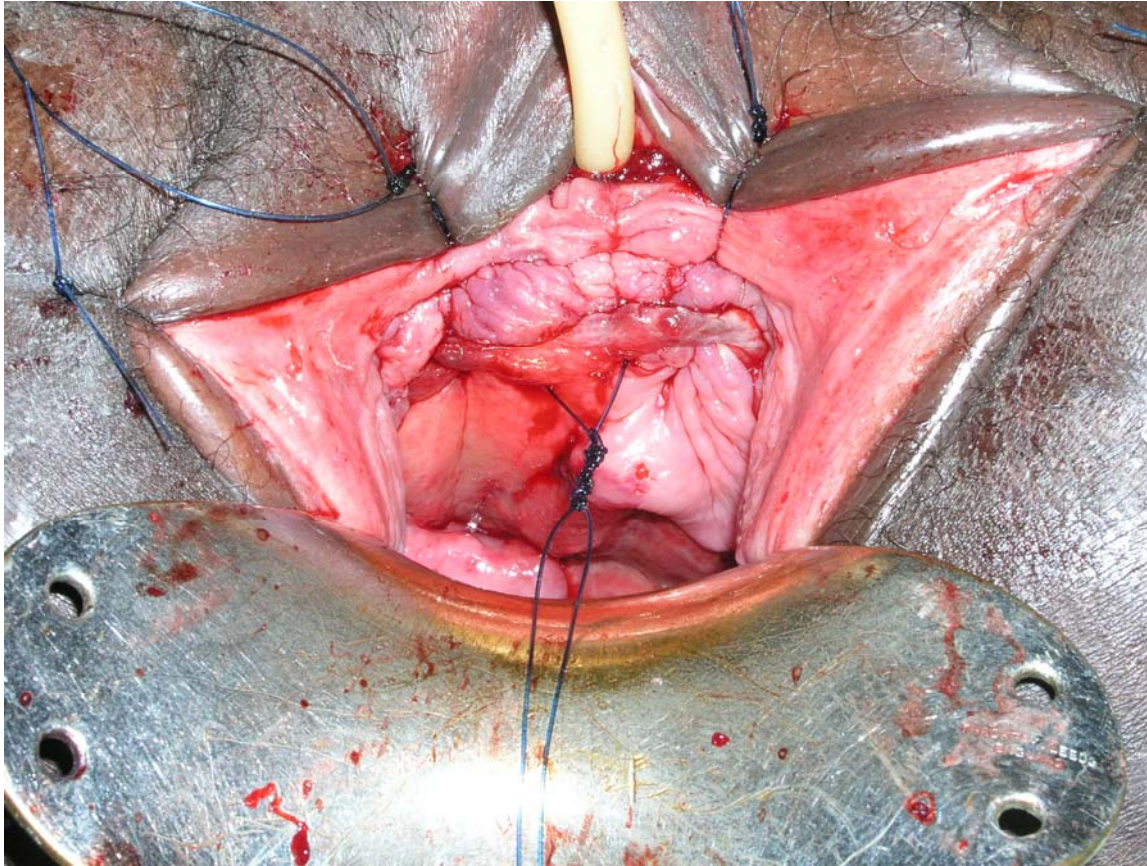
early closure

adaptation anterior vagina wall by everting nylon sutures 2x

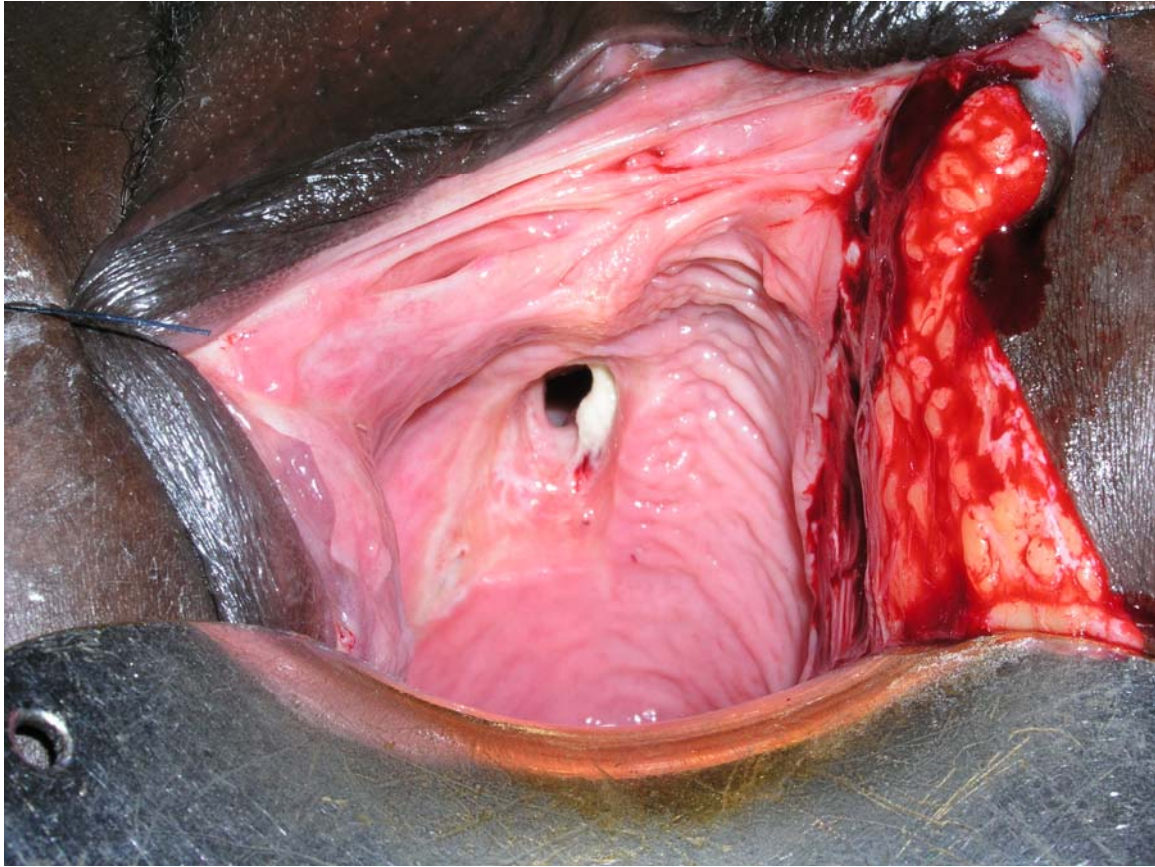


early closure

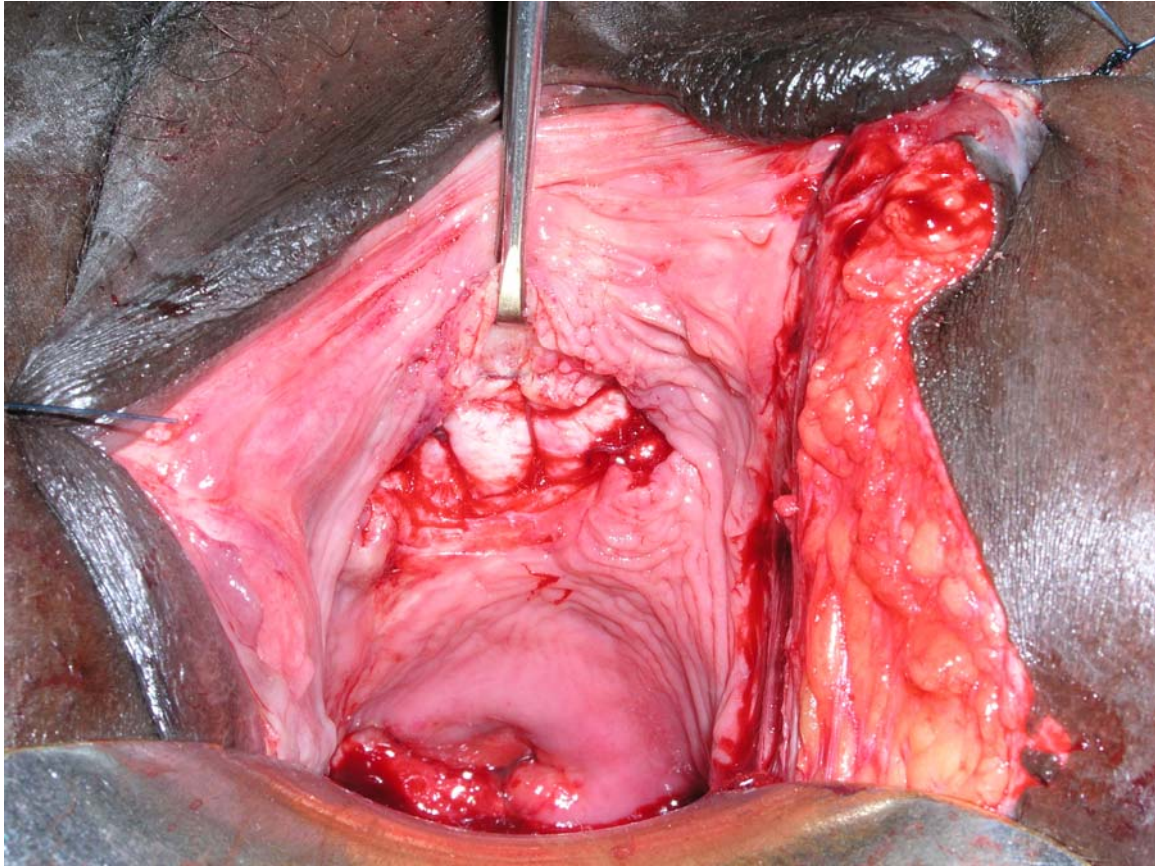
triple fixation of FOLEY catheter Ch 18



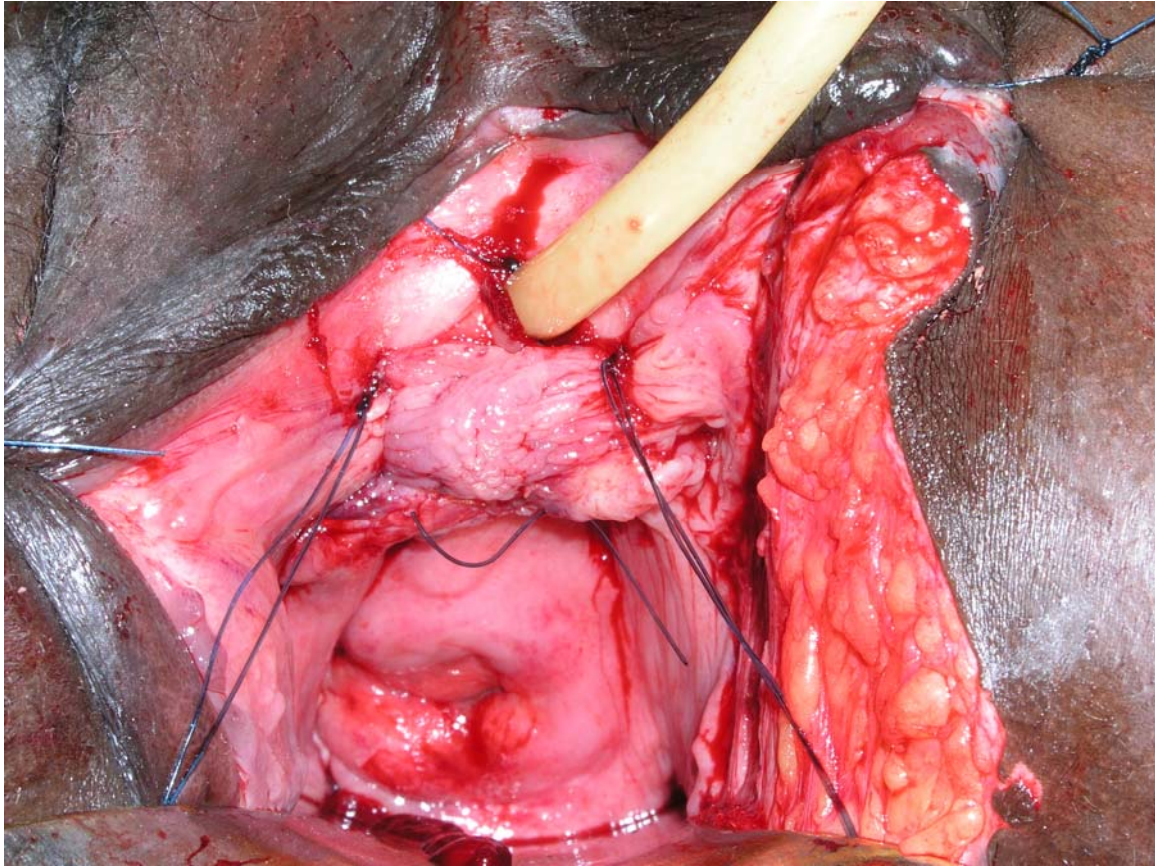
early closure



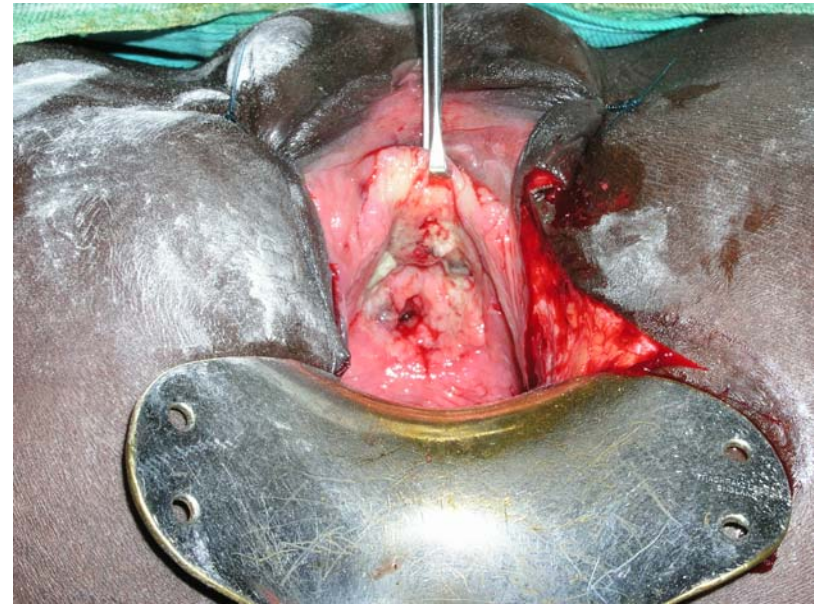
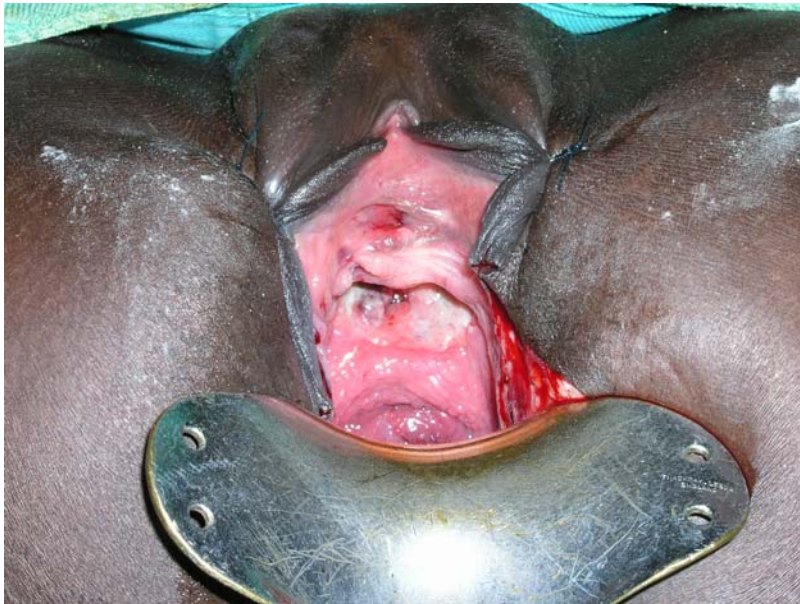early closure



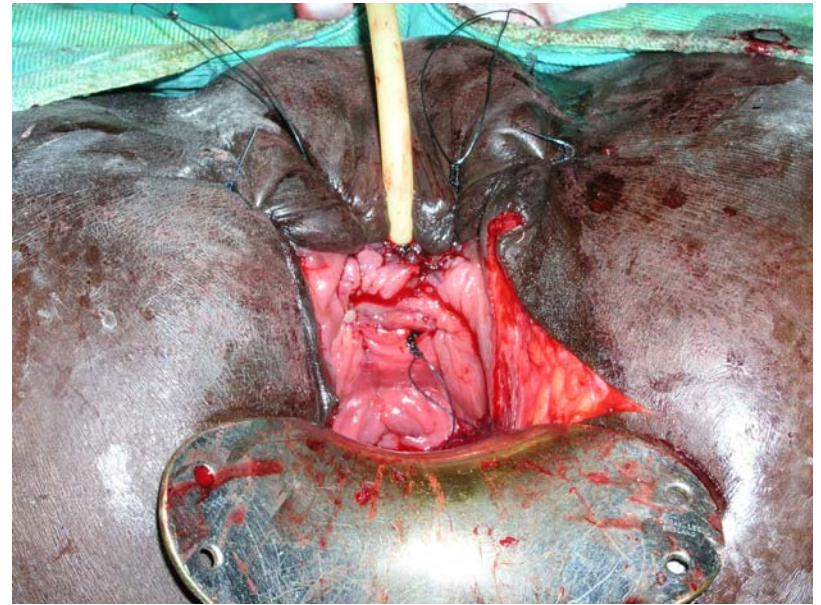
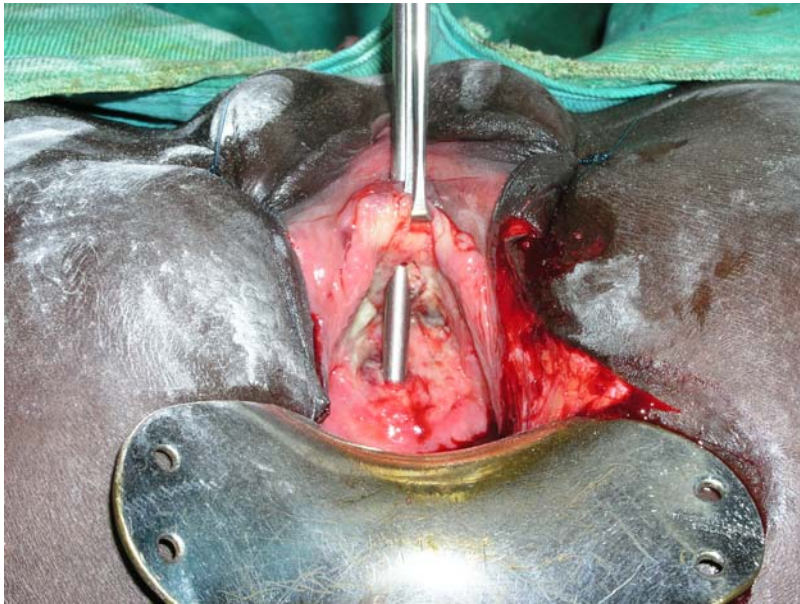
early closure



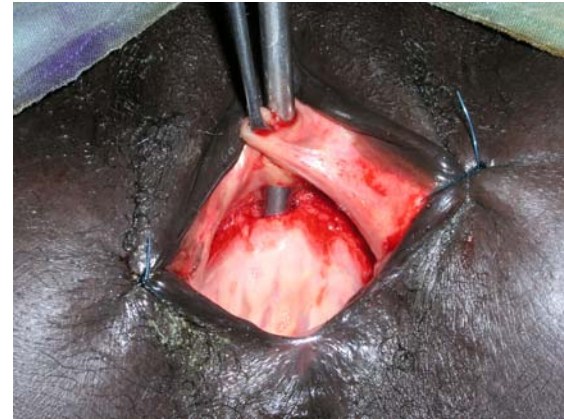
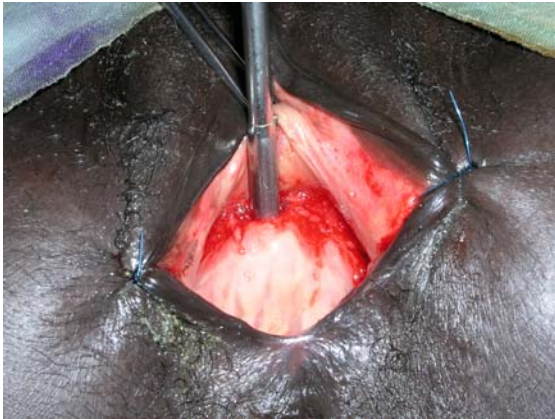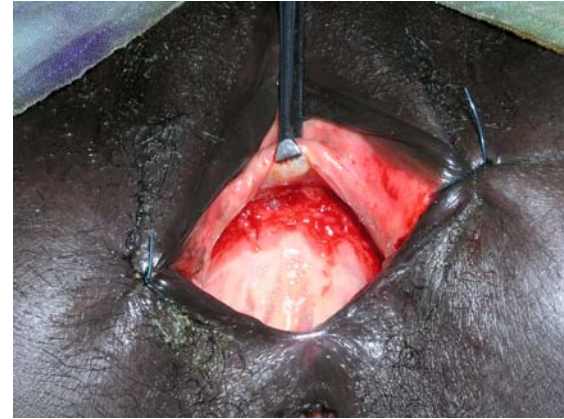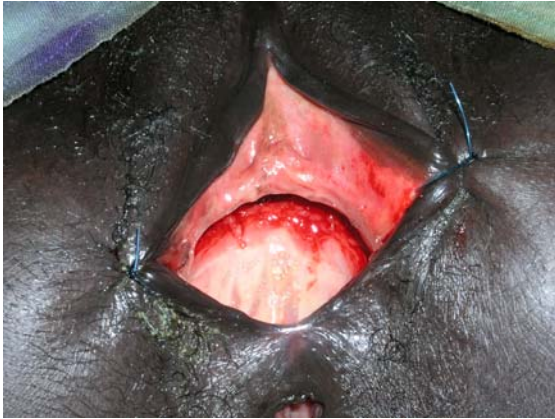early closure



early closure

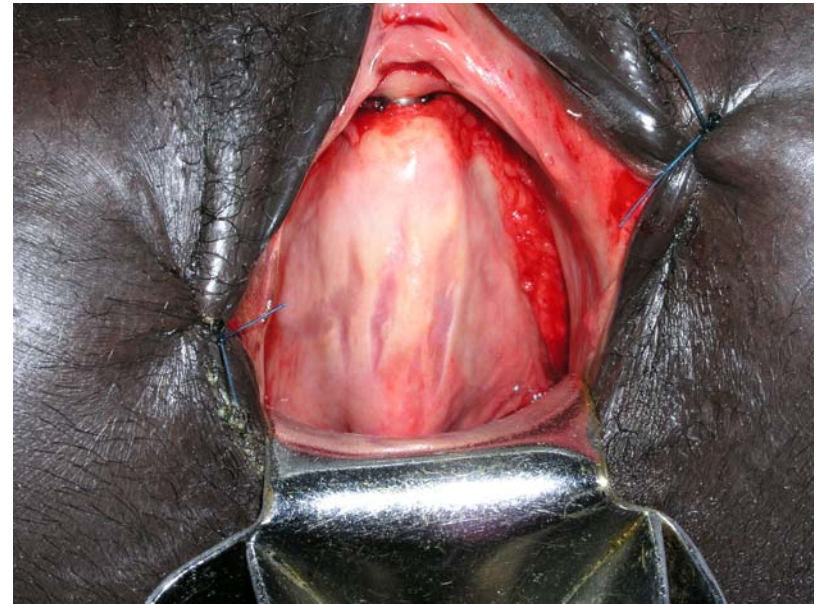
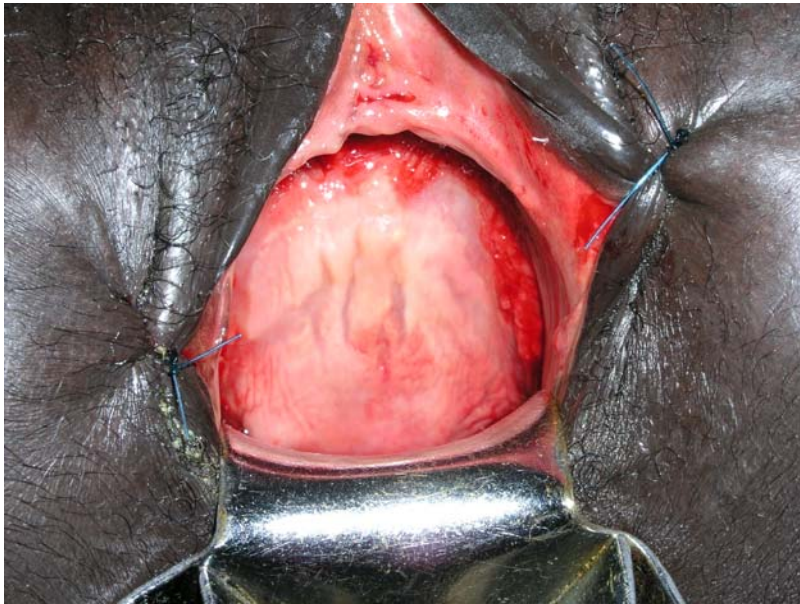


early closure

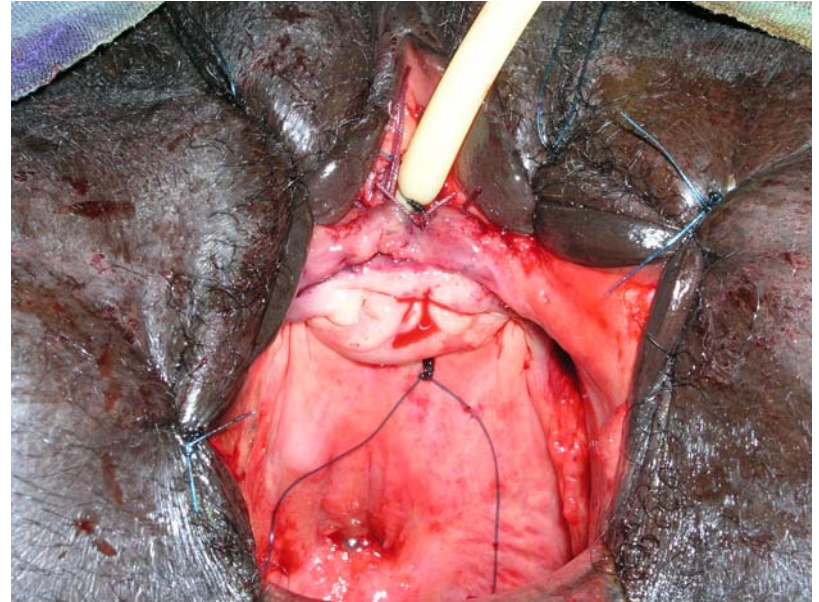
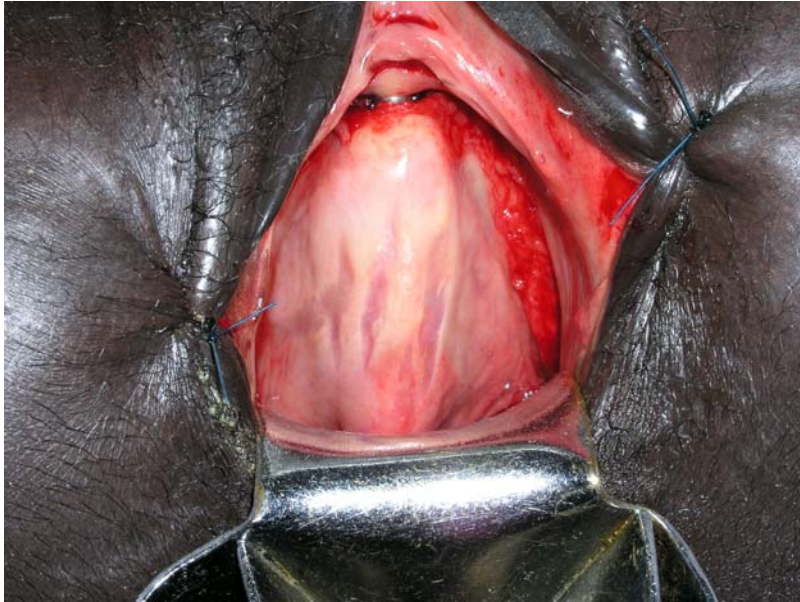

early closure

vagina striae

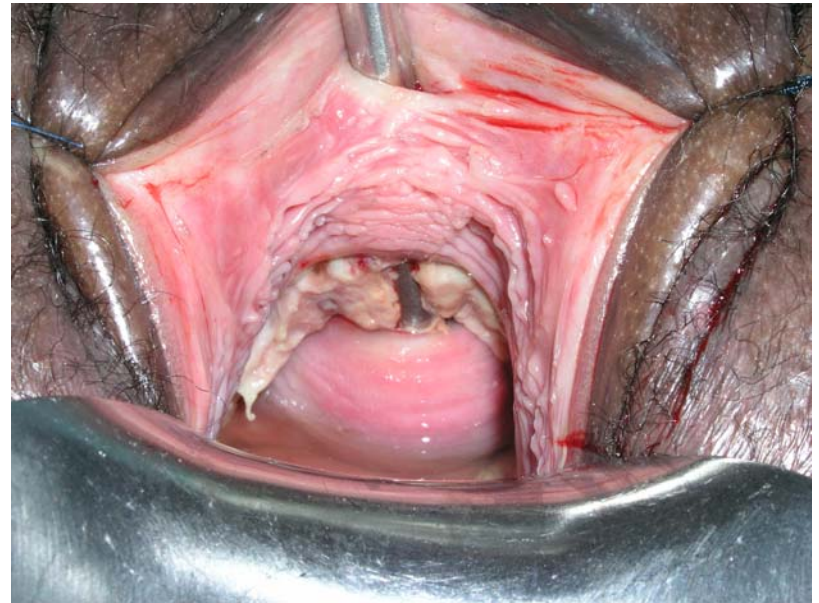
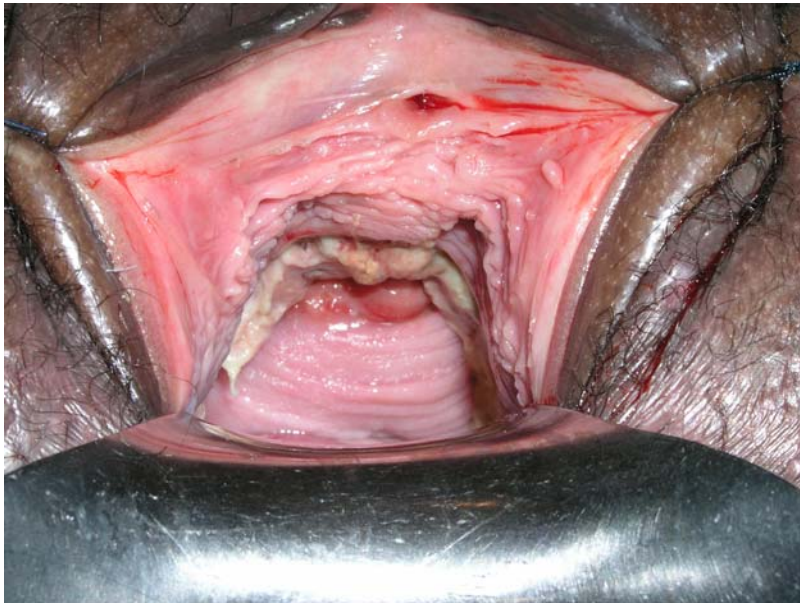

early closure



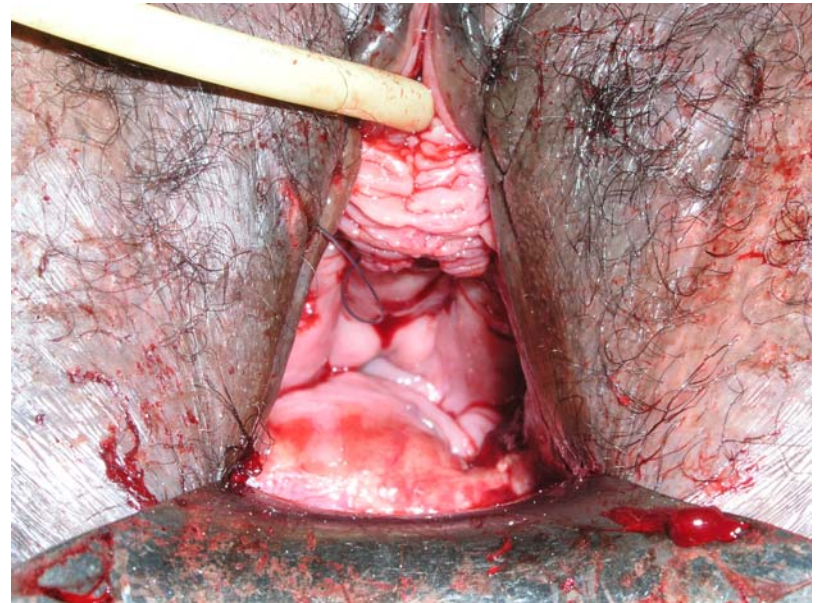
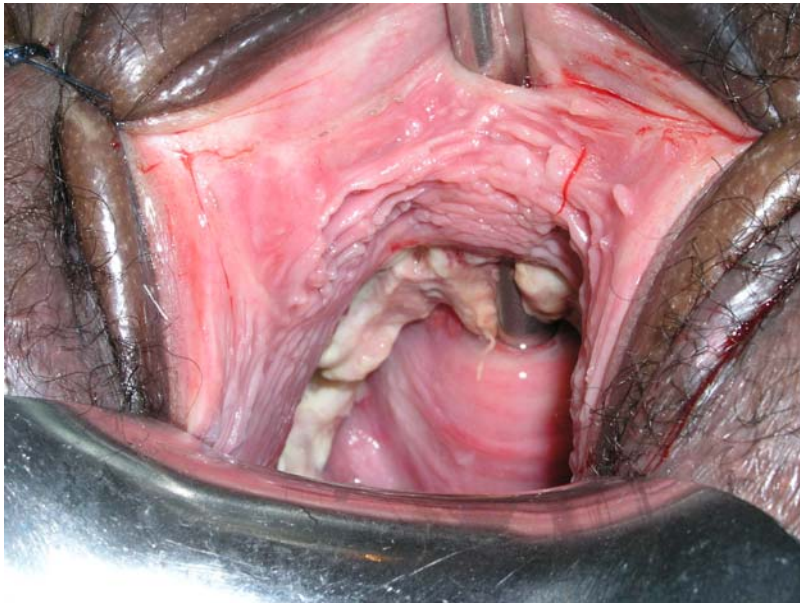early closure

slough_necrosis



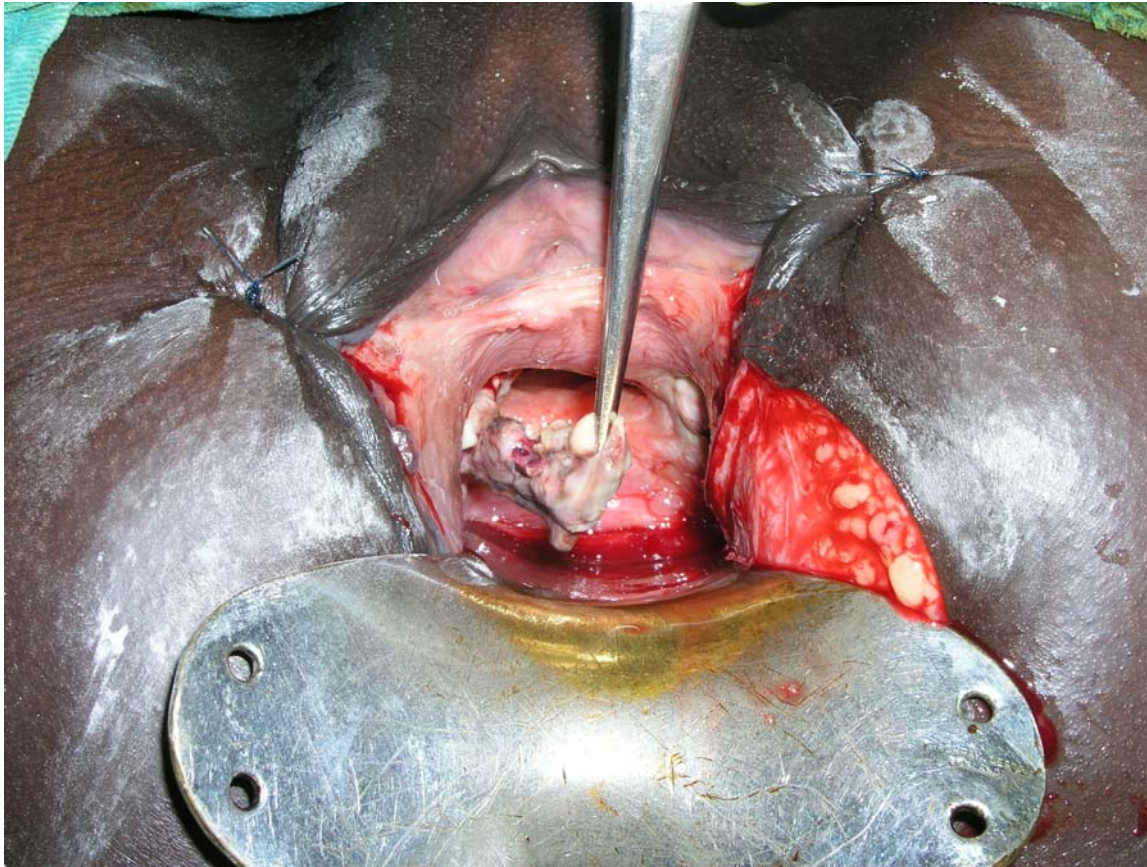
early closure

slough_necrosis



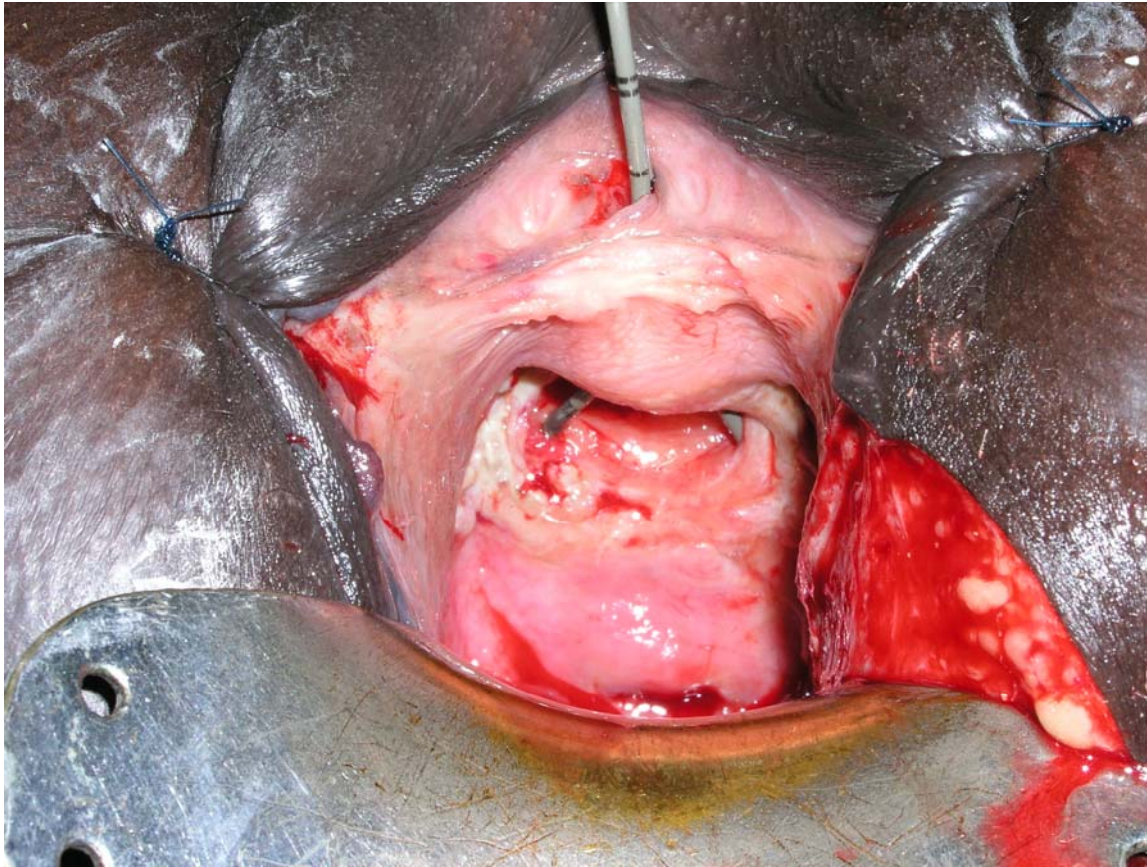
early closure

slough



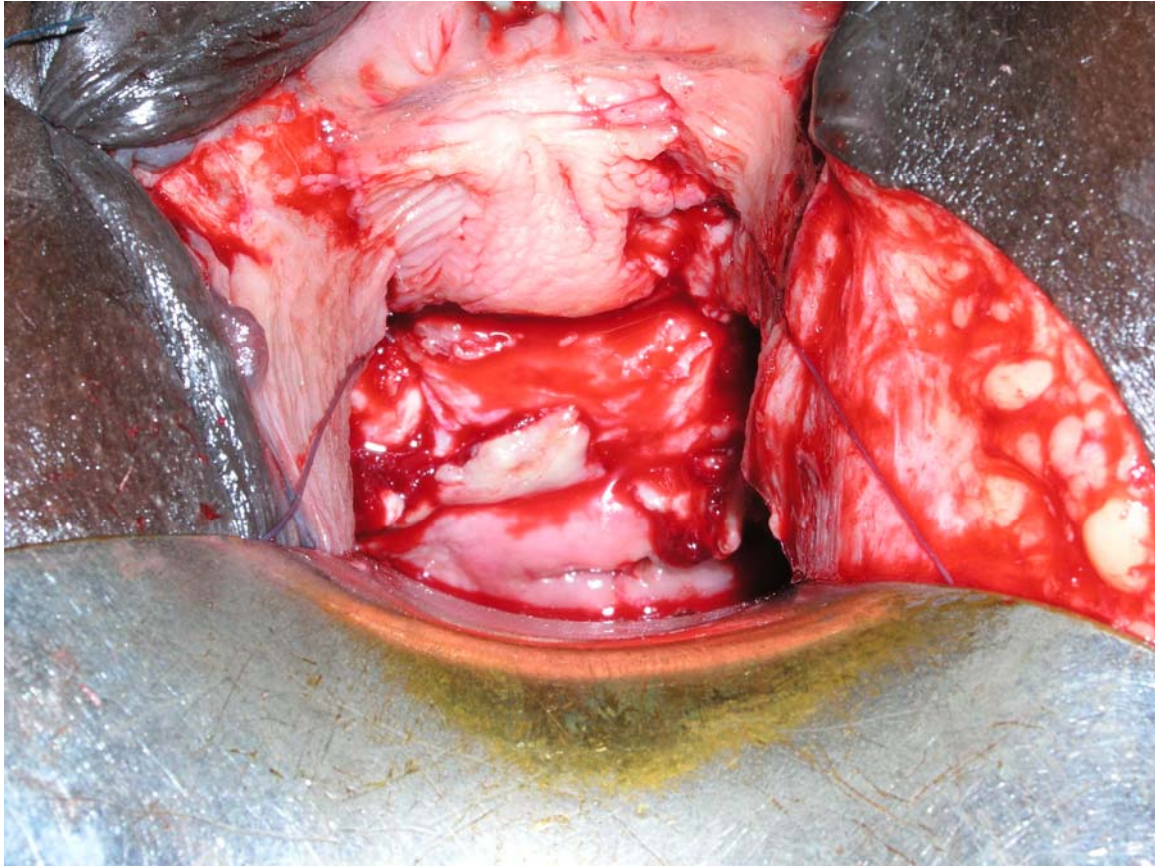
early closure

slough



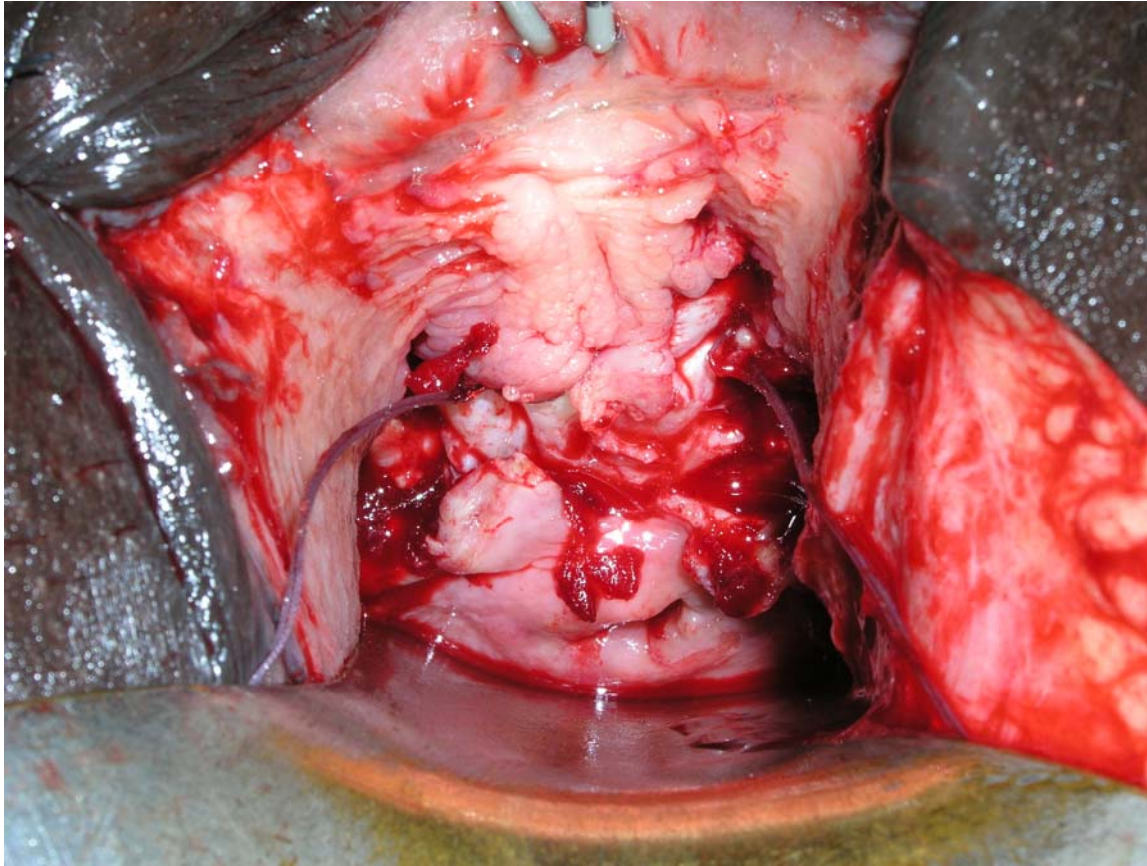
early closure

slough



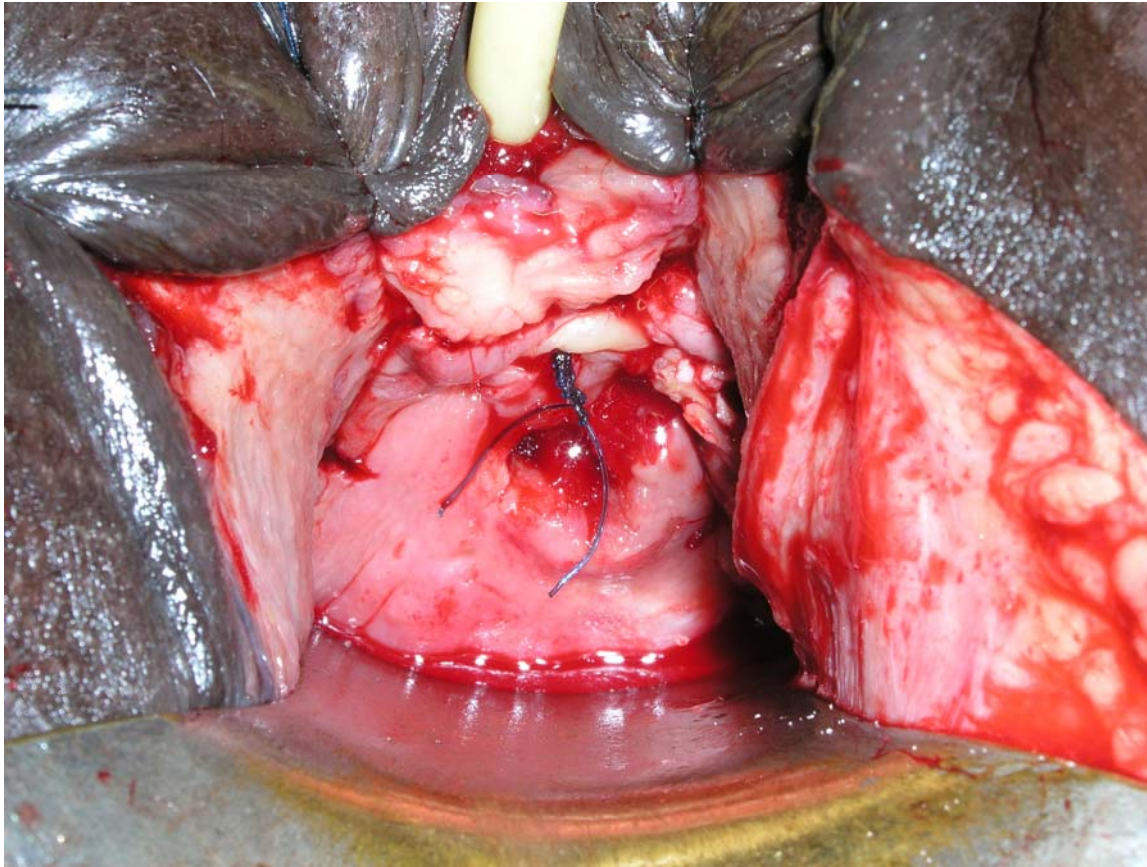
early closure

slough

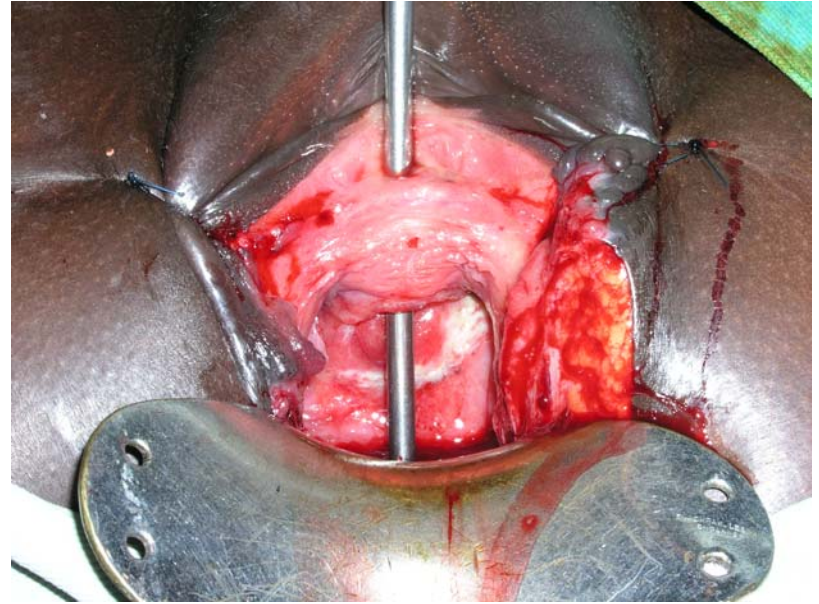
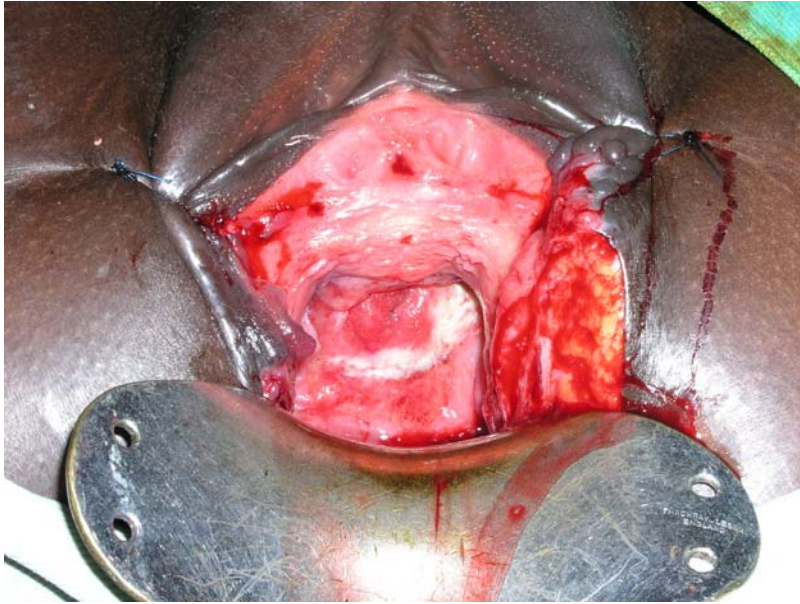


early closure

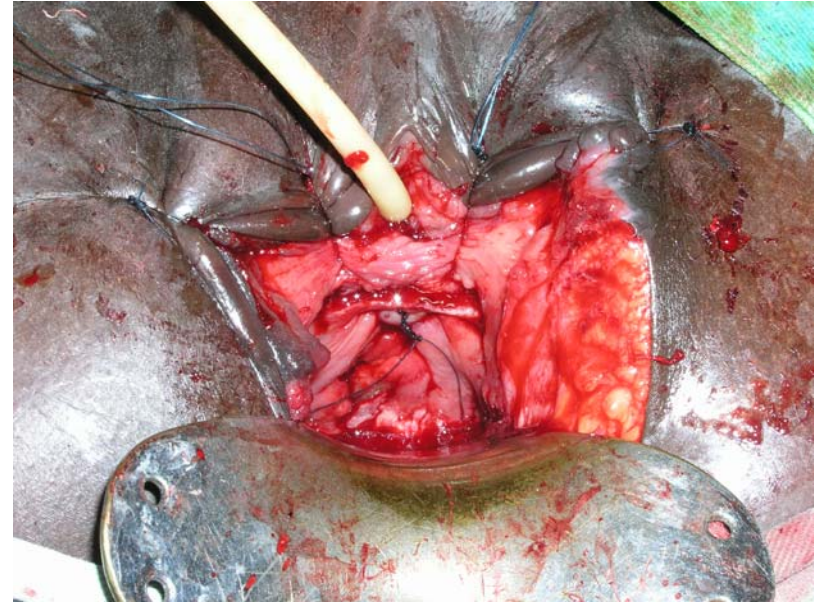
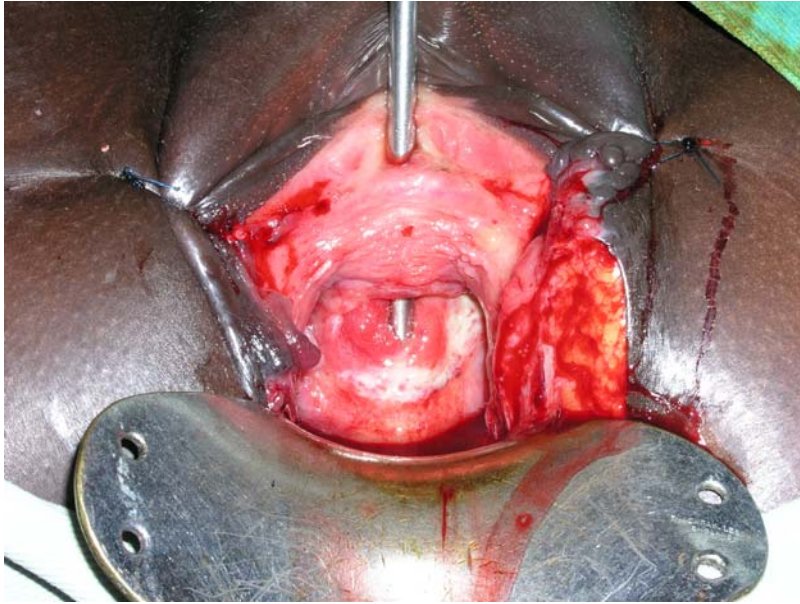
slough



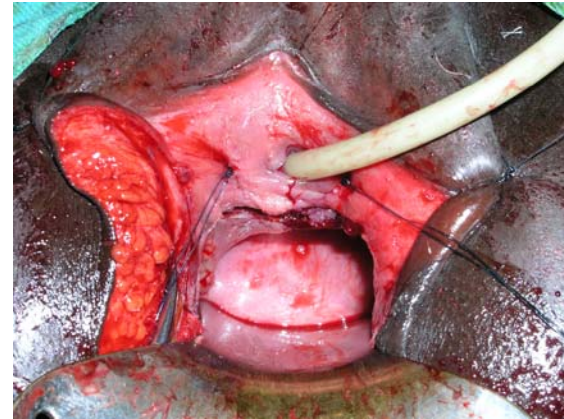
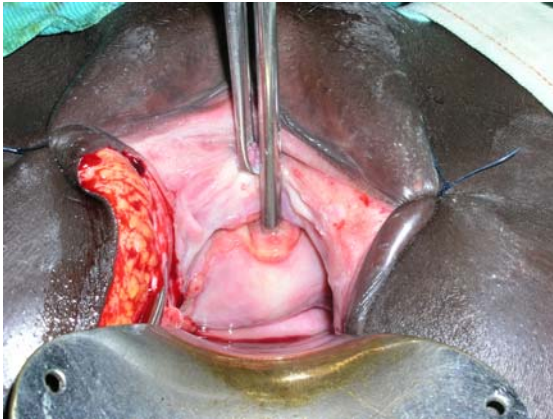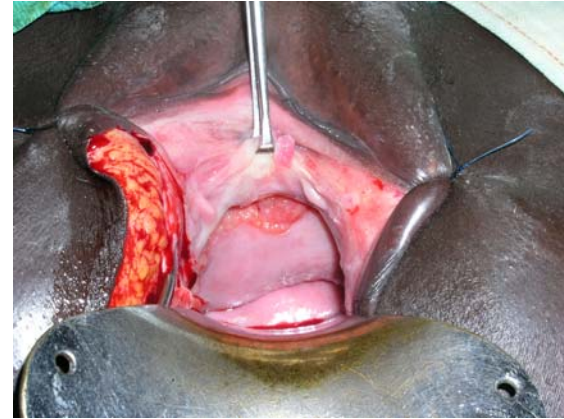
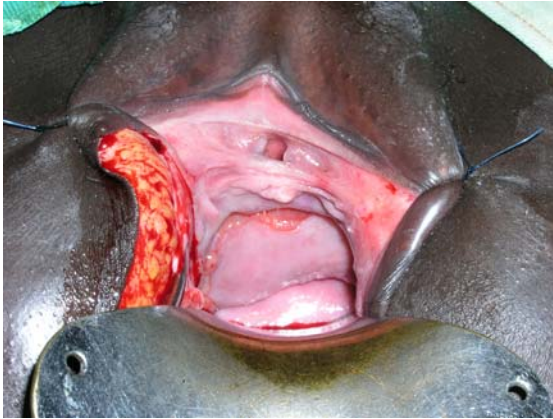early closure



early closure



early closure



early closure

