

the obstetric fistula

kees waaldijk

babbar ruga fistula hospital

the obstetric fistula

- **vesicovaginal fistula** **VVF**
continuous leaking of urine thru vagina
- **rectovaginal fistula** **RVF**
intermittent passing of stools_flatus thru vagina

mechanism

- the head of the baby is too big, malrotates or presents abnormally and gets stuck inside the birth canal: **obstructed labor**
- the soft tissue of the vagina are compressed between the hard fetal skull and the bony maternal pelvis
- if not relieved in time **pressure necrosis** develops
- the baby dies and its head shrinks
- now the baby may pass thru the birth canal

prolonged obstructed labor

- this condition may last for up to 7 and more days
- many women die in the process though it is not known how many
- if the mother survives it is for the prize of a dead baby and an obstetric fistula
- if the fistula is not closed she becomes an outcast

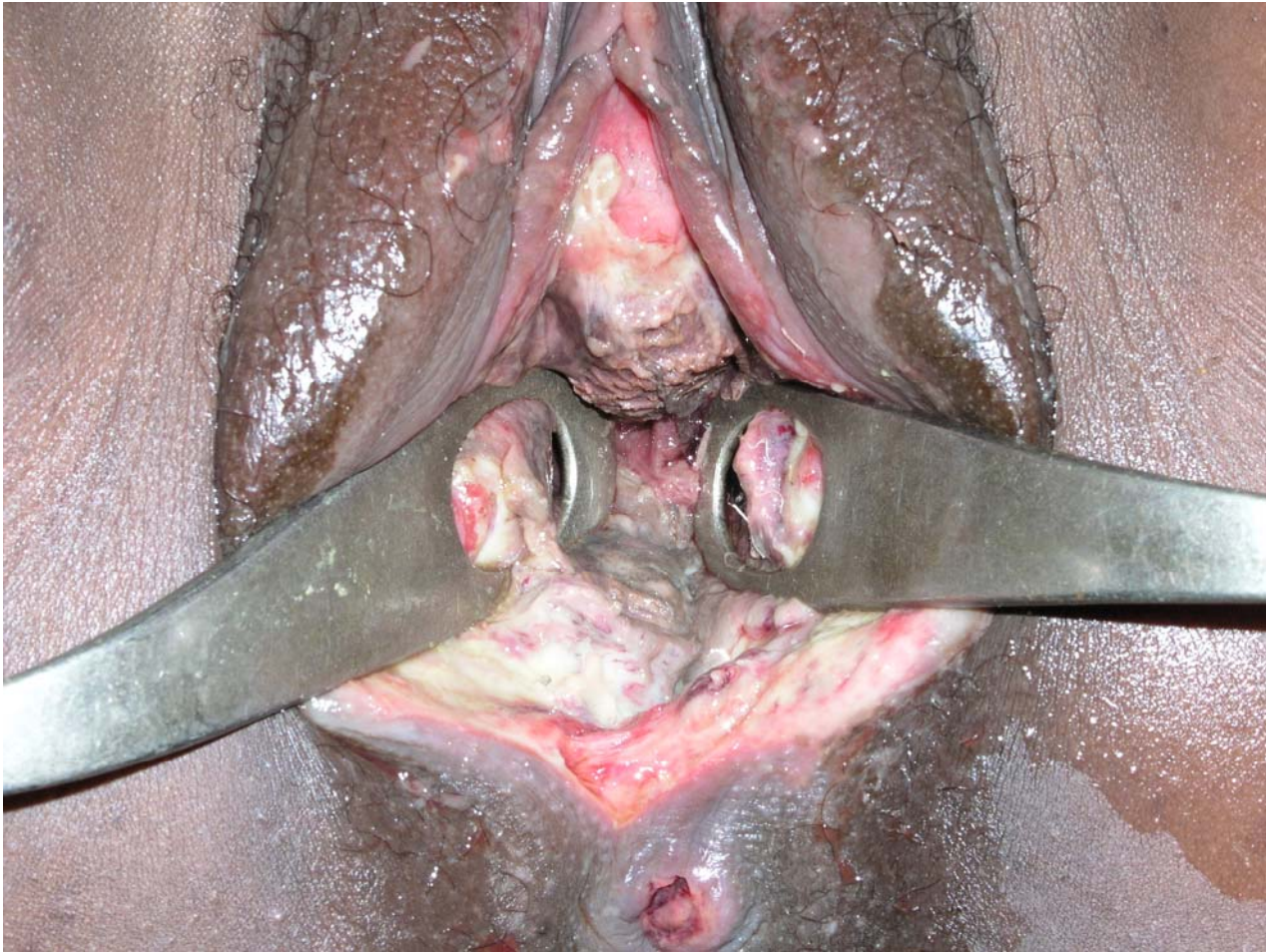
incidence and prevalence

- 2-5 per 1,000 deliveries where the mother survives
- 100,000-150,000 new patients a year
- 1,500,000-2,000,000 patients world wide waiting for surgery

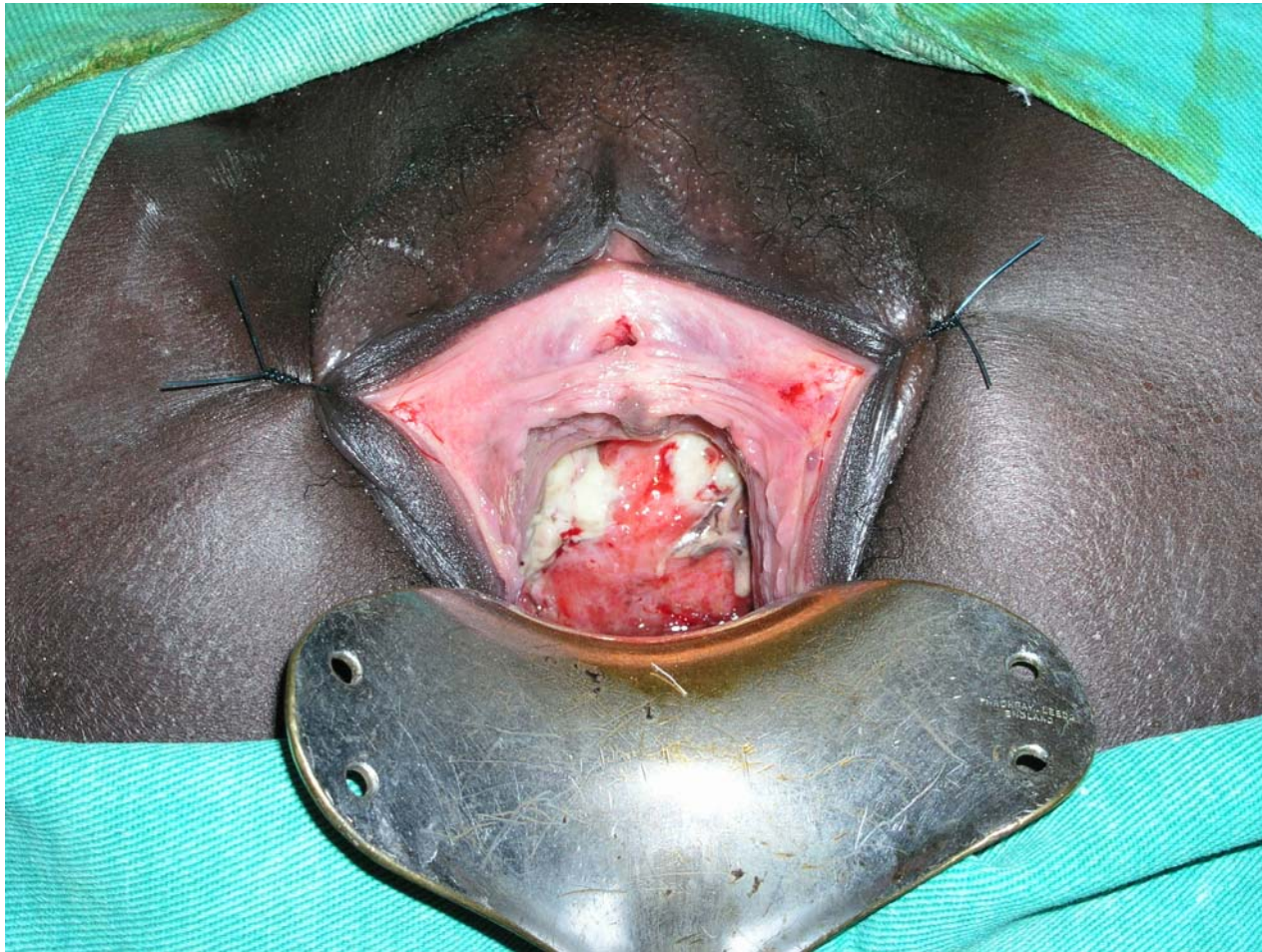
prevention

- **a** prevention of the obstetric fistula is a utopia since a network of 150,000 obstetric units are needed evenly distributed throughout the rural parts of inhabited Africa where day and night an emergency cesarean section can be performed upon arrival; what about the delay in diagnosis, decision taking and transport?
this will take at least another century
- **b** prevention of the woman from becoming an outcast is very well feasible by the **immediate management** by catheter and/or early closure

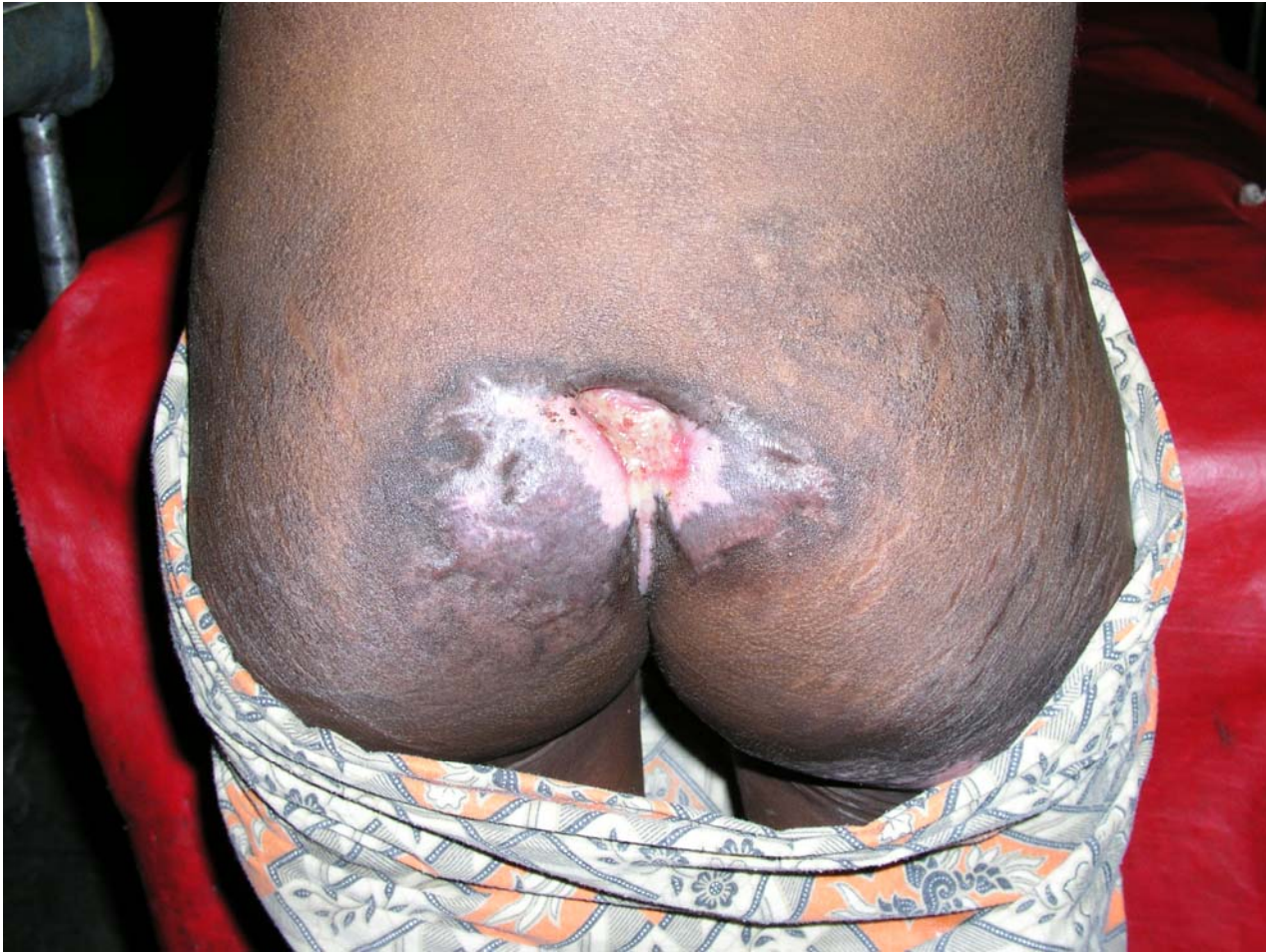necrosis



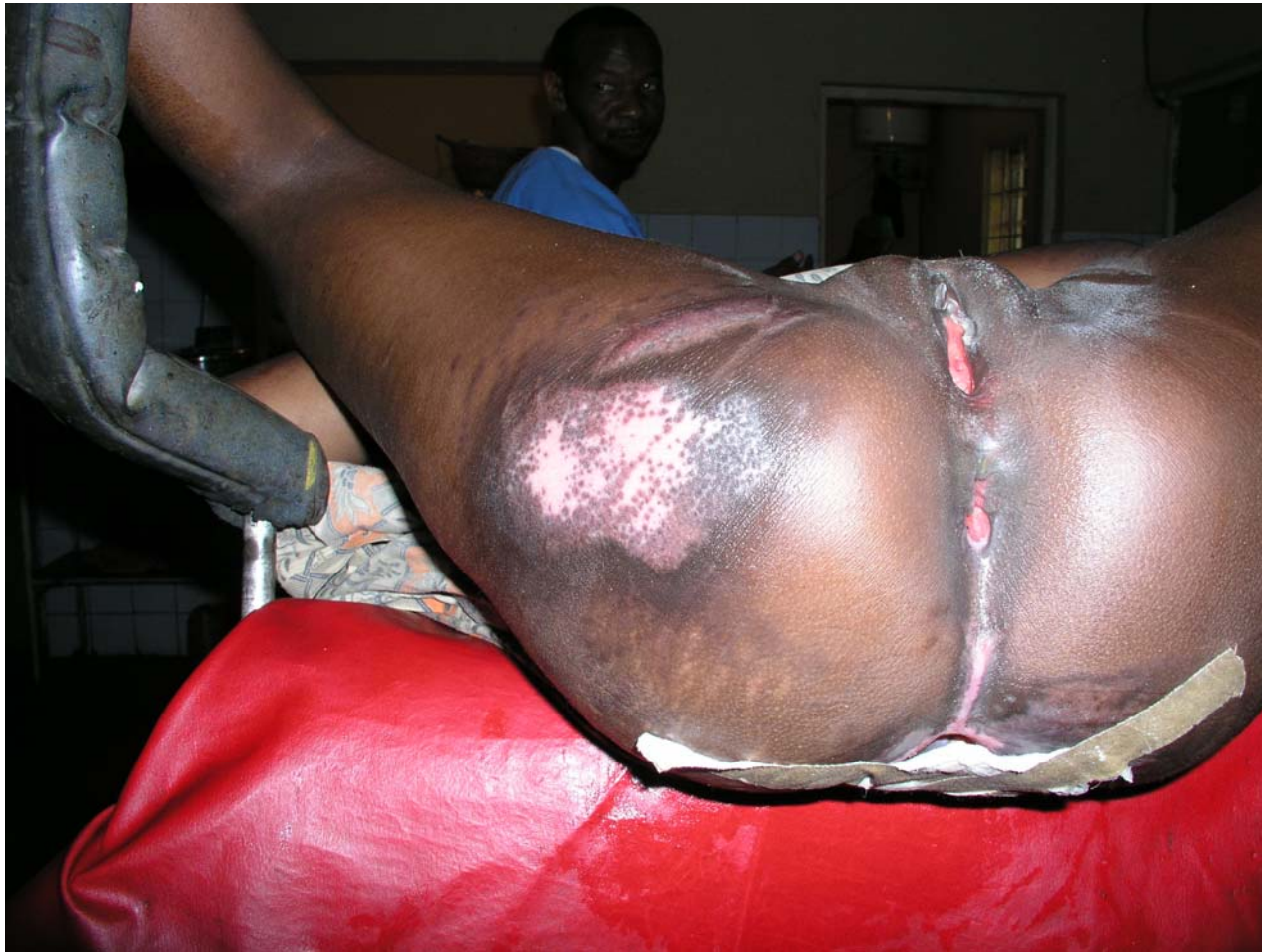necrosis_slough



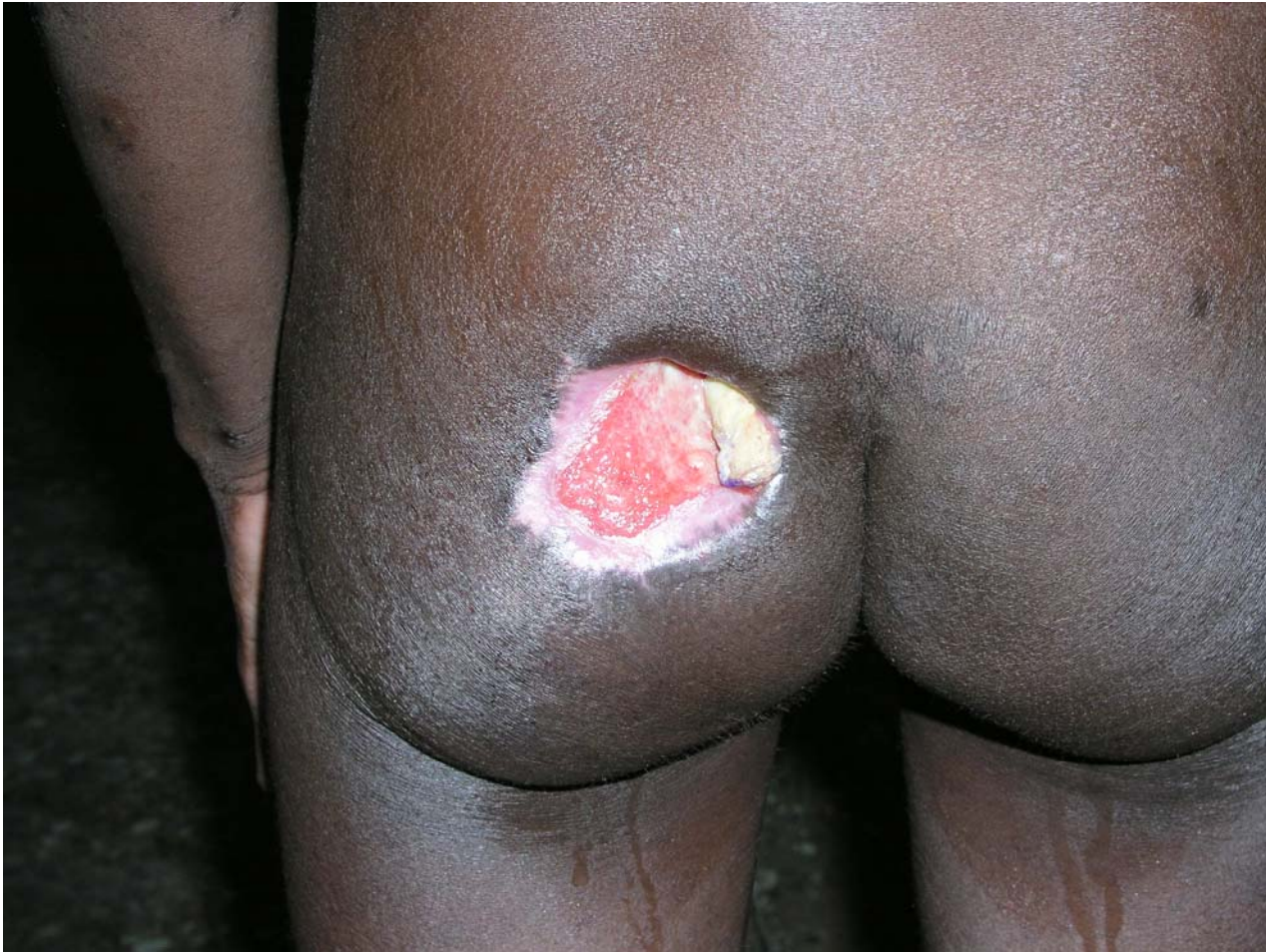ulcer over sacrum



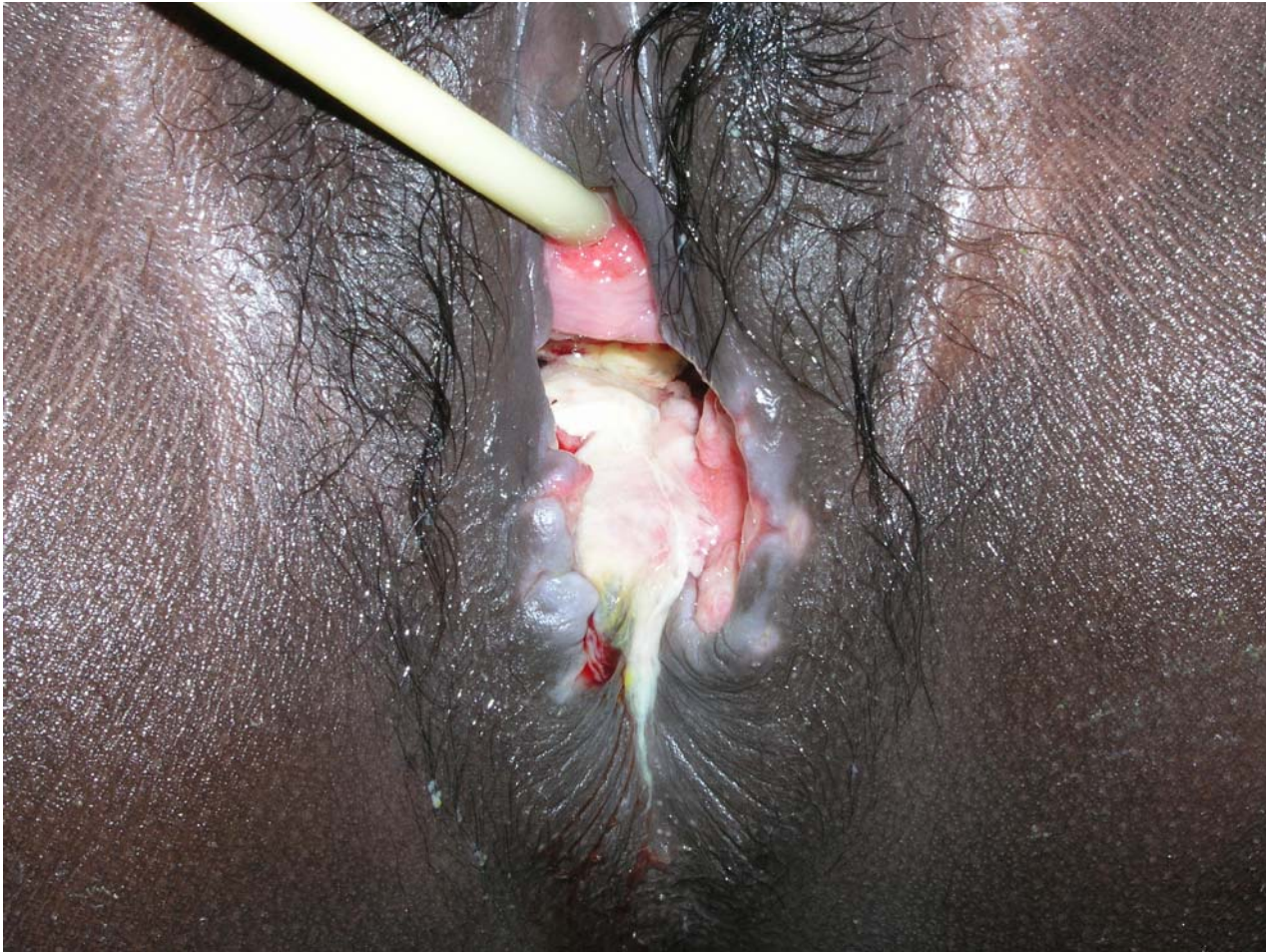ulcer due to hot baths



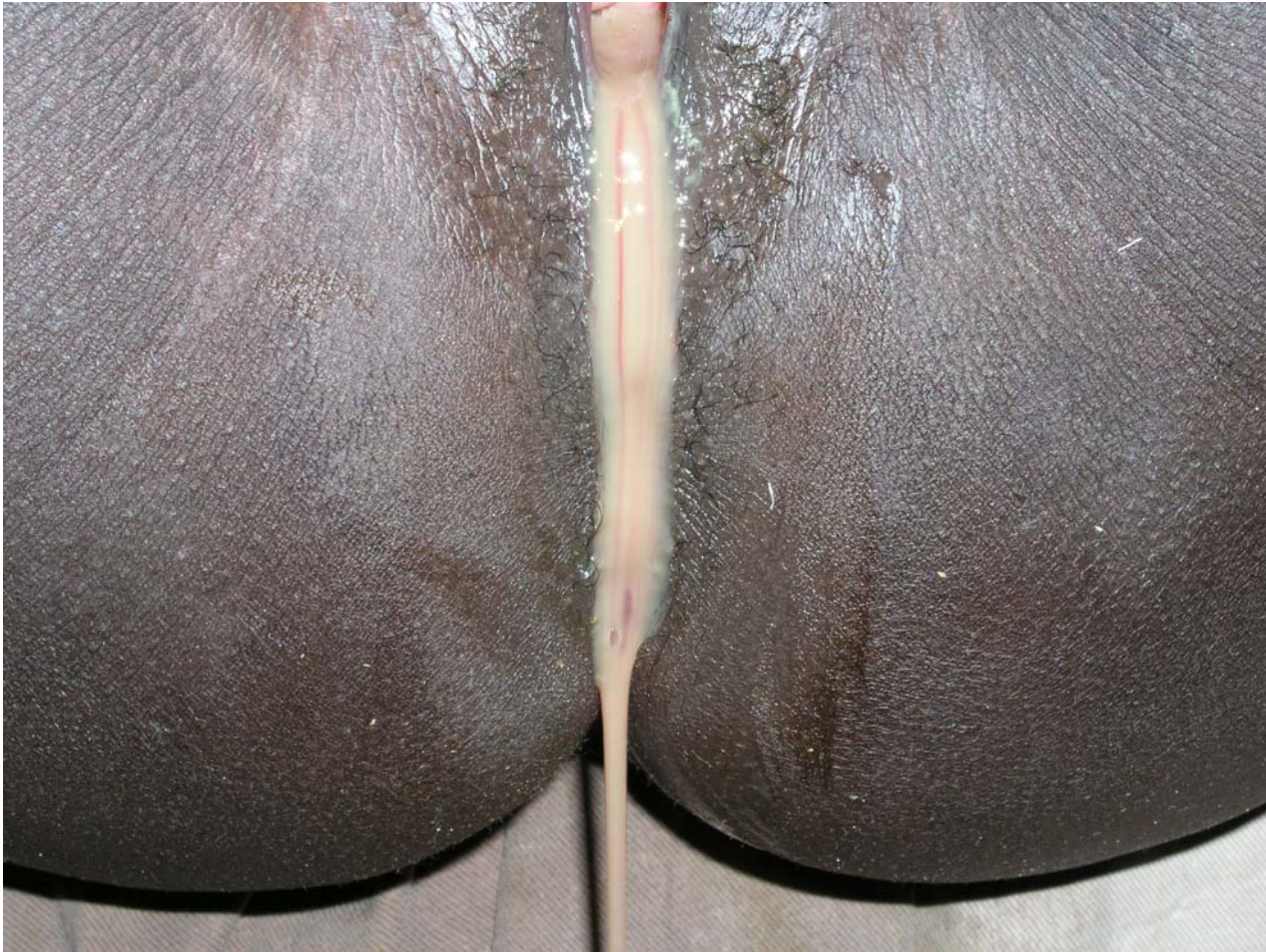
ulcer R buttock



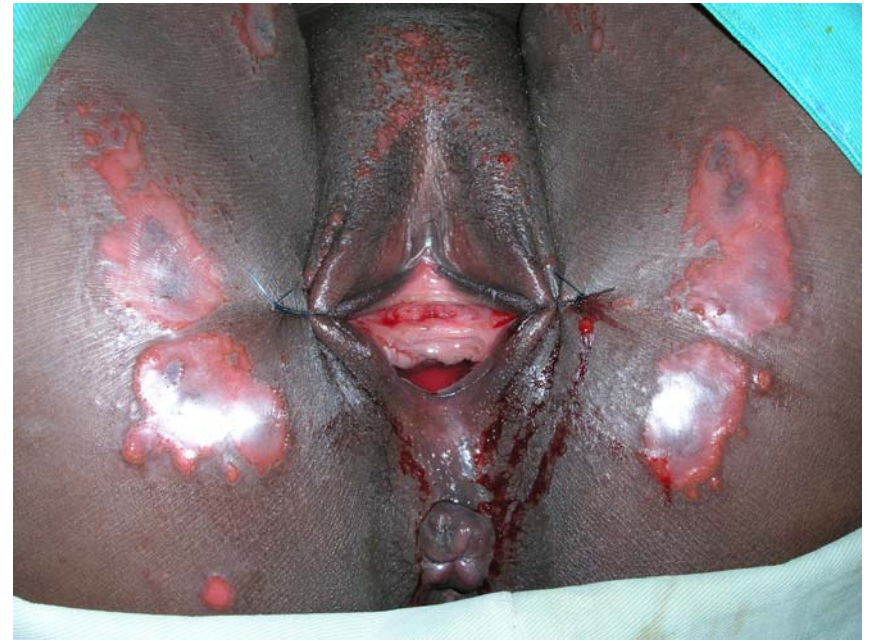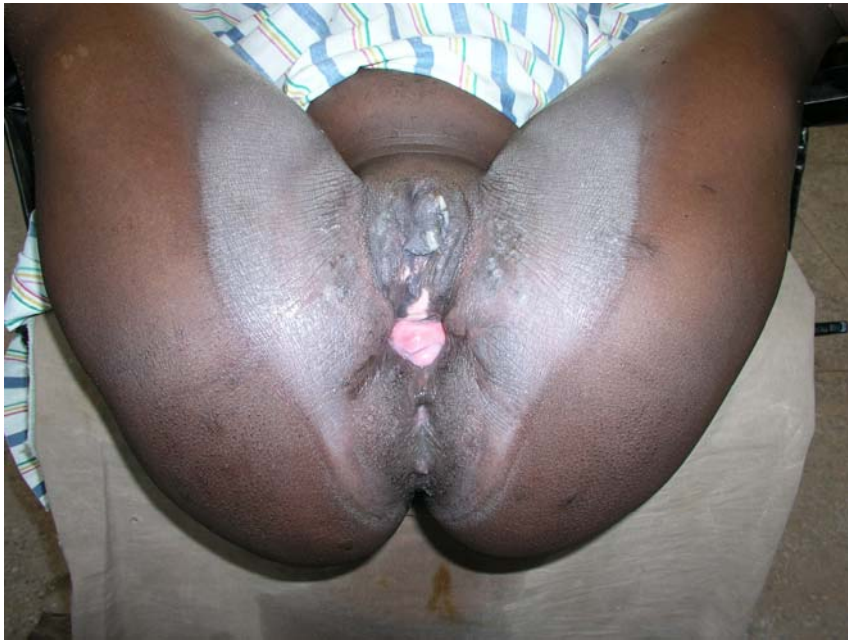slough



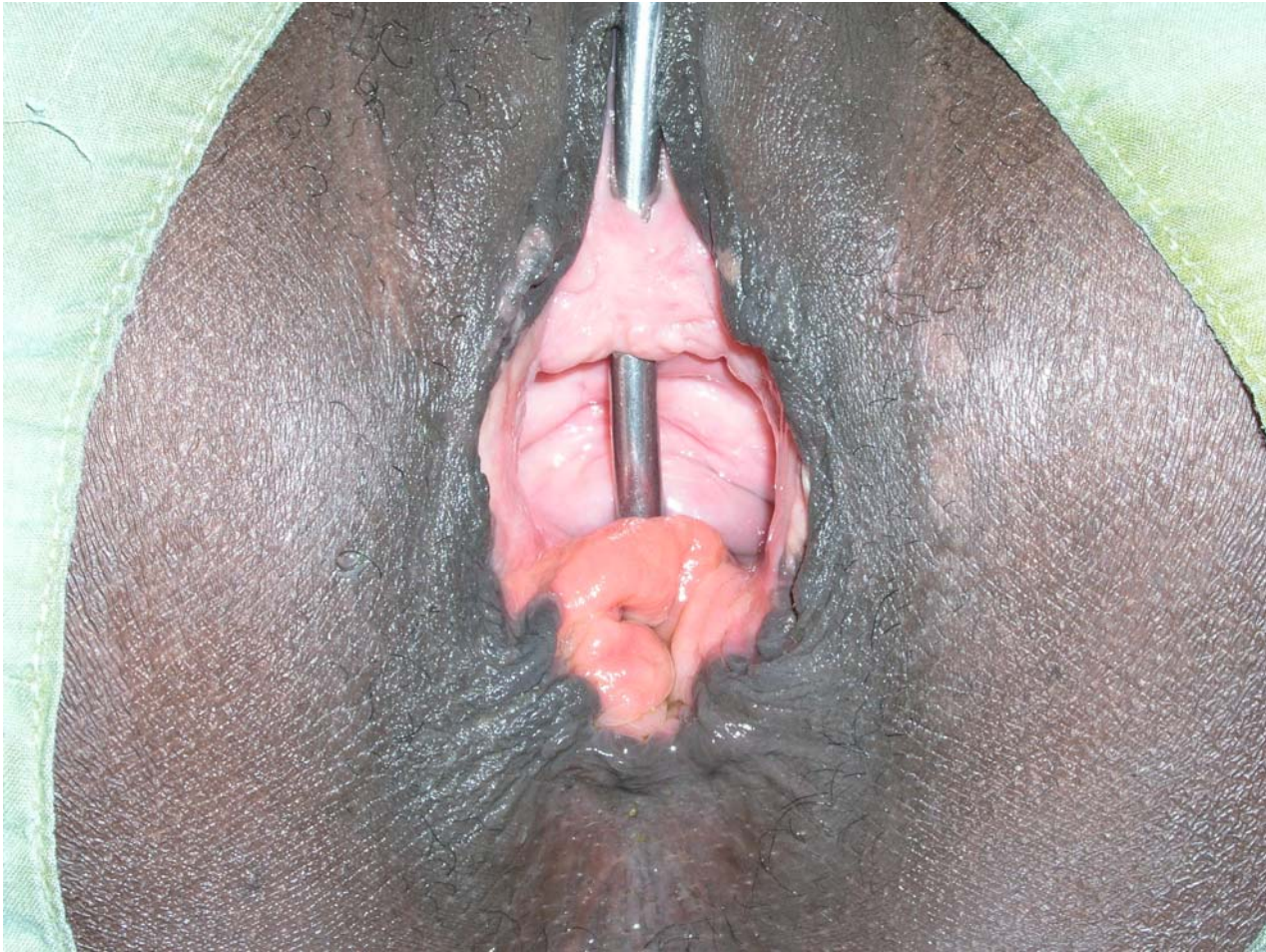
slough plus lochia



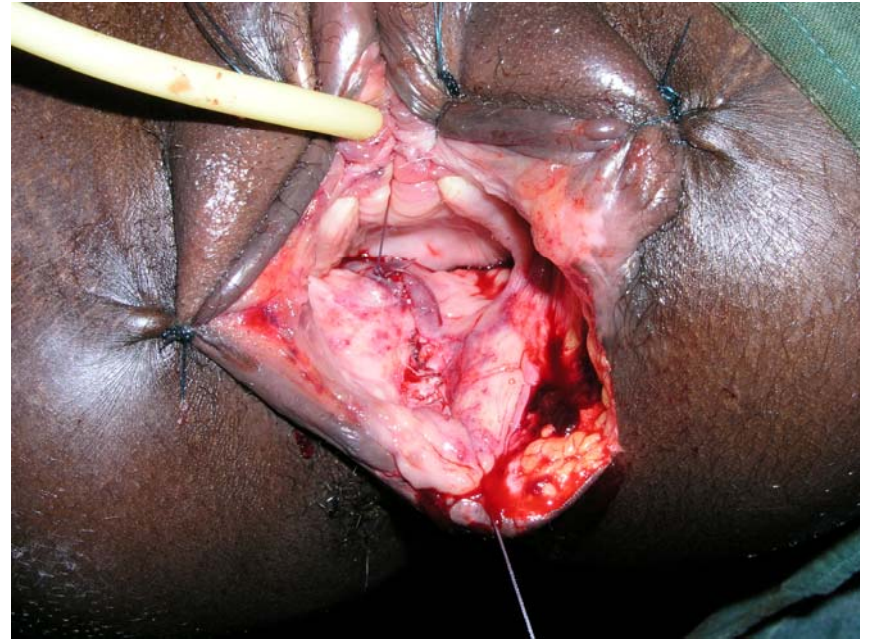
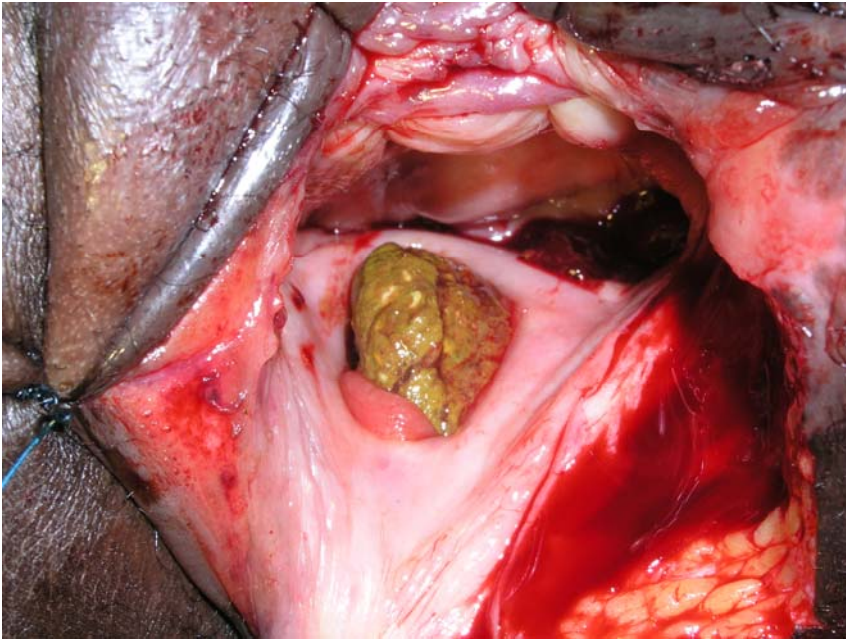
ammonia dermatitis



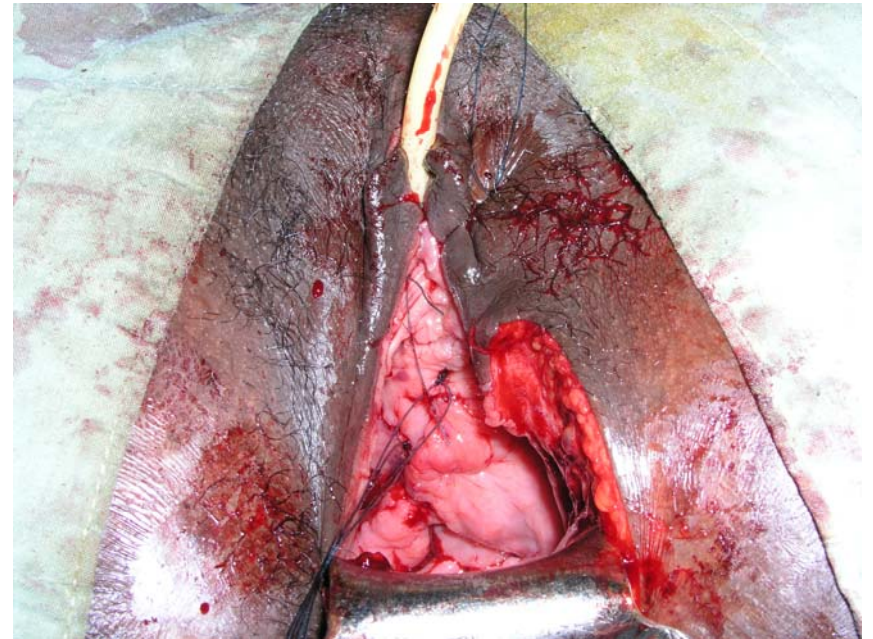
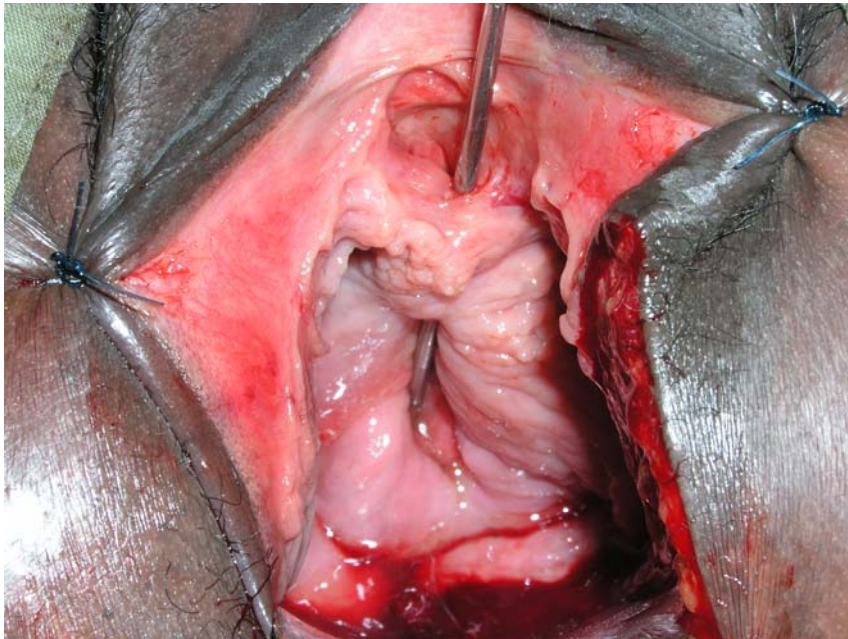
vesico- and rectovaginal fistula



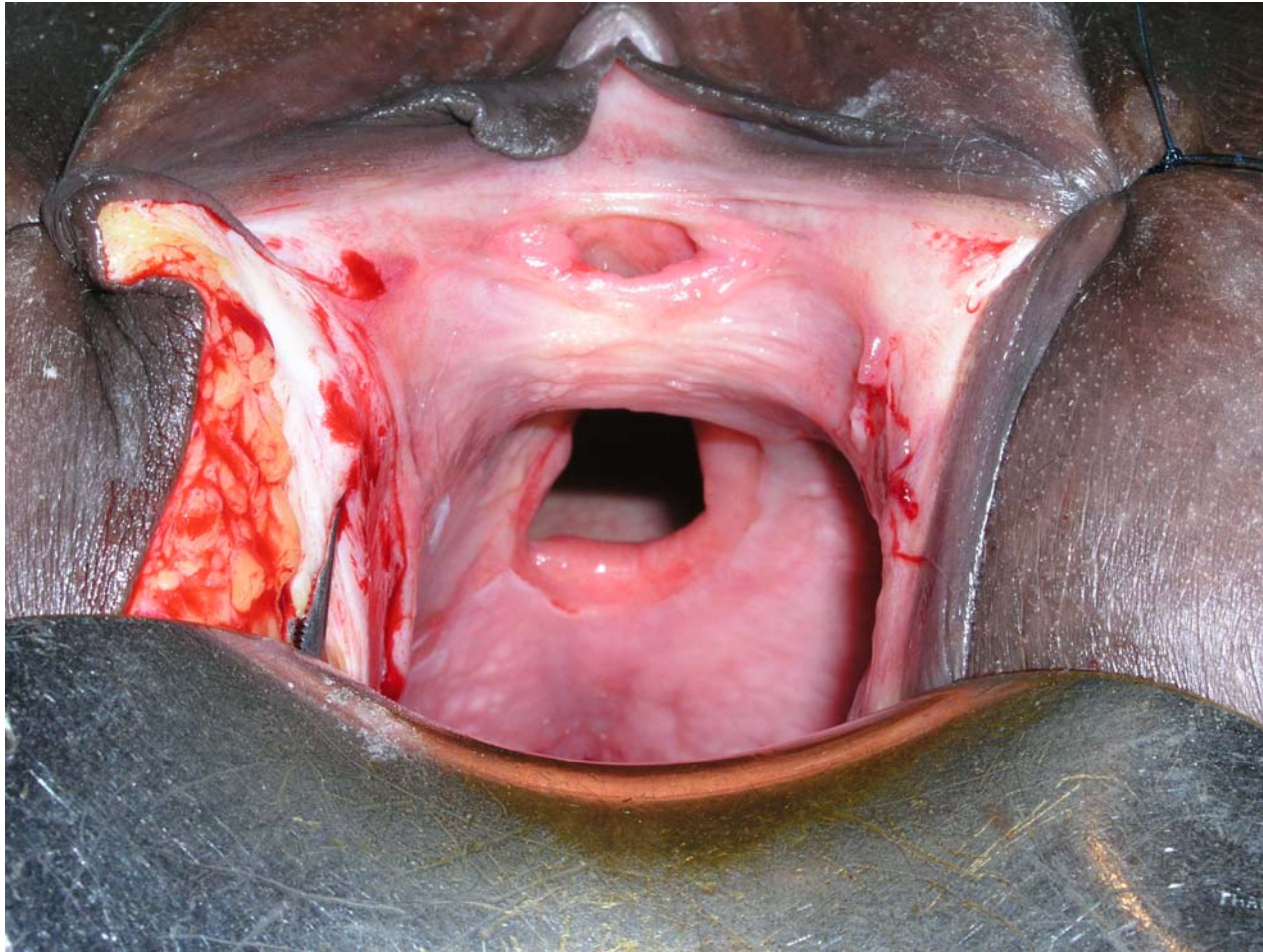
rectovaginal fistula



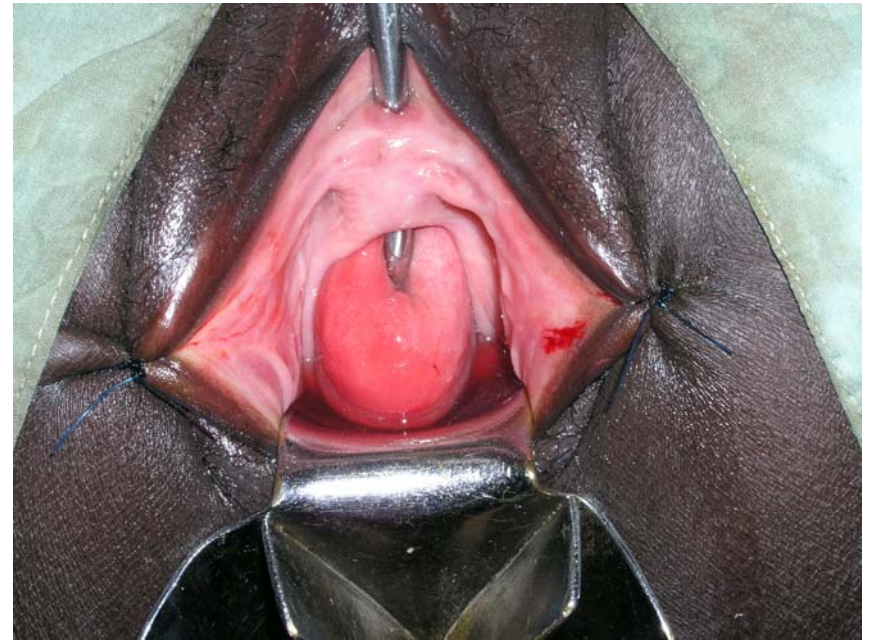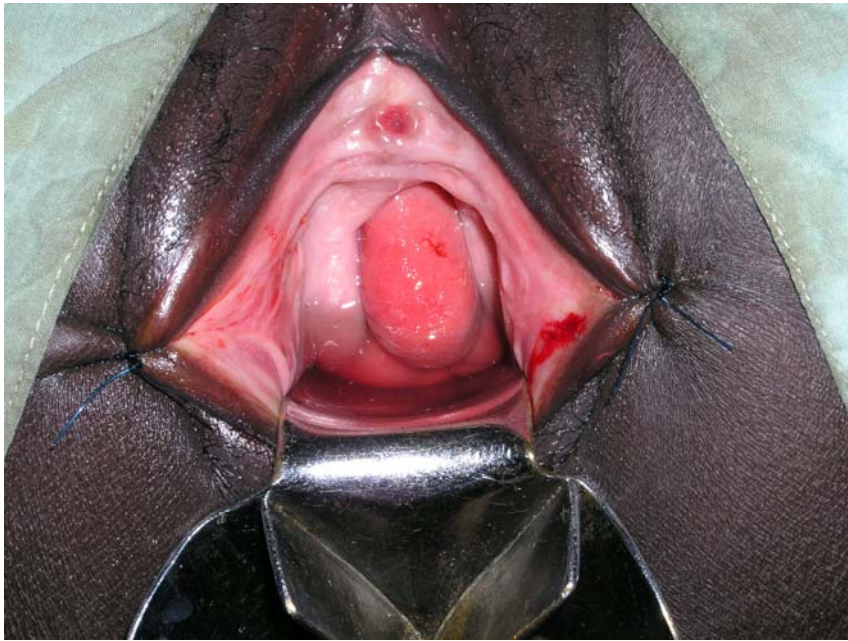urethra trauma and fistula



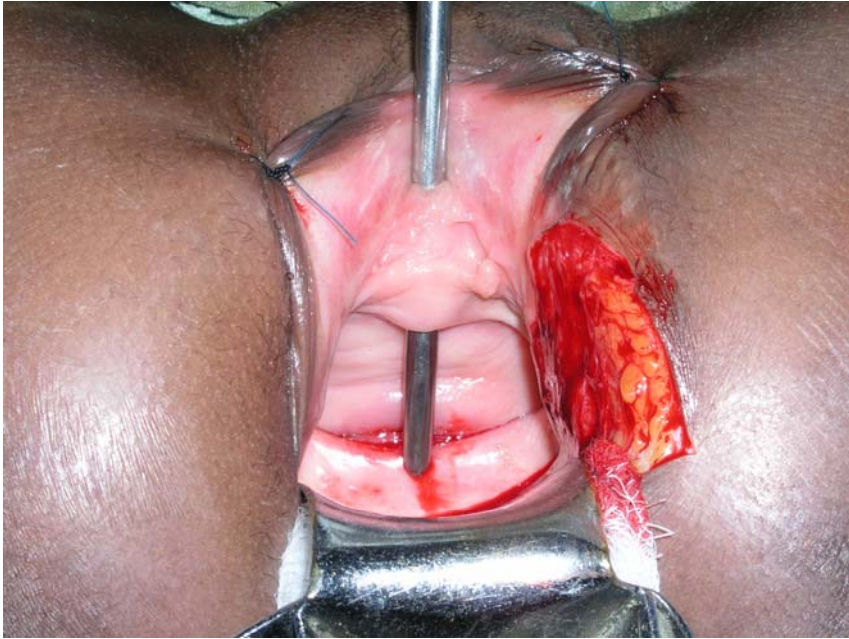
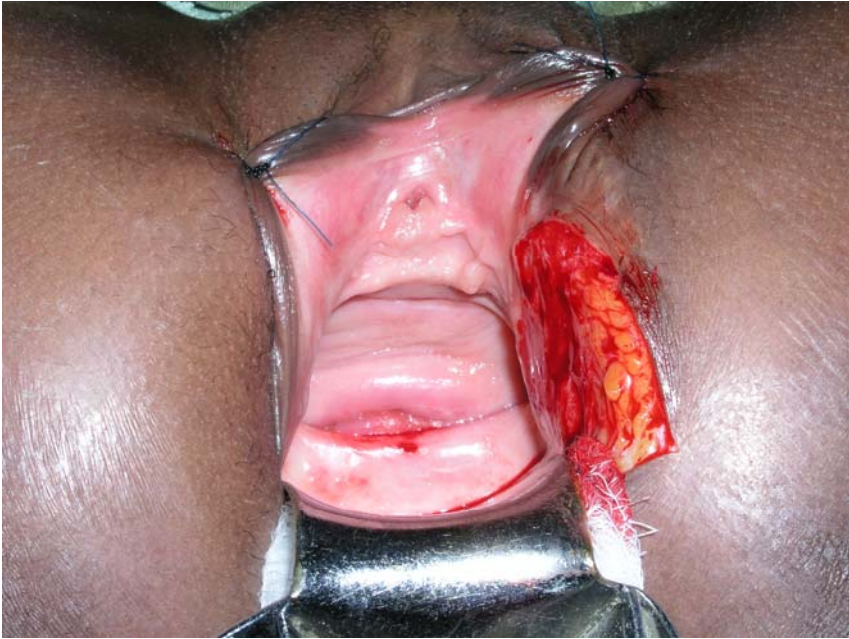open urethra_external urethra opening



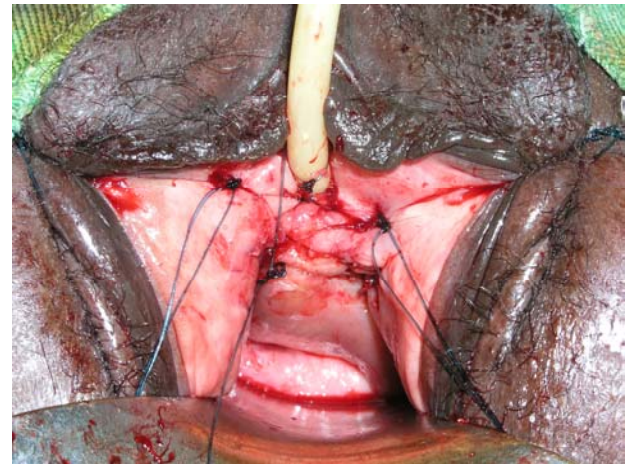
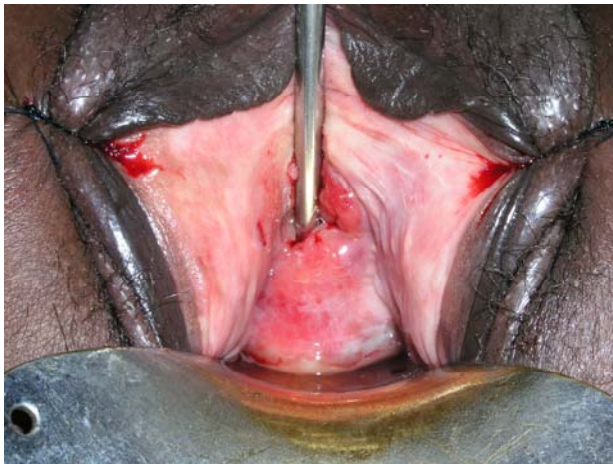
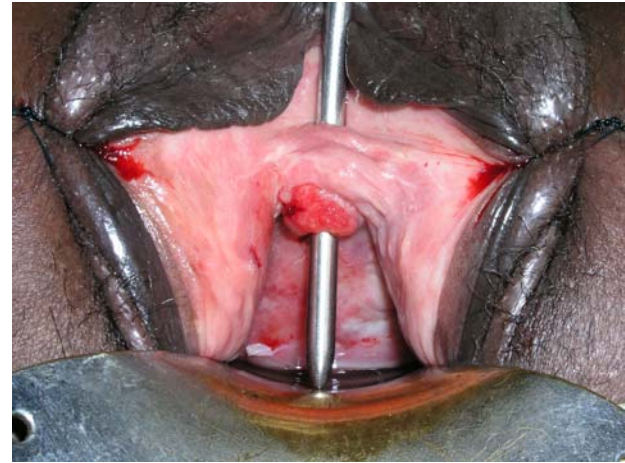
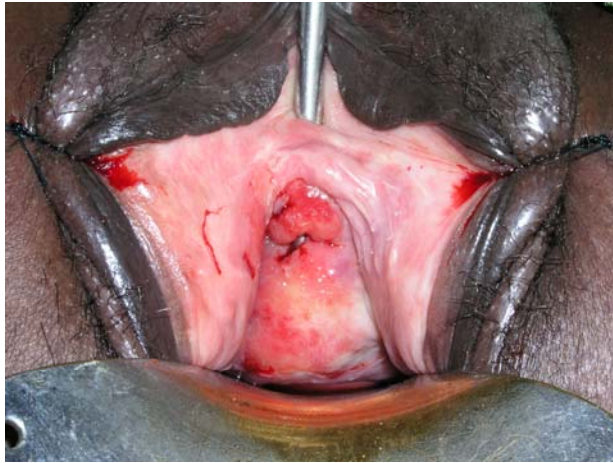bladder base prolapse



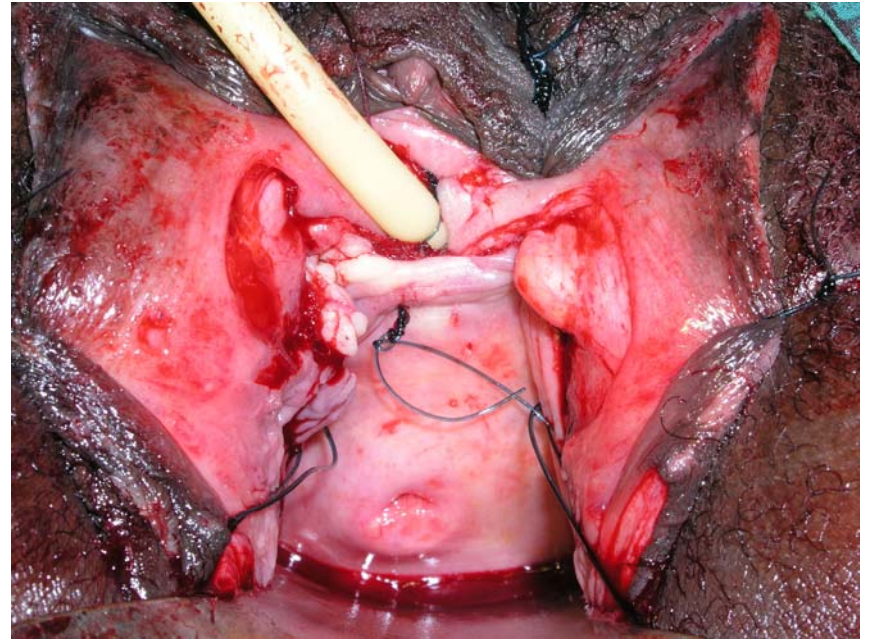
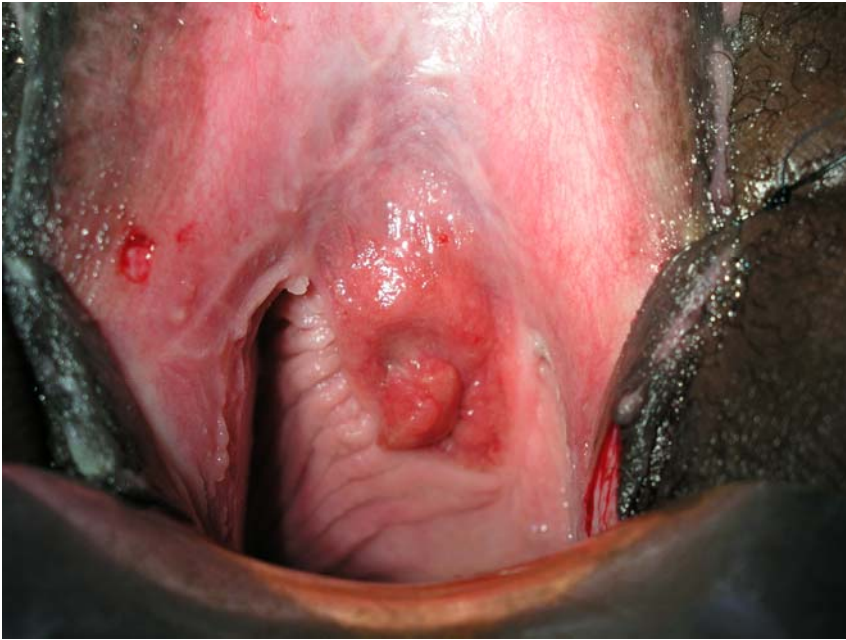posterior vagina wall stricture



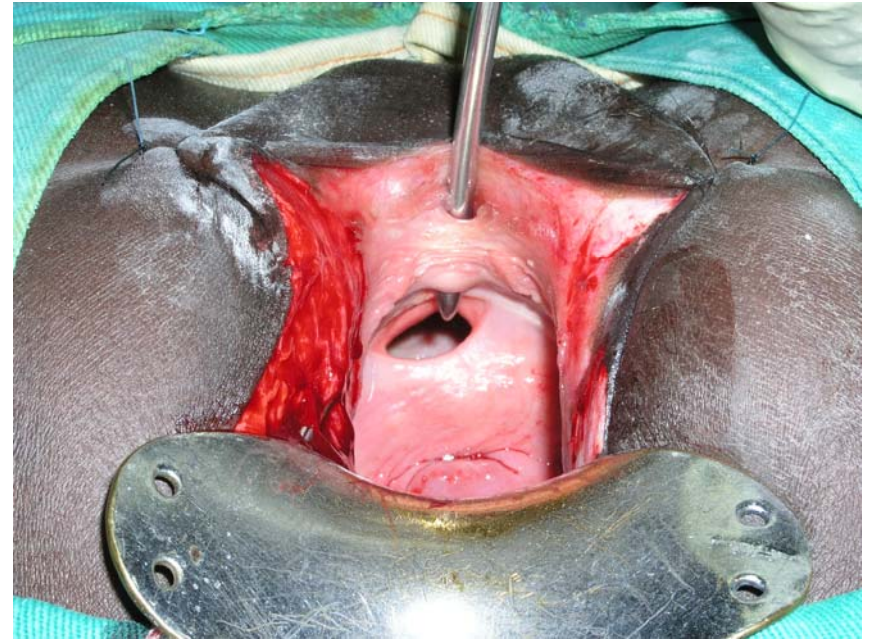
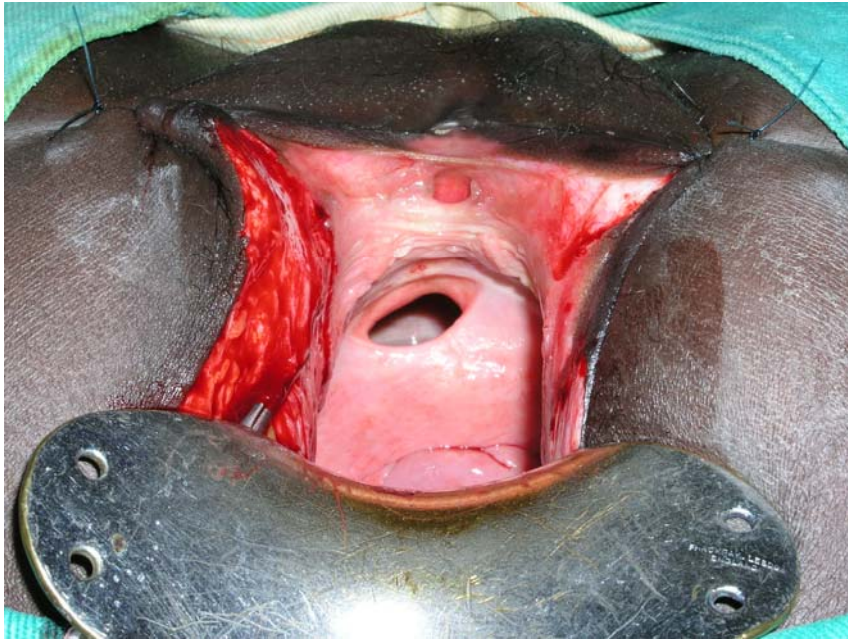
fresh fistula



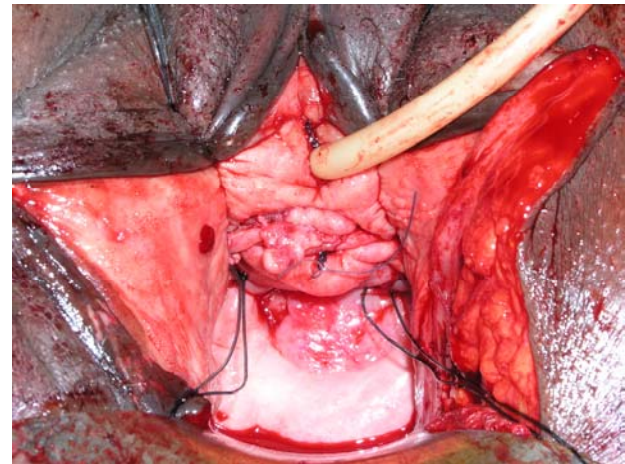
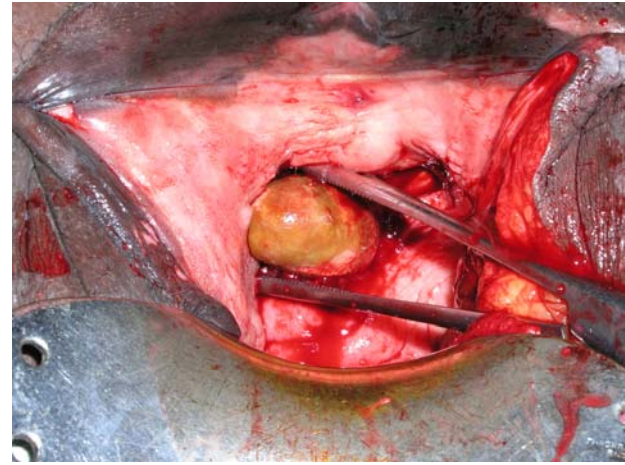
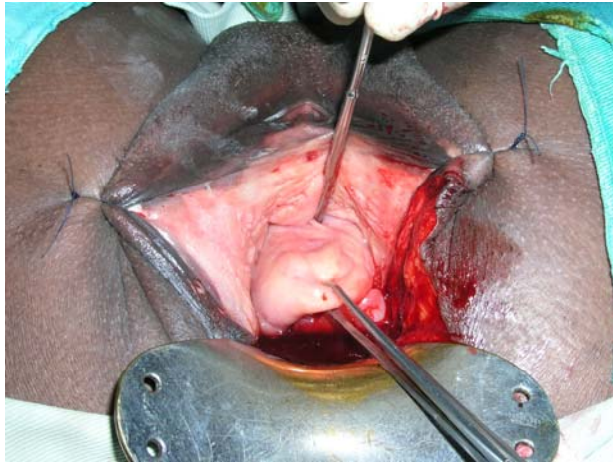
yankan gishiri fistula



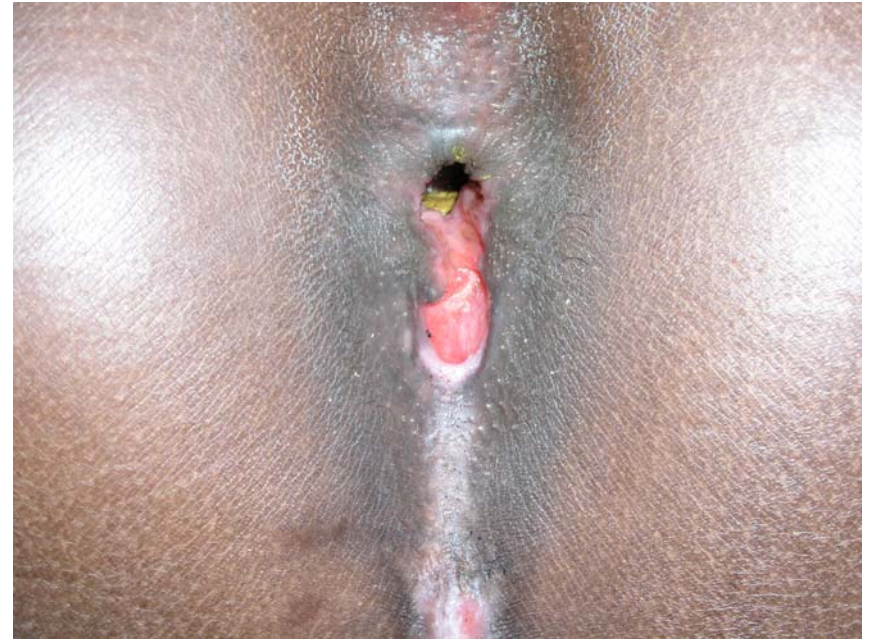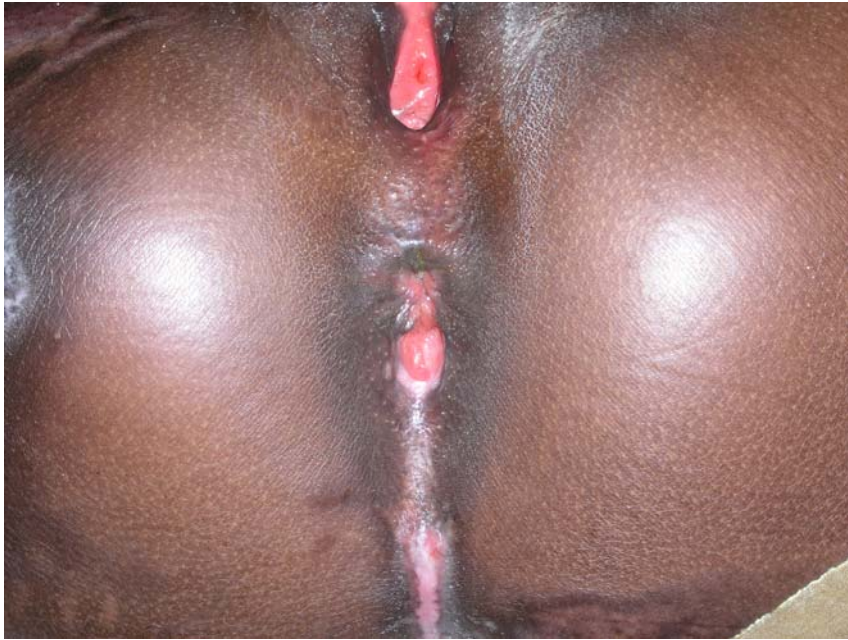circumferential defect



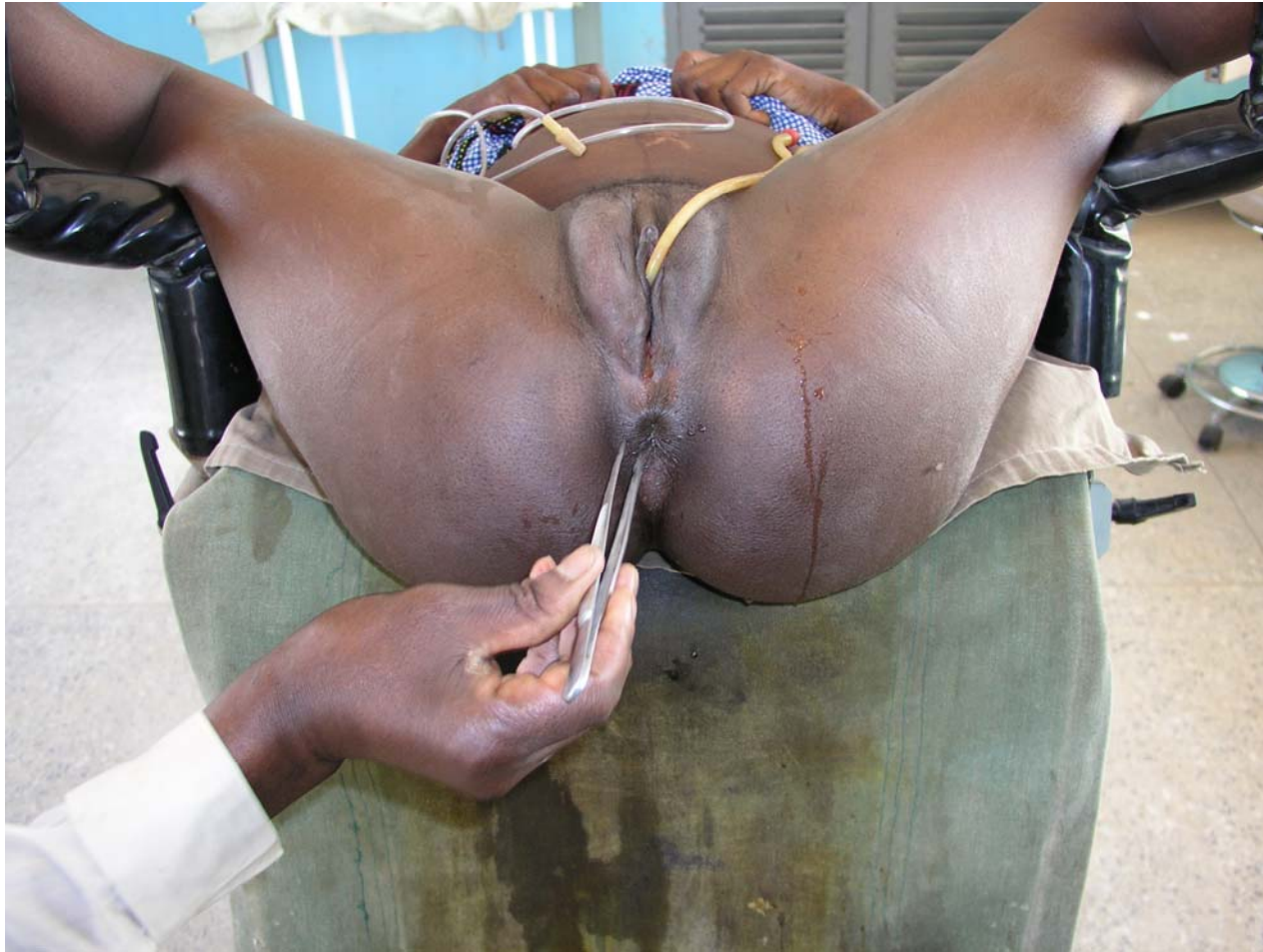complex trauma



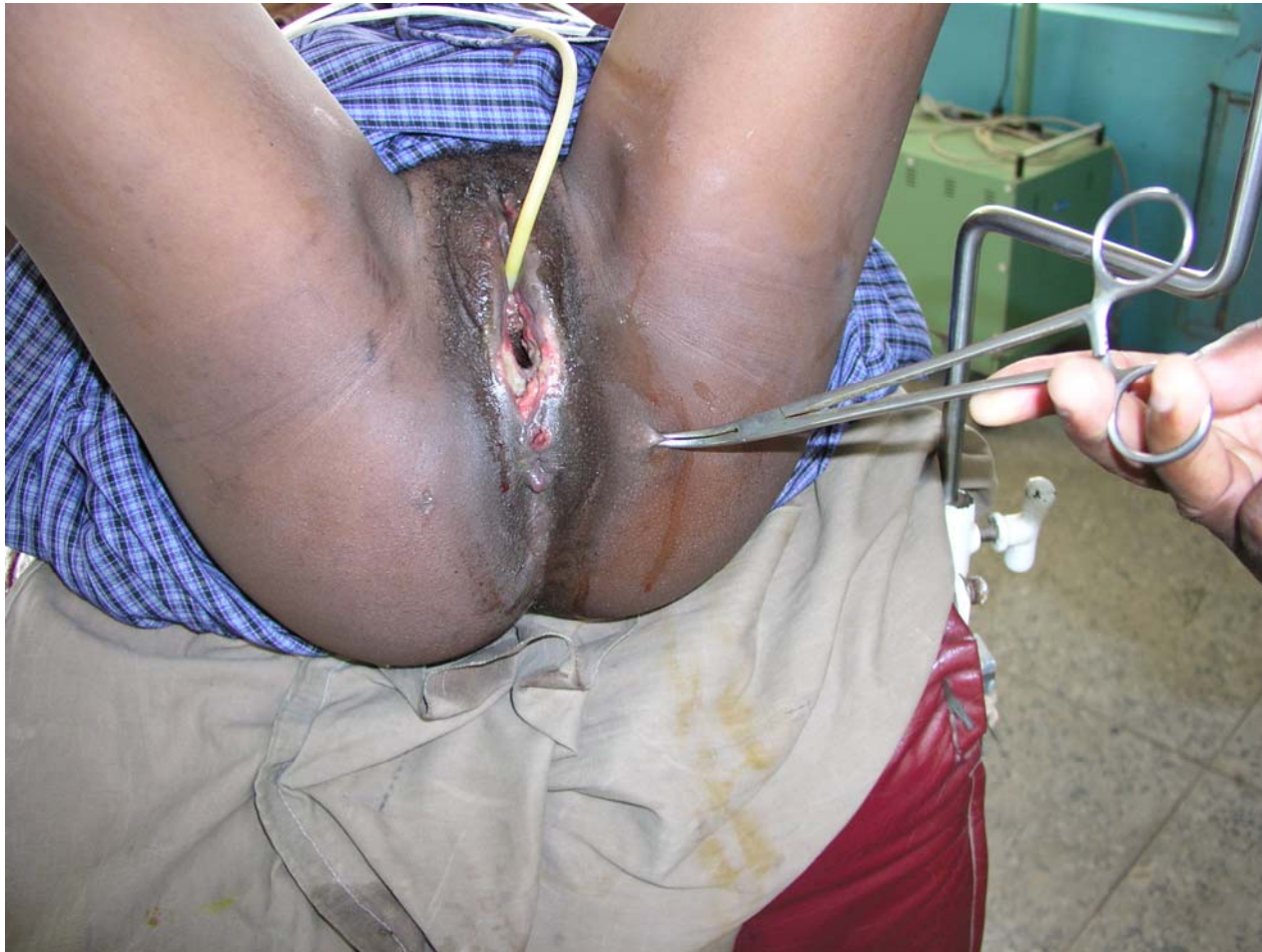posterior sphincter trauma



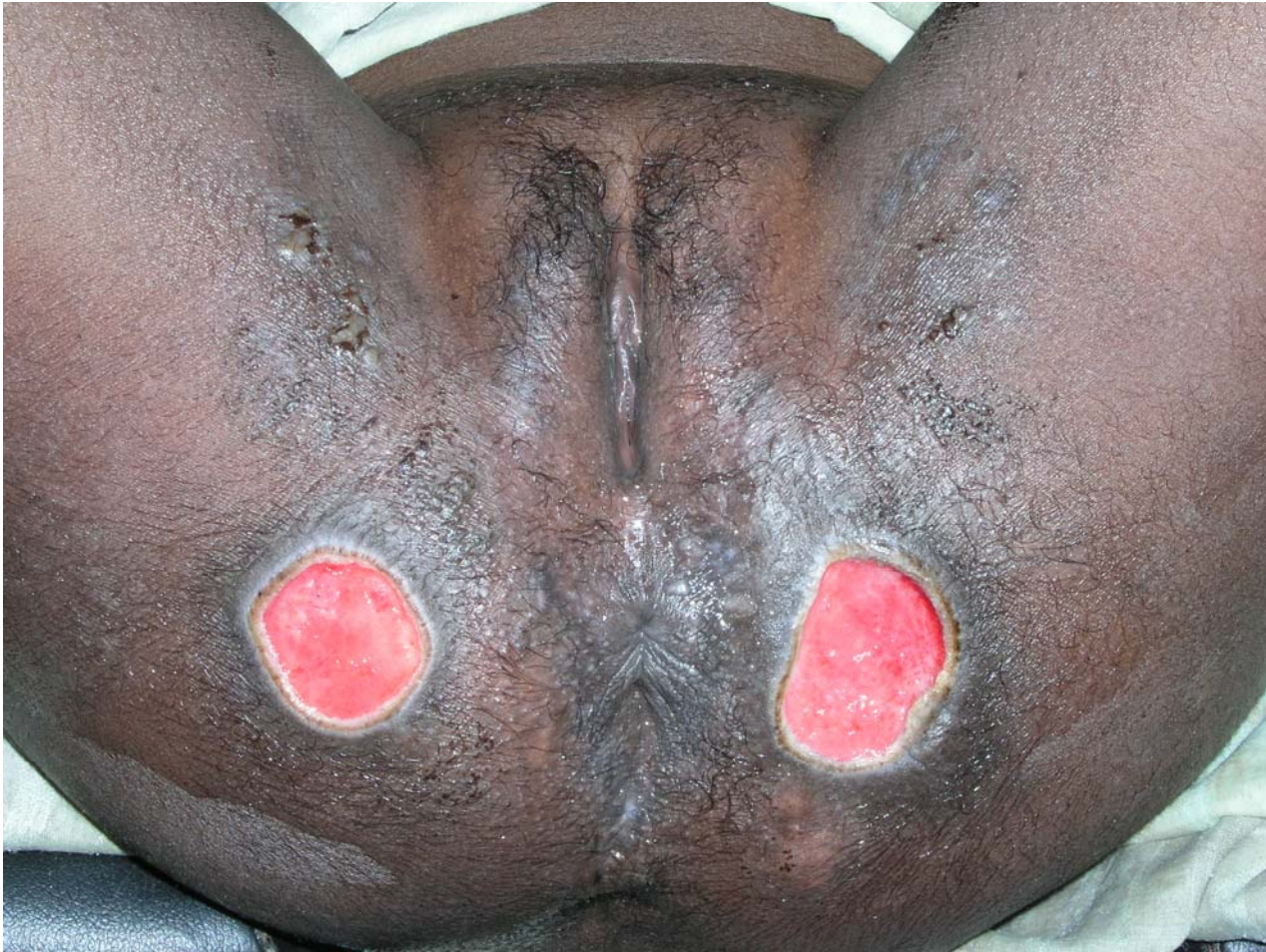anal reflex



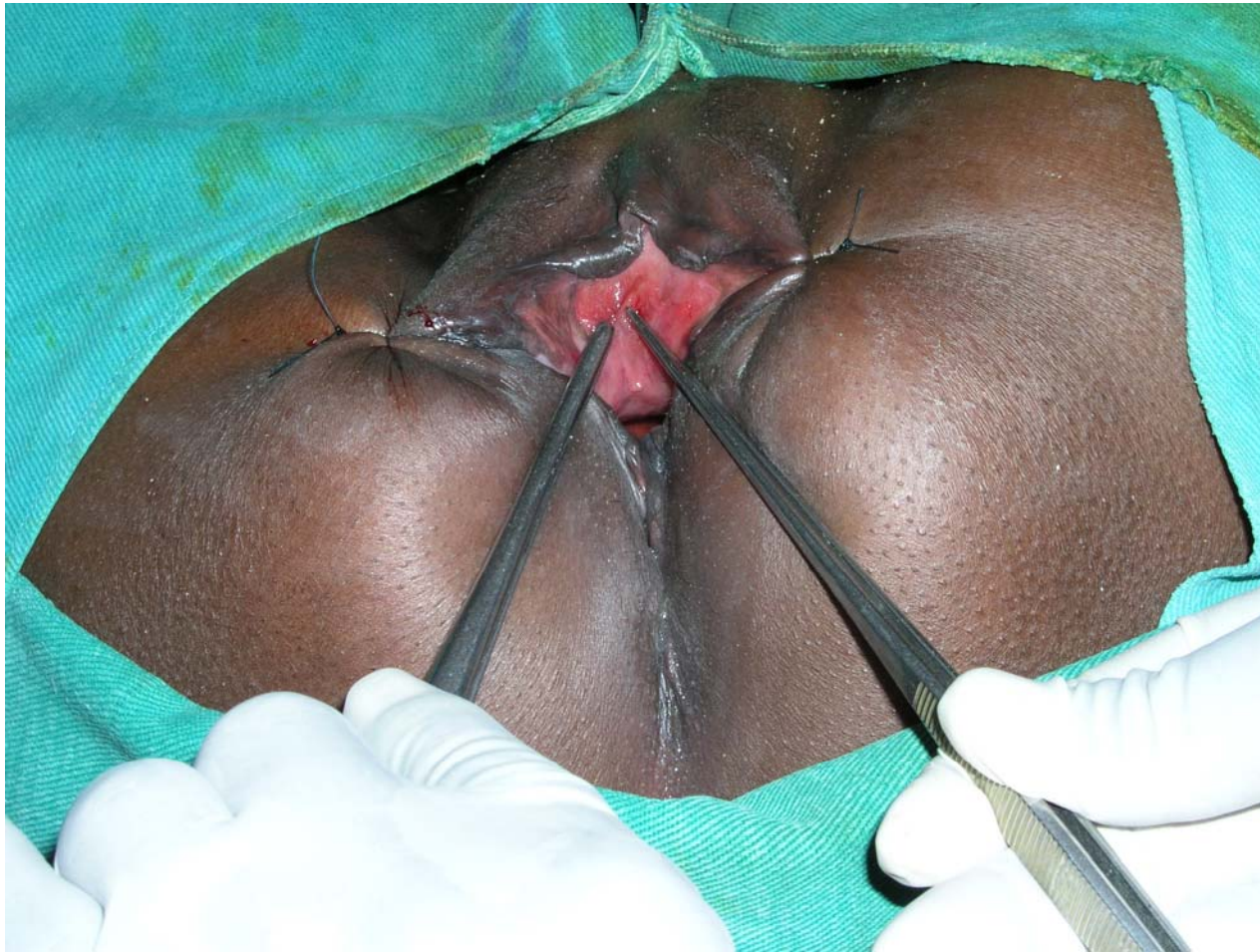saddle anesthesia



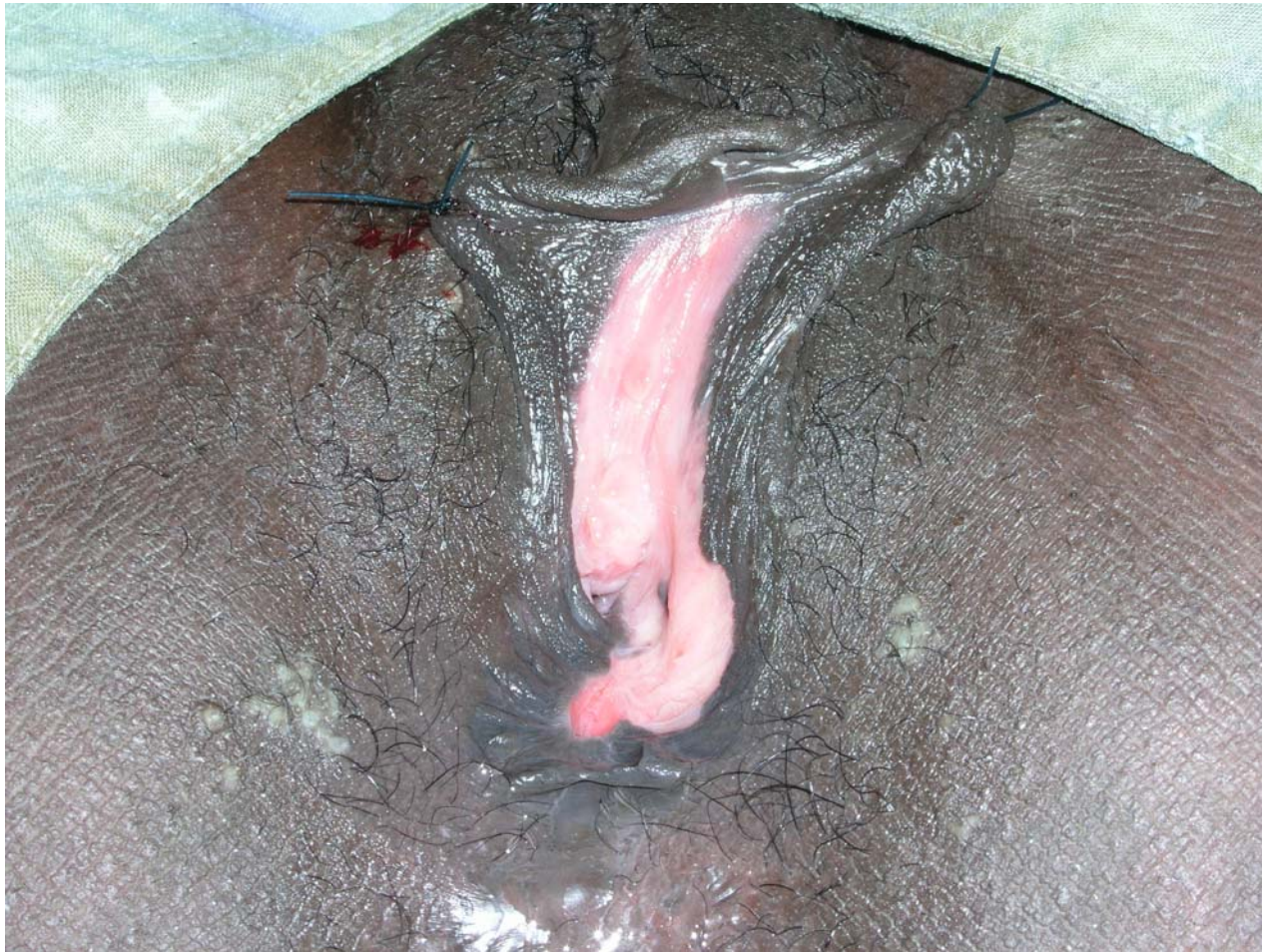long-standing saddle anesthesia



narrow pubic arch

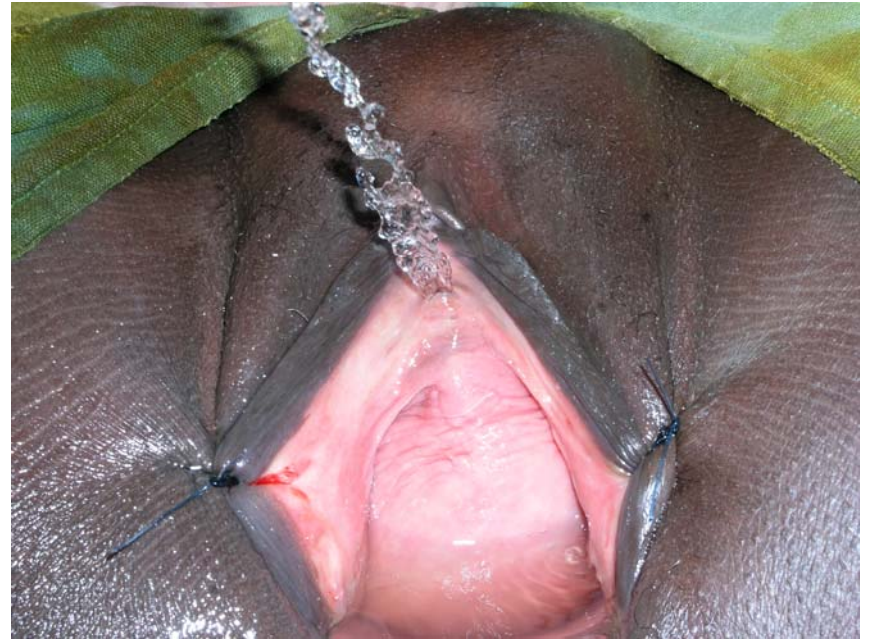
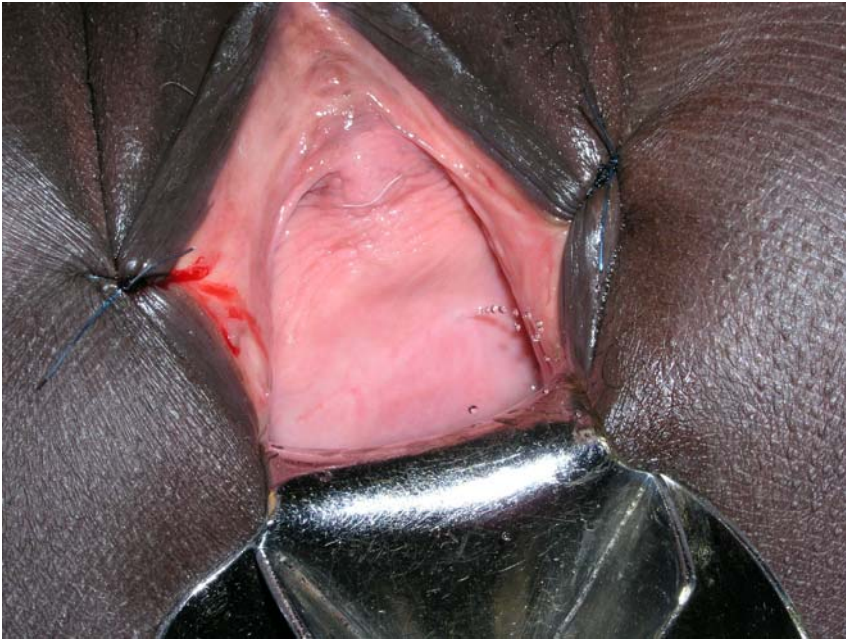
vagina atresia

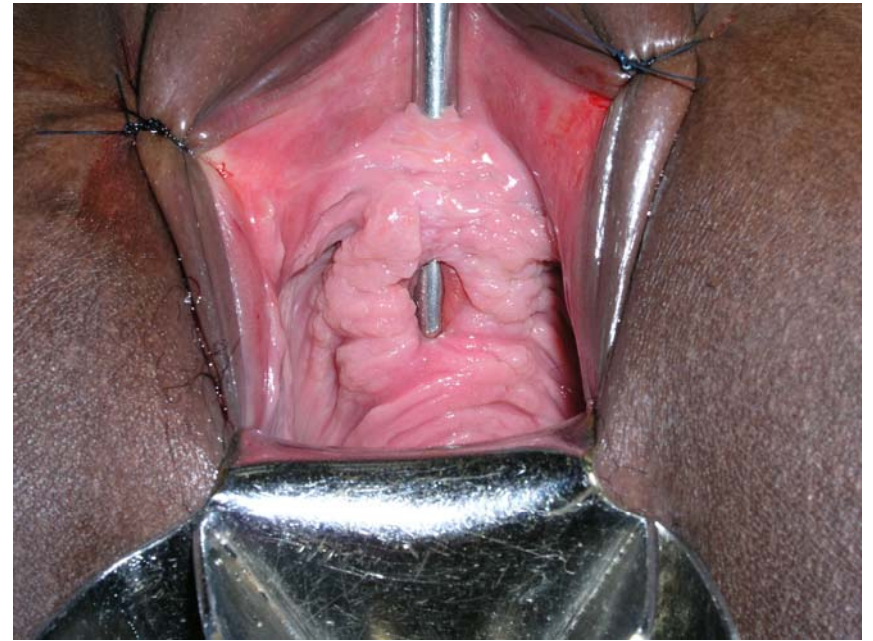
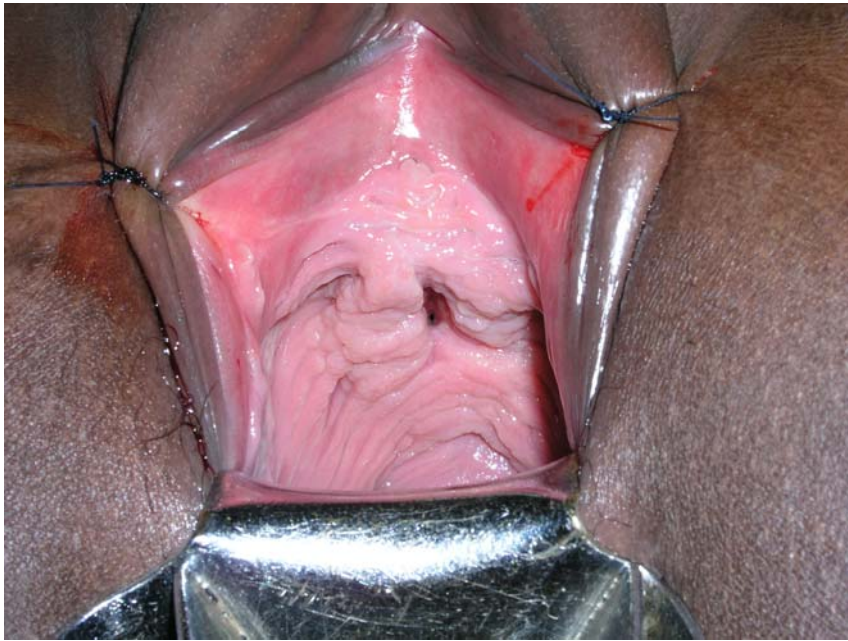

minute fistula

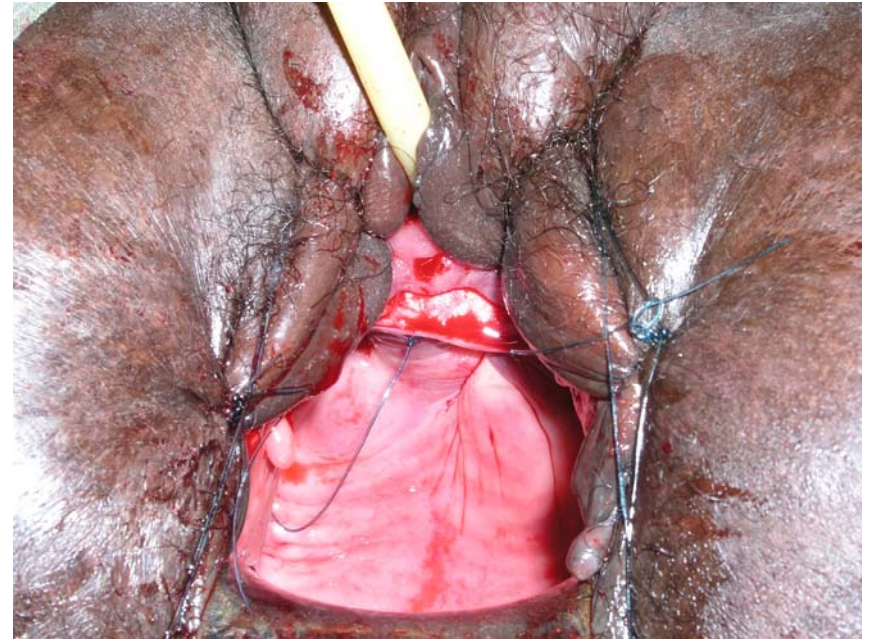
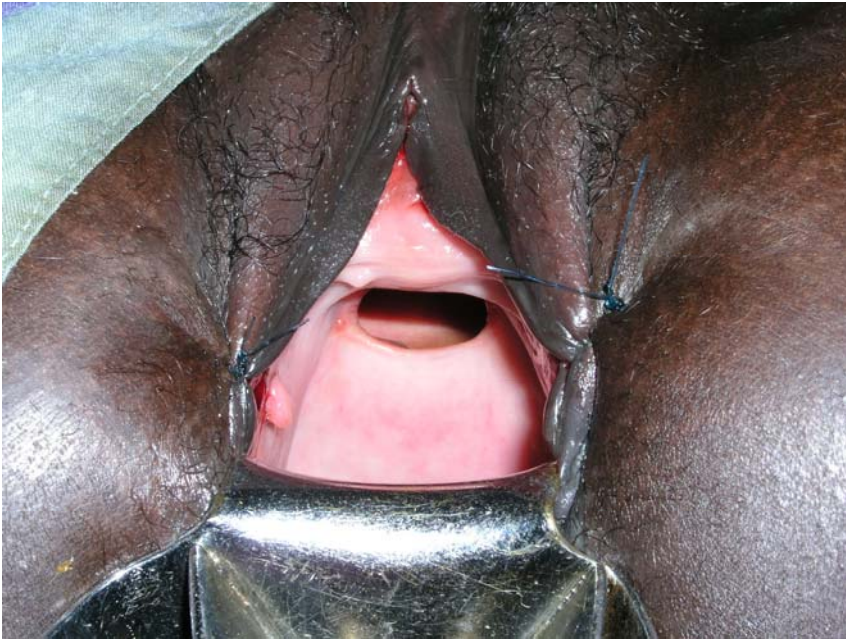with stress incontinence



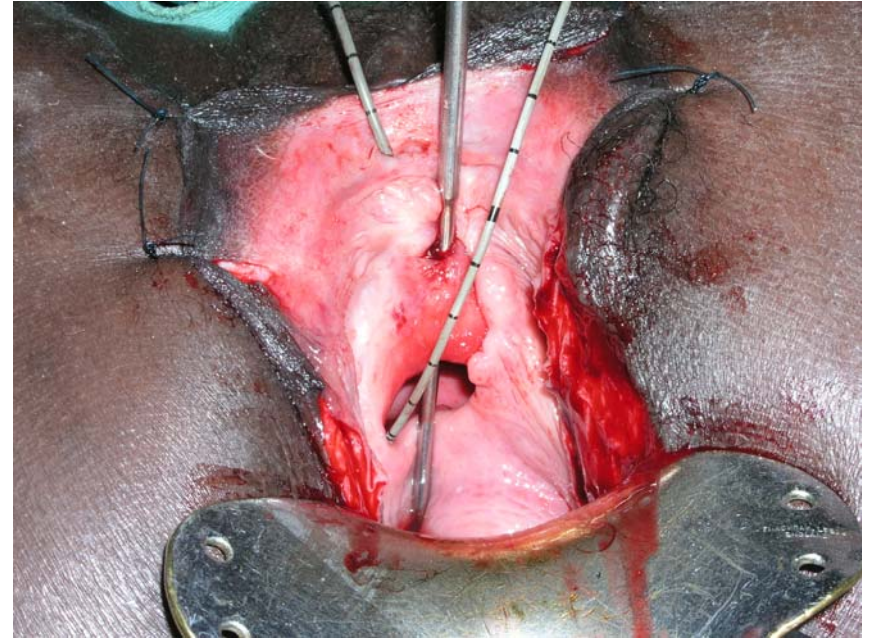
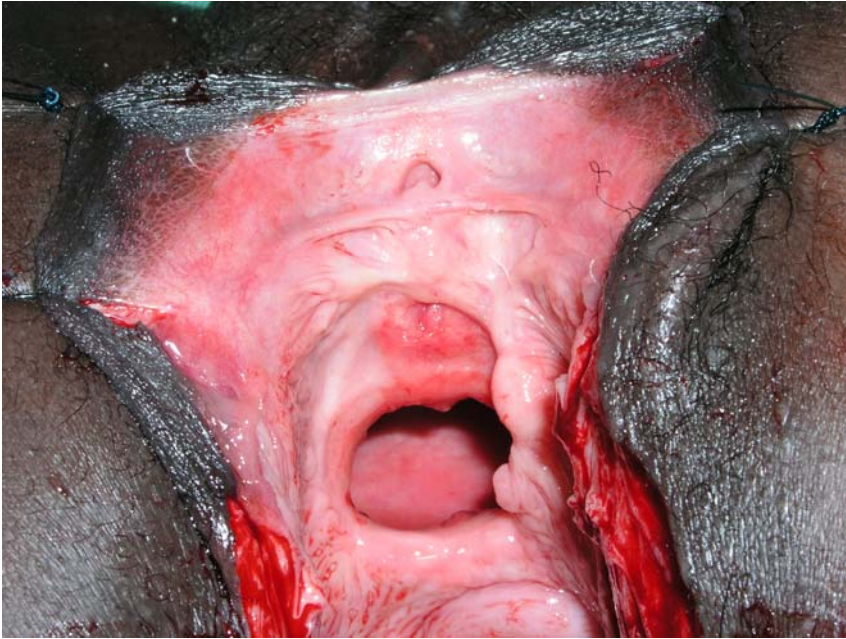small fistula



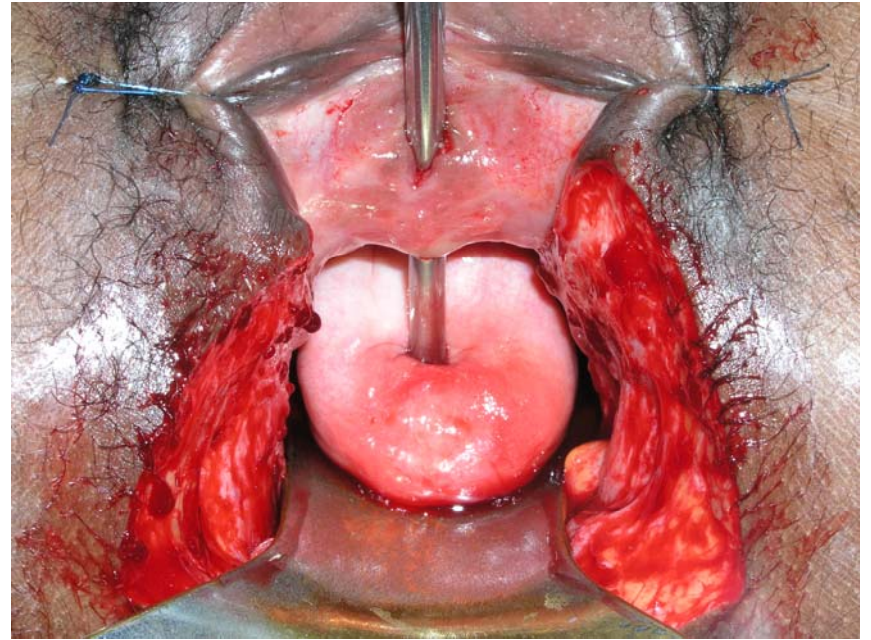
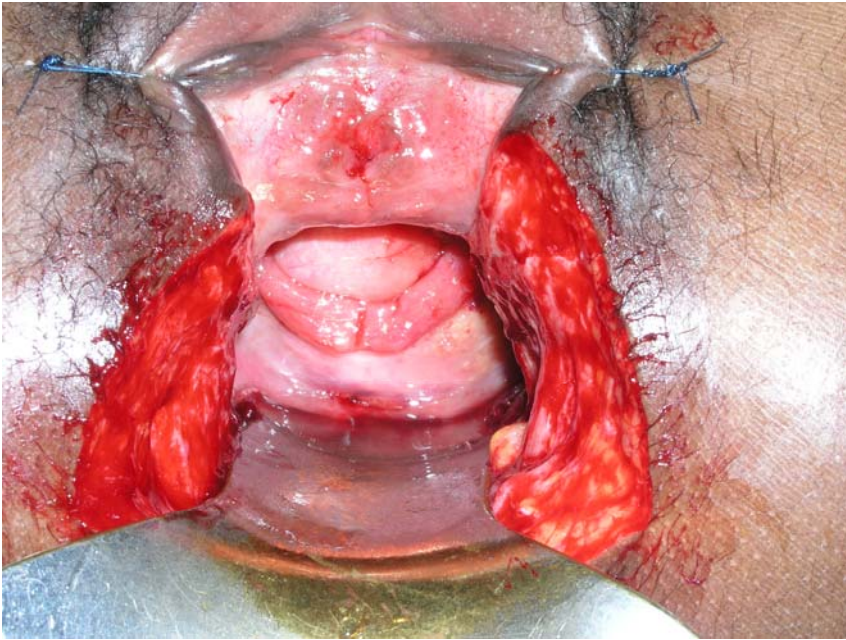
medium fistula



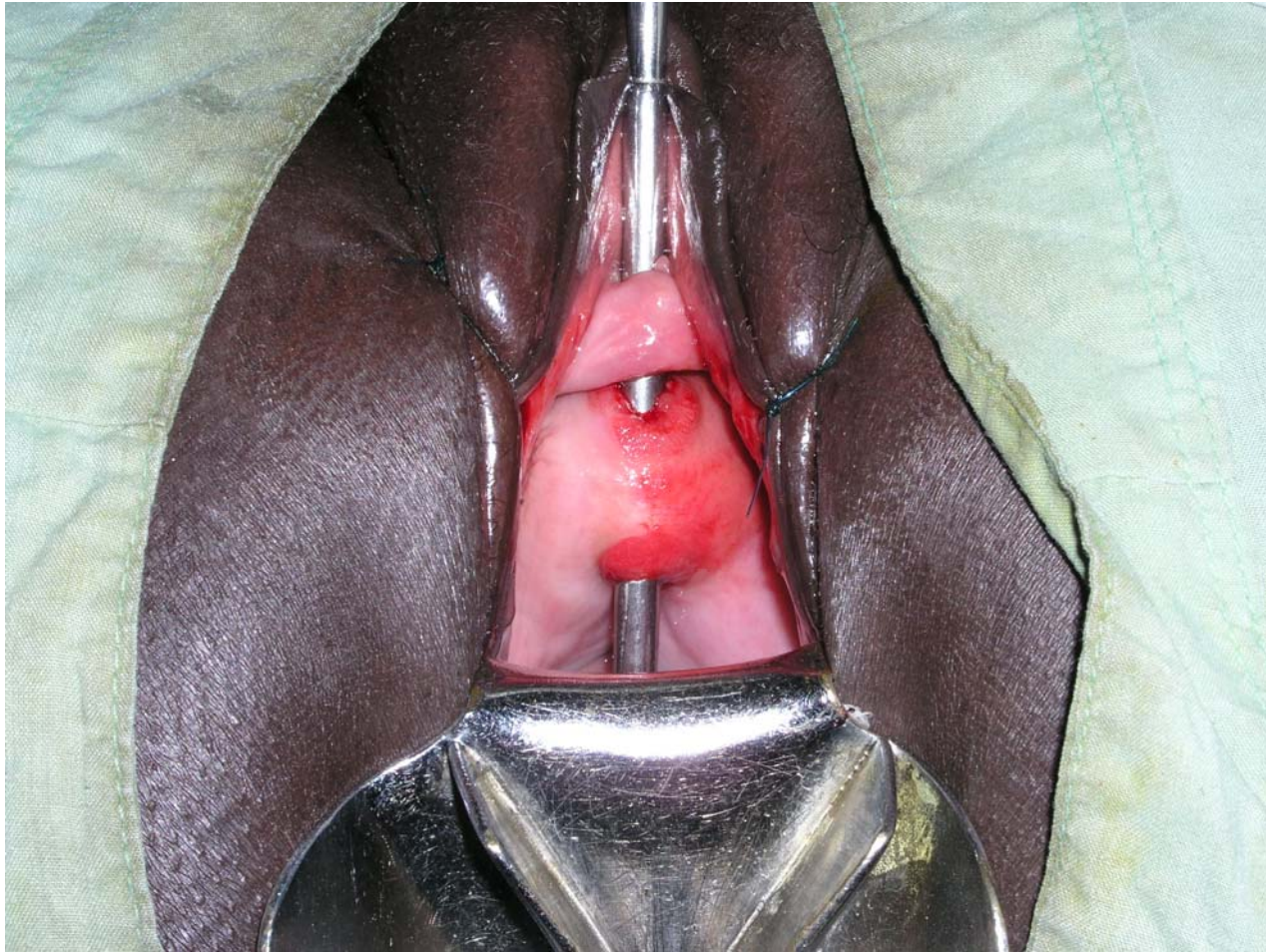
large fistula



extensive fistula

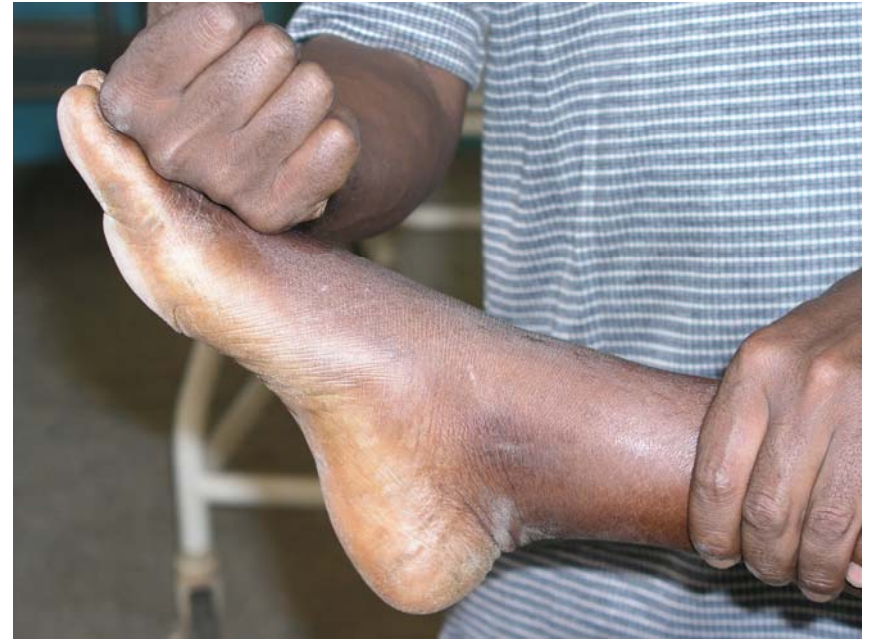

double fistula

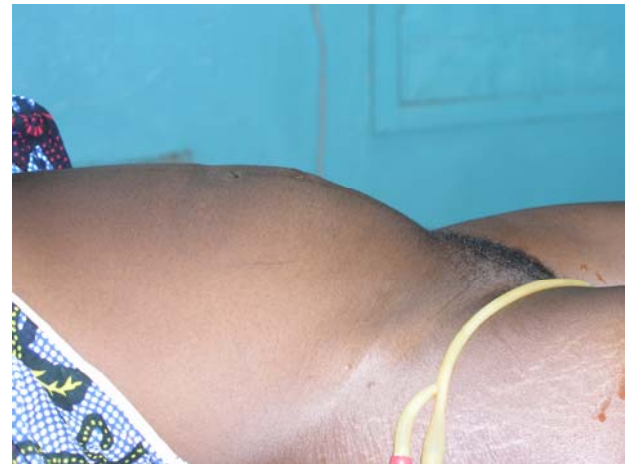
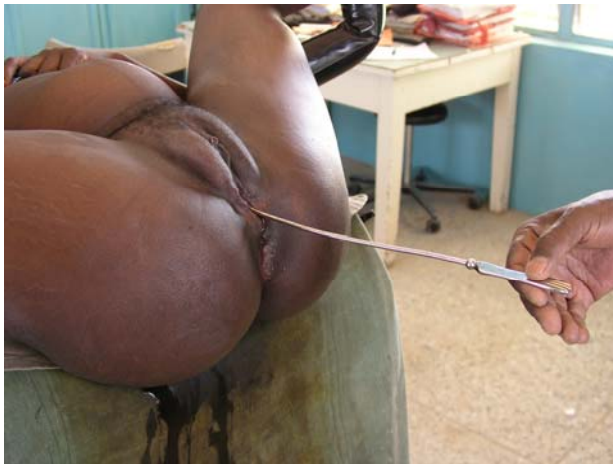
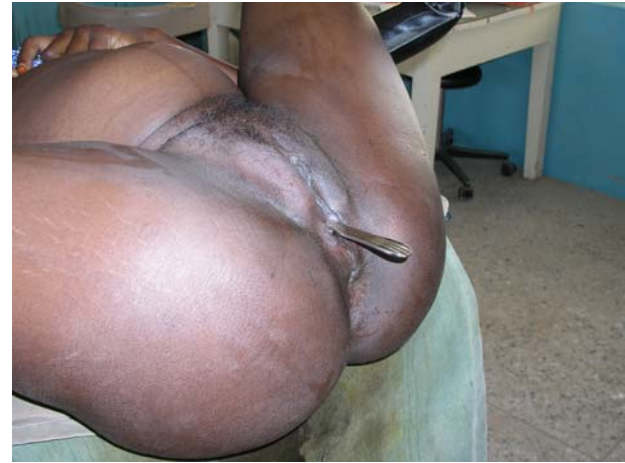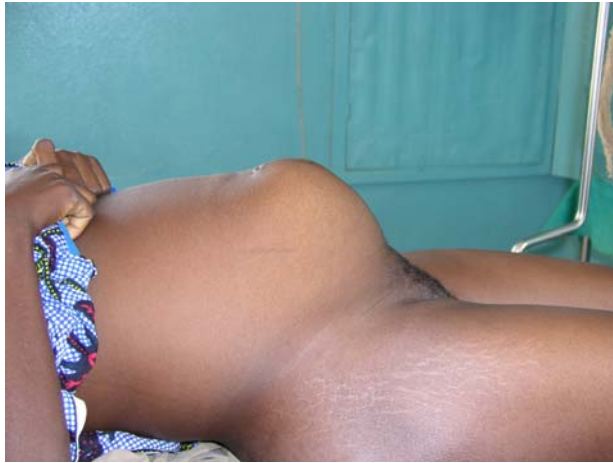drop foot

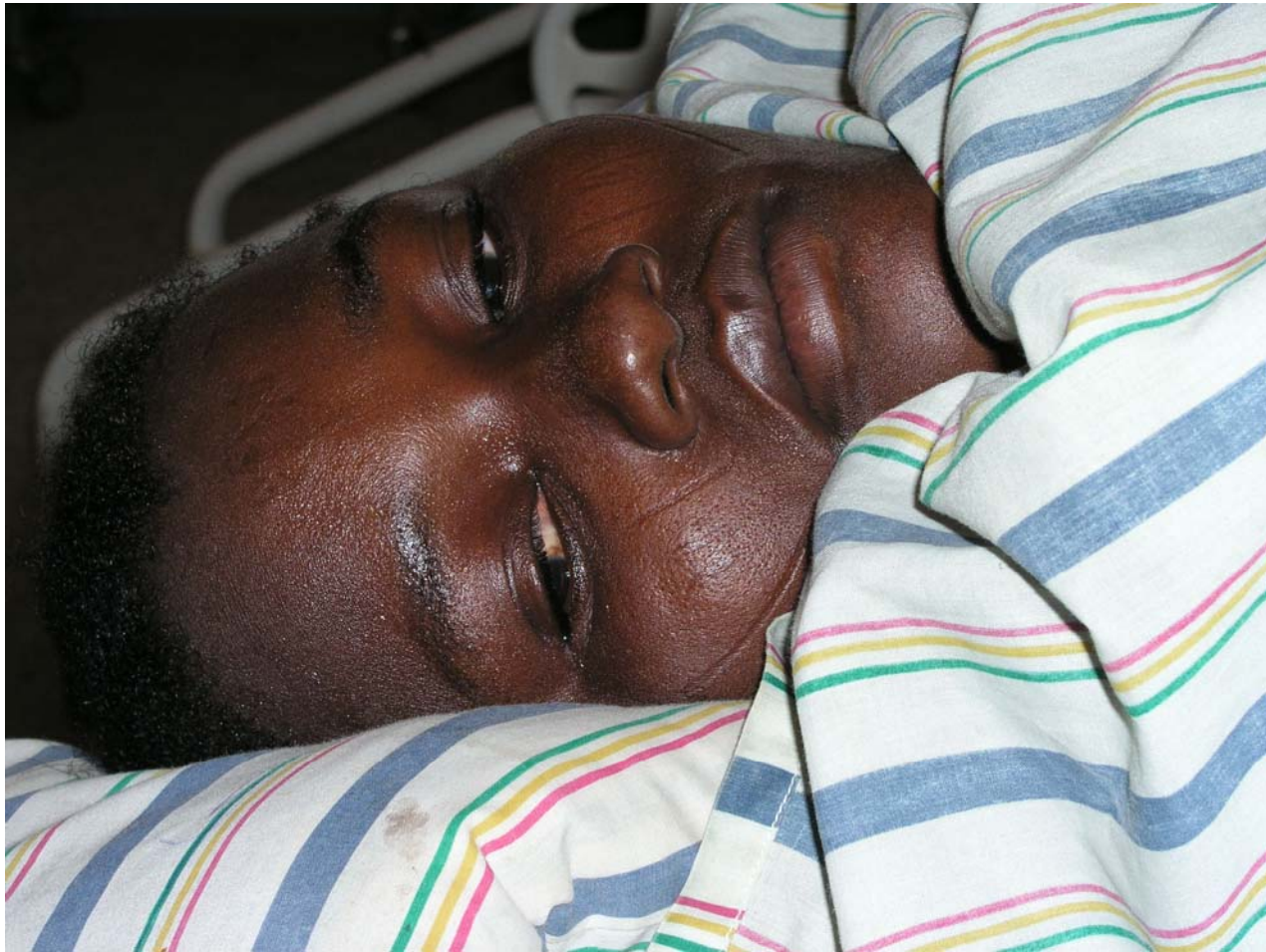in 85%



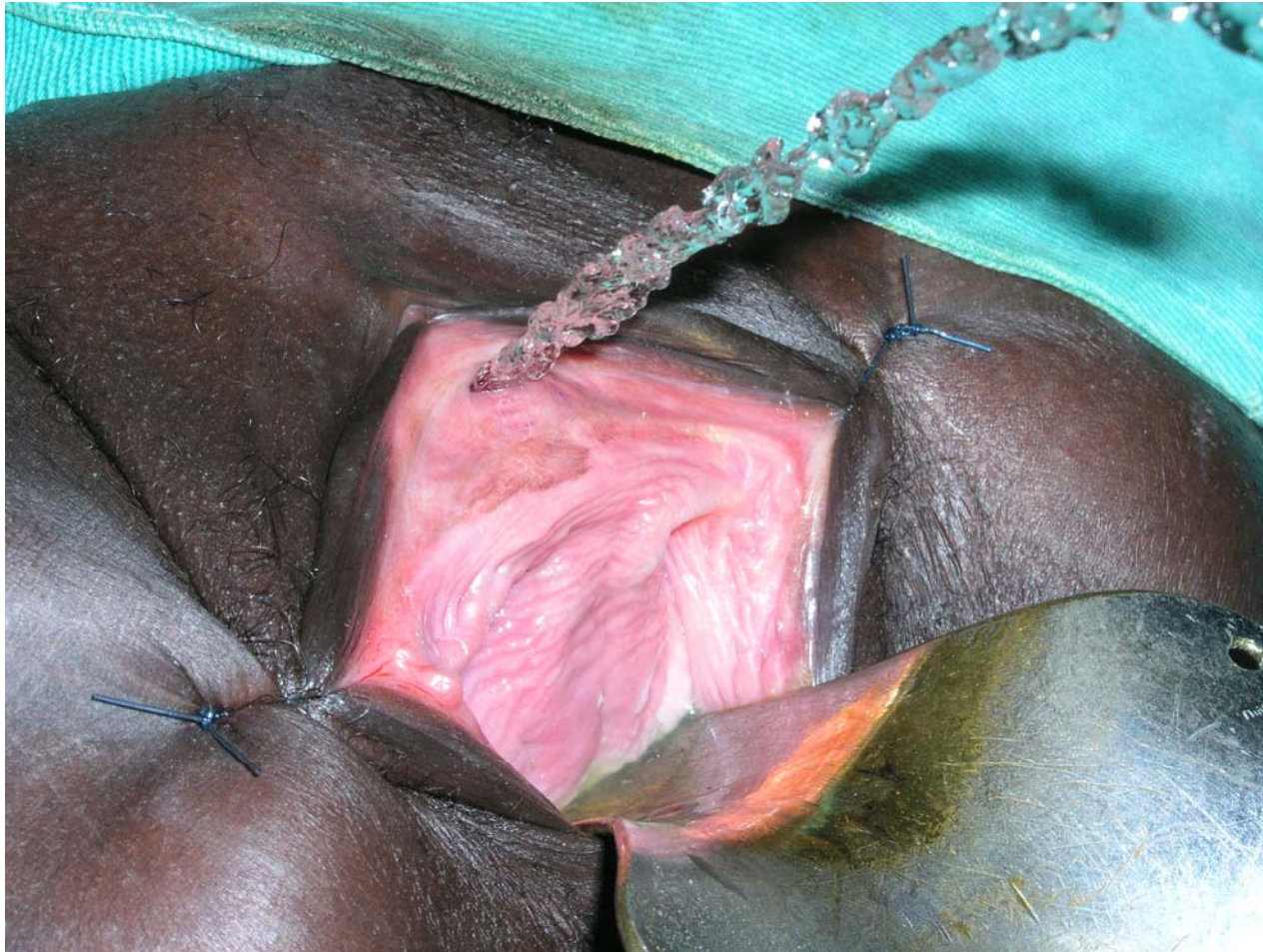
postpartum atonic bladder



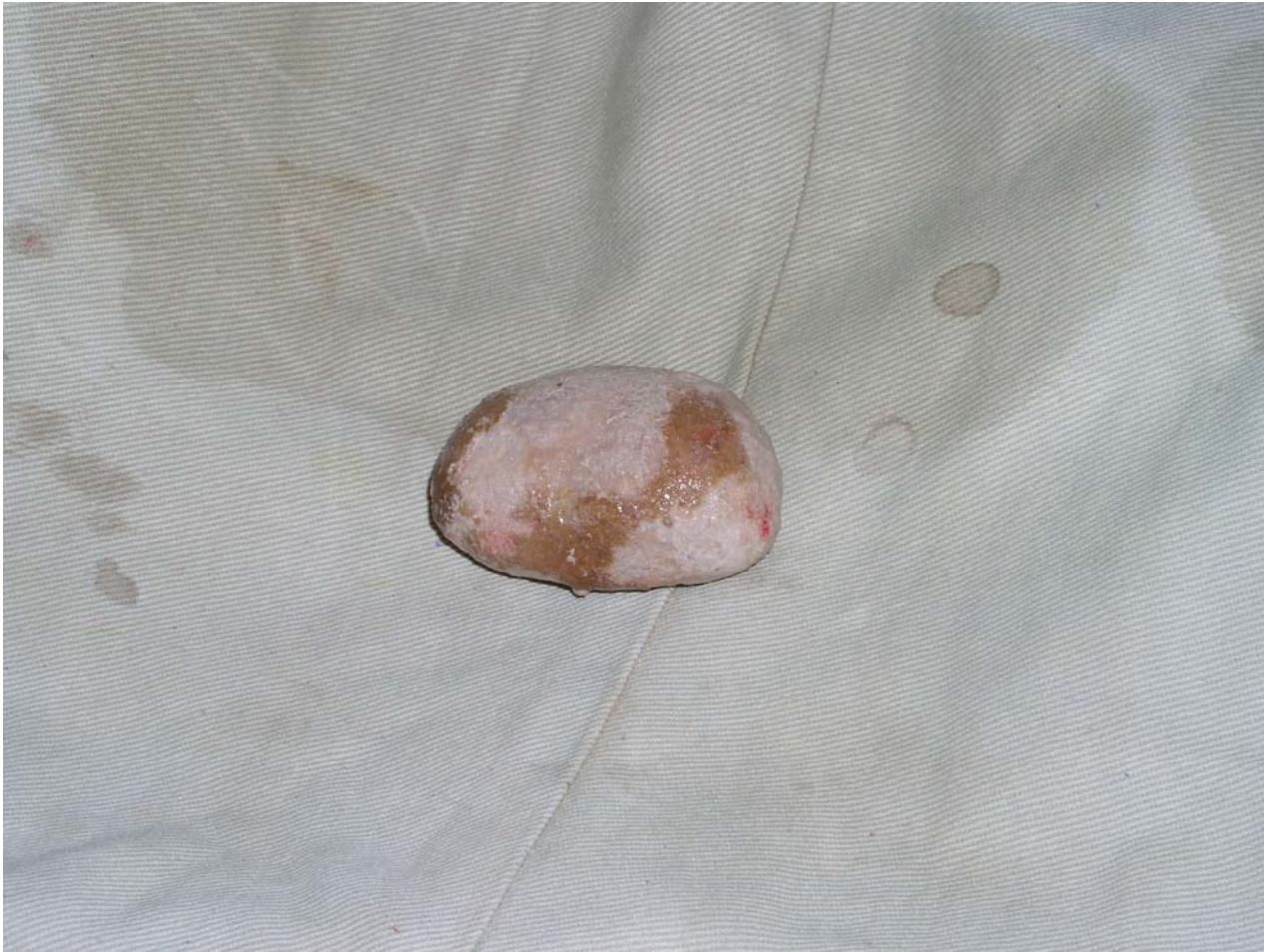70% younger than 20 yr



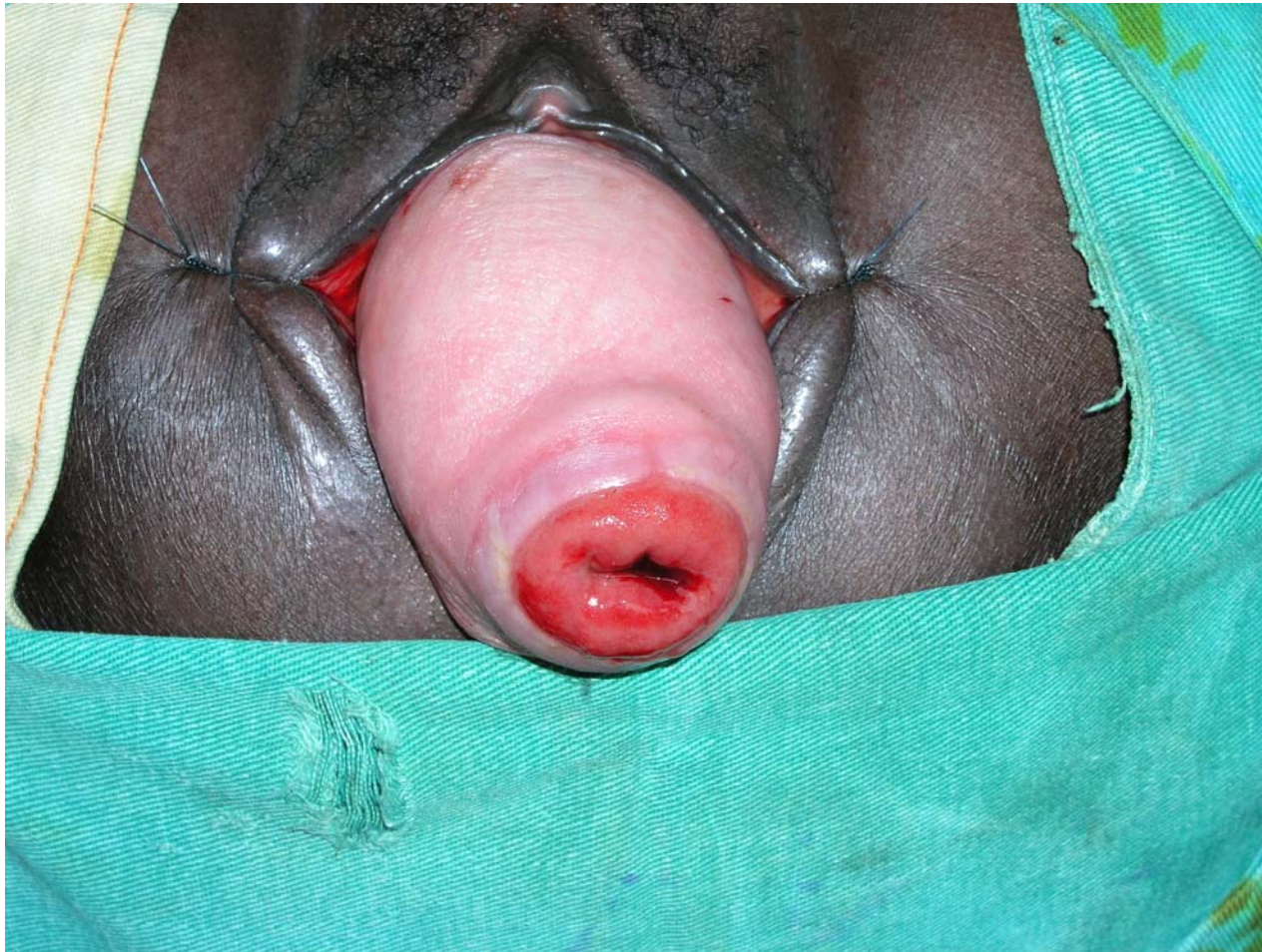
postrepair incontinence



bladder stone



cervix prolapse



classification

closing mechanism

Figure 58 Closing mechanism

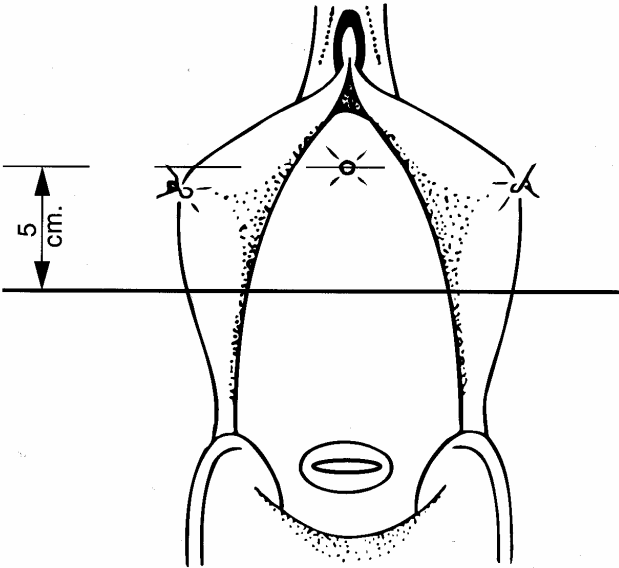


Figure 58-a Closing mechanism: frontal

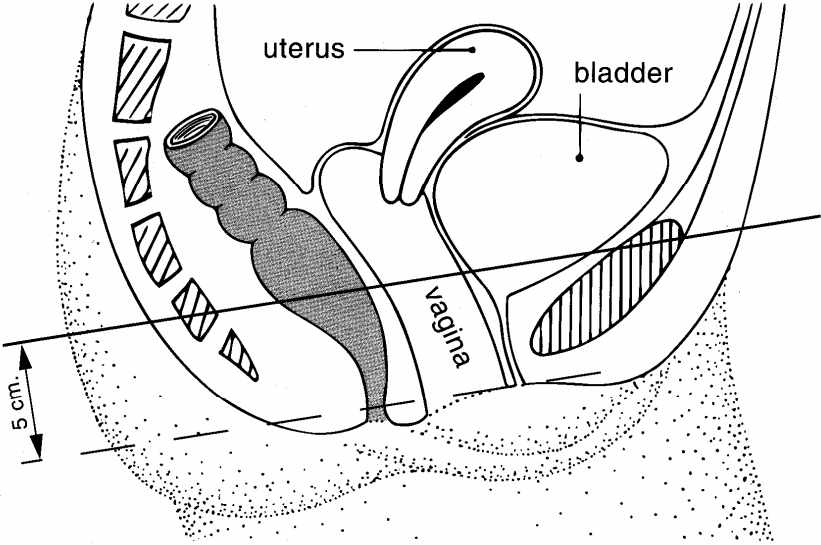


Figure 58-b Closing mechanism: sagittal

classification

according to anatomic/physiologic location

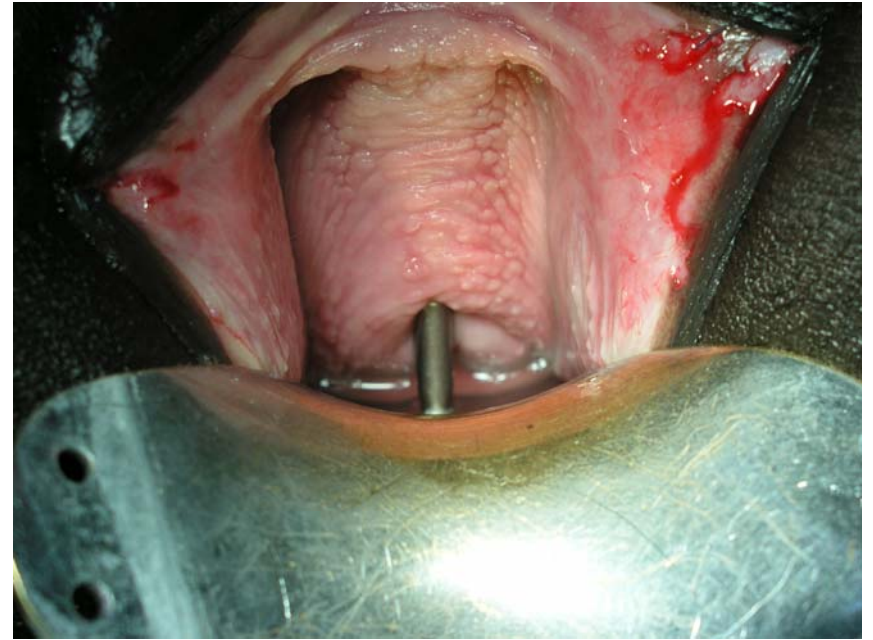
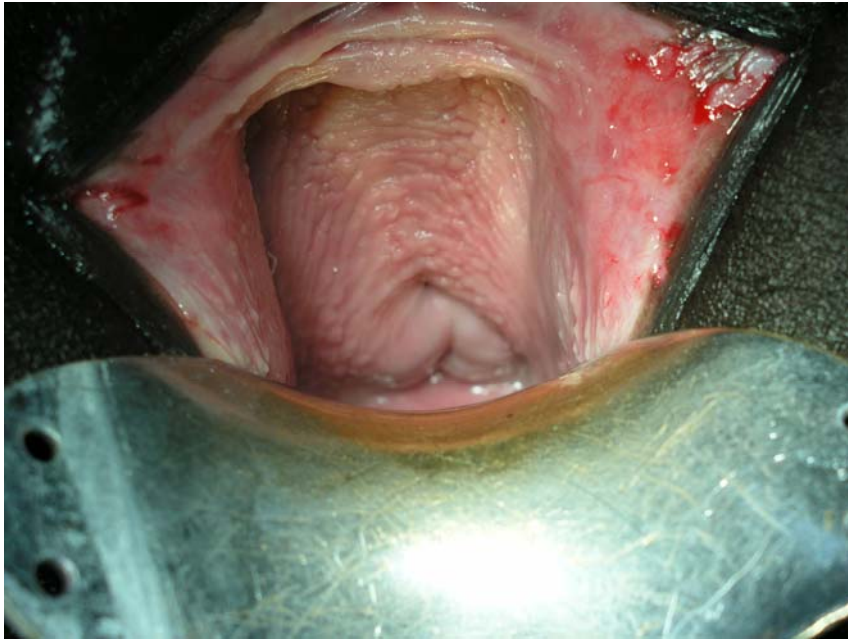- type **I**: not involving closing mechanism
- type **II**: involving closing mechanism
 - **A**: not involving (sub)total urethra
 - **a**: without circumferential defect
 - **b**: with circumferential defect
 - **B**: involving (sub)total urethra
 - **a**: without circumferential defect
 - **b**: with circumferential defect
- type **III**: miscellaneous, e.g. ureter fistula

classification

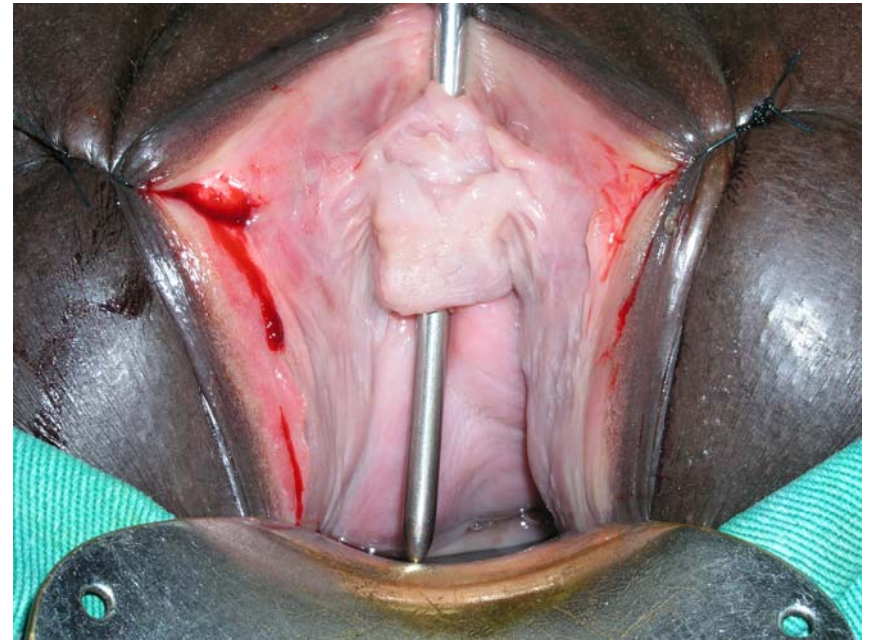
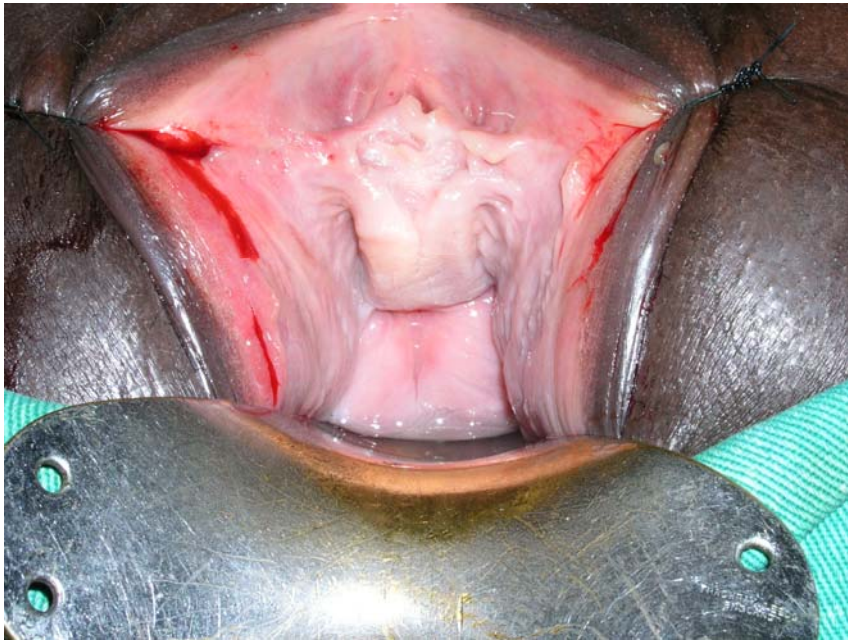
according to size

- **small** < 2 cm
- **medium** 2-3 cm
- **large** 4-5 cm
- **extensive** \geq 6 cm

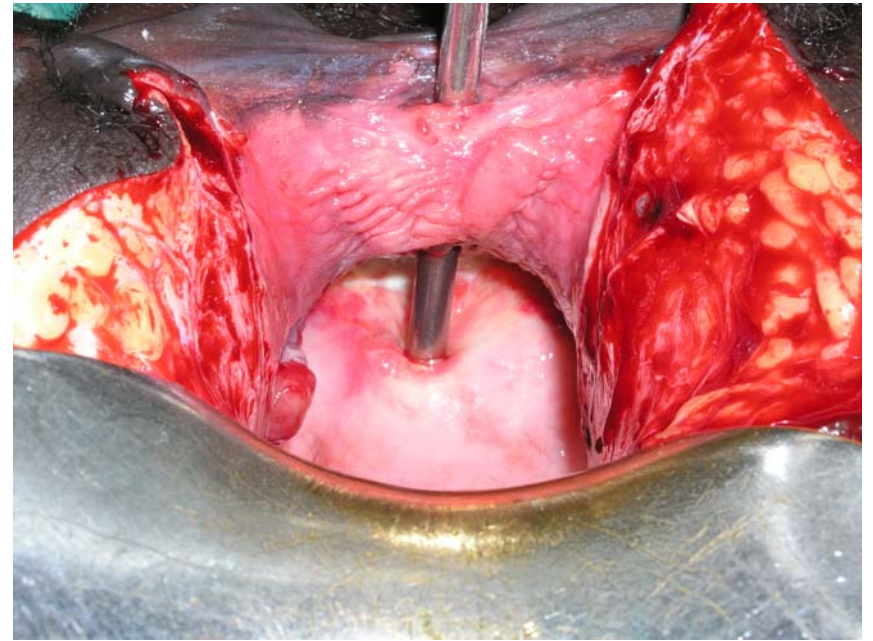
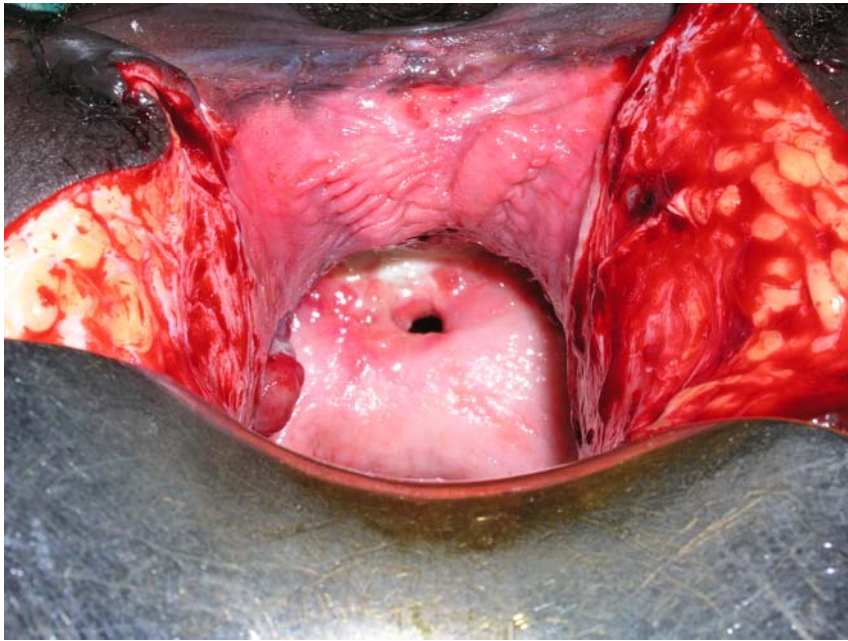
type I fistula



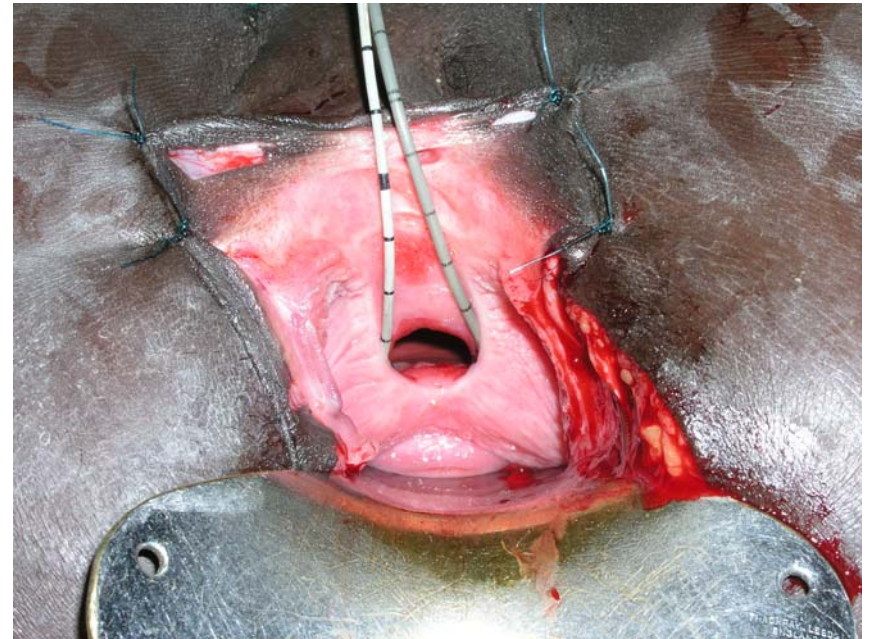
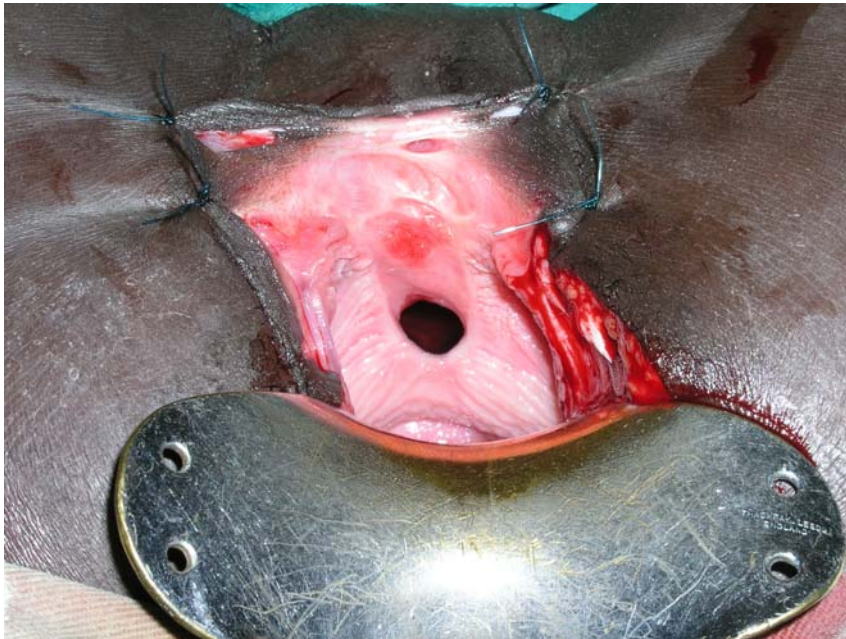type IIAa fistula



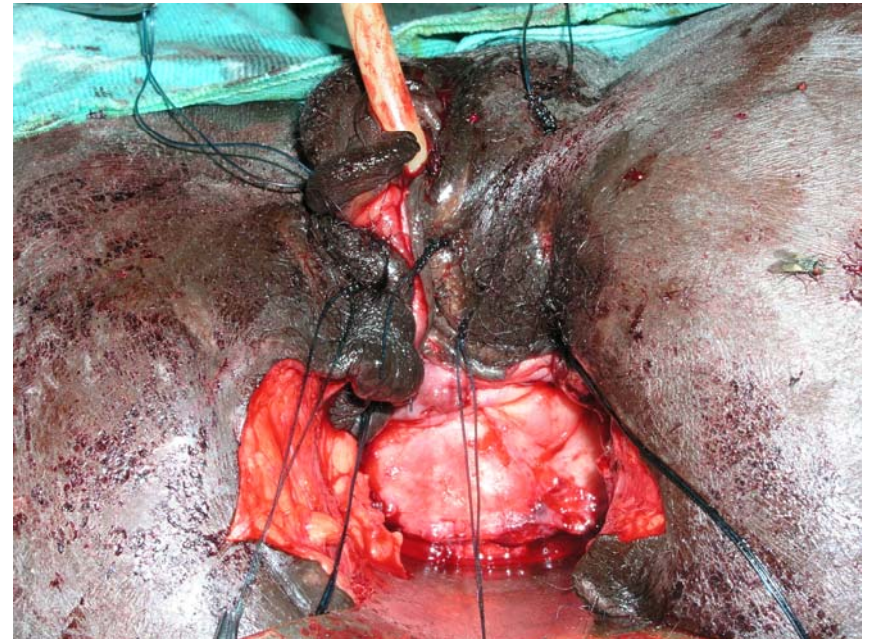
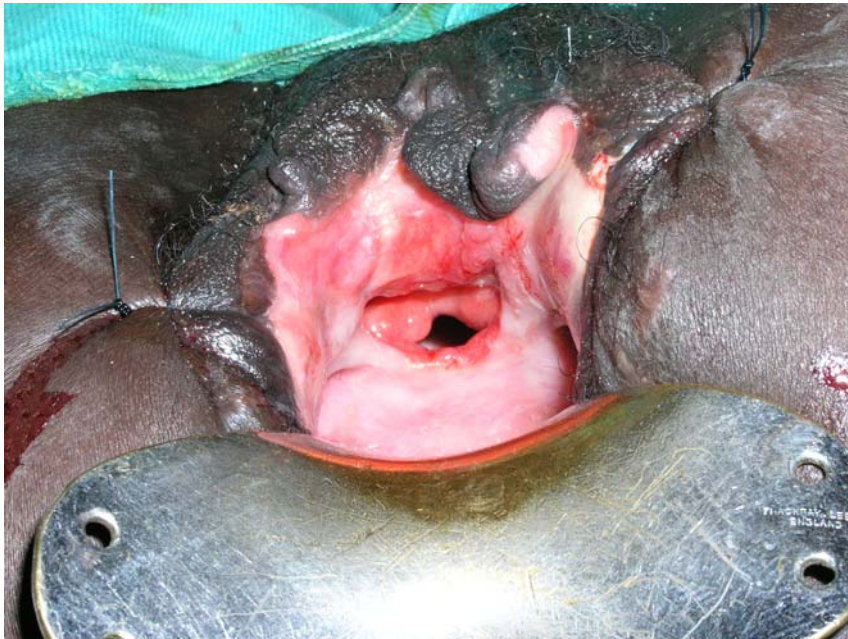type IIAb fistula



type II Ba fistula

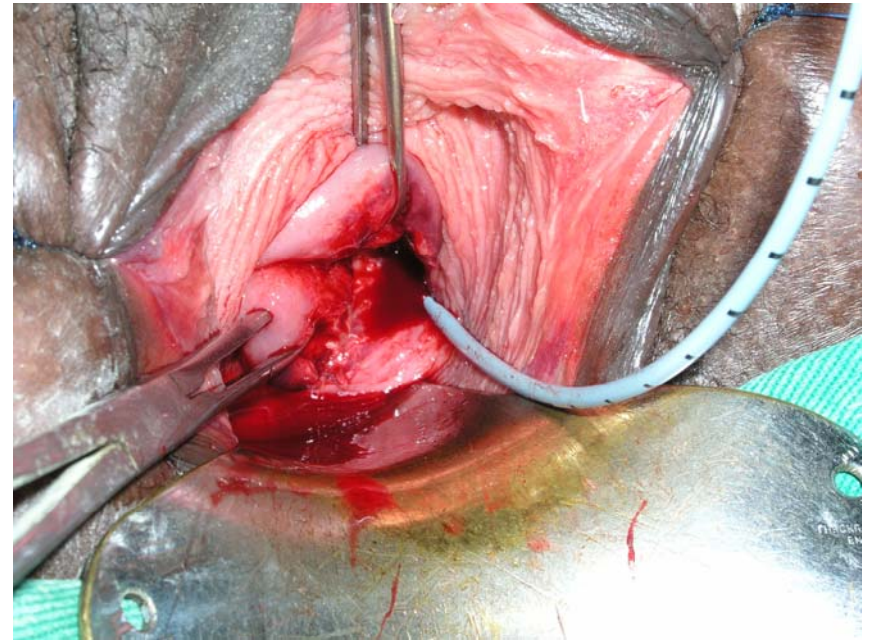
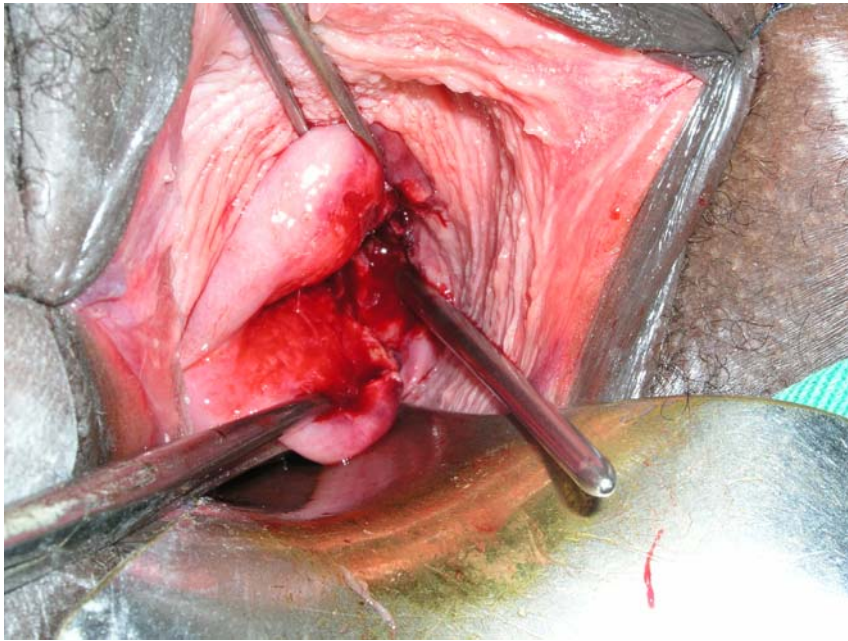


type IIBb fistula

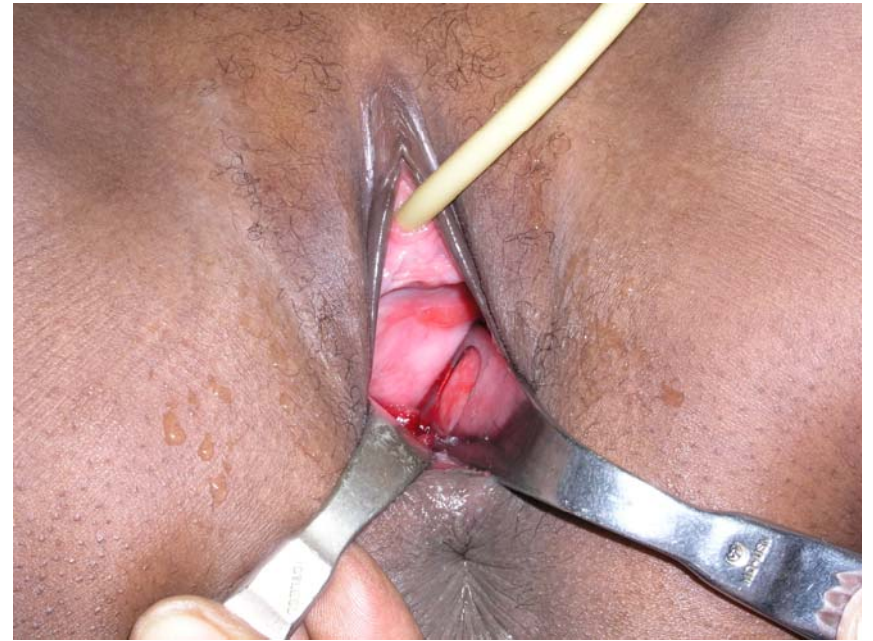
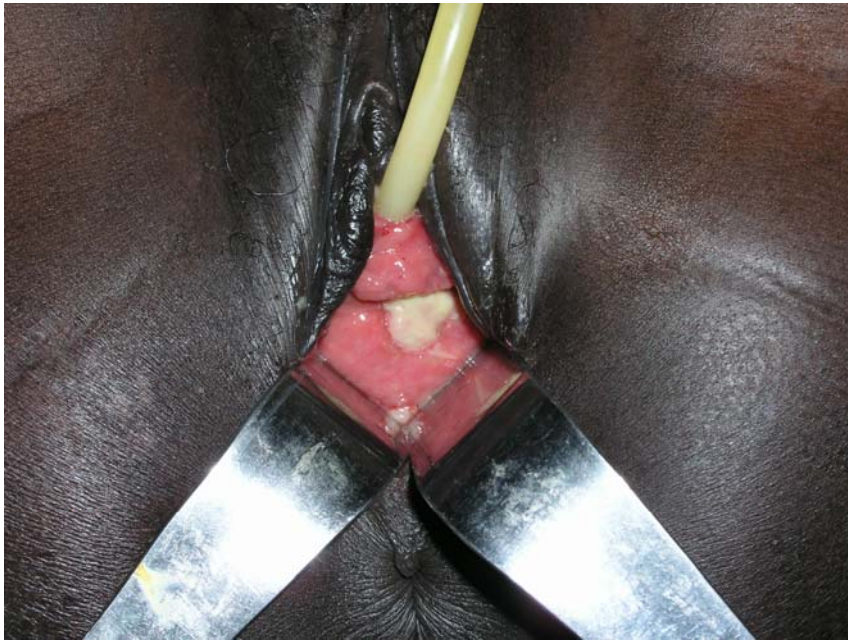
type III fistula

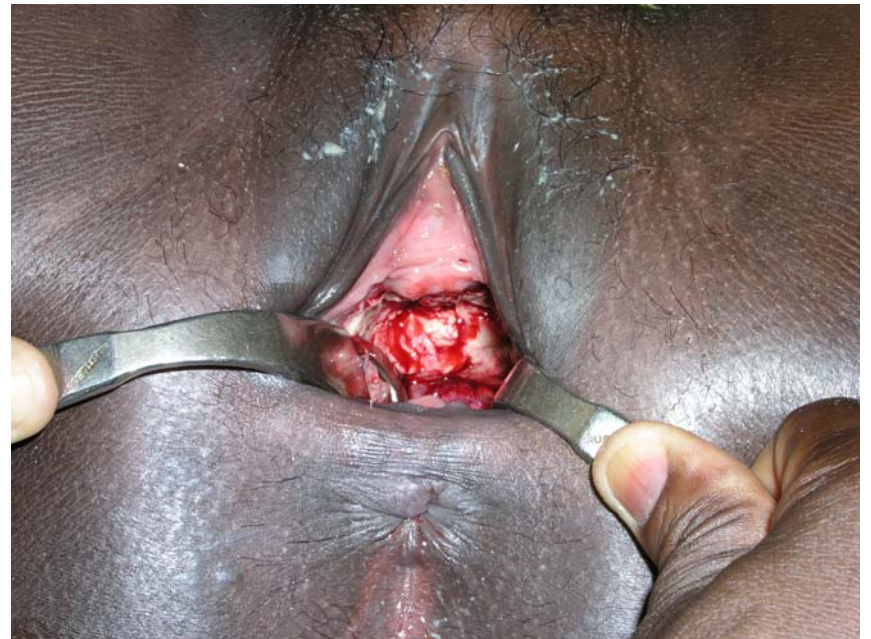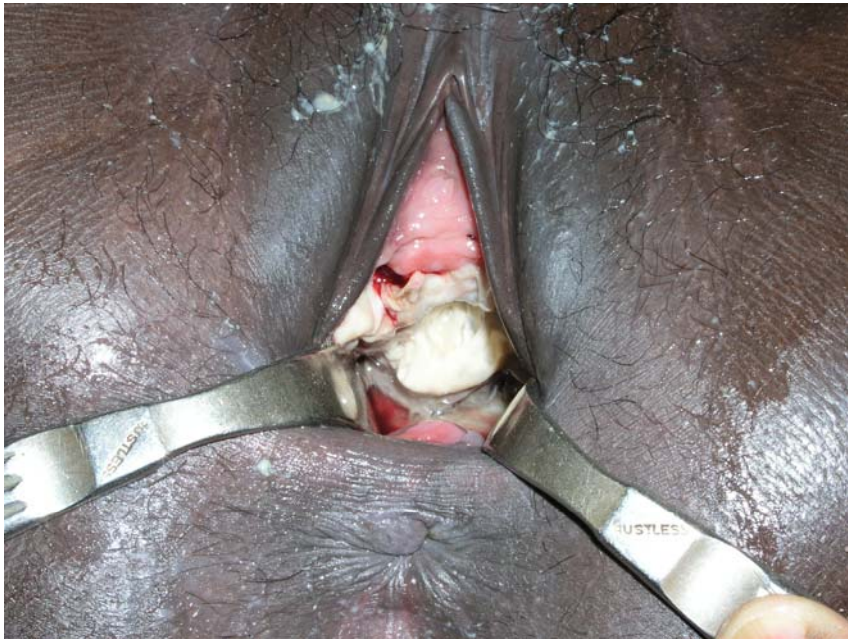ureter fistula



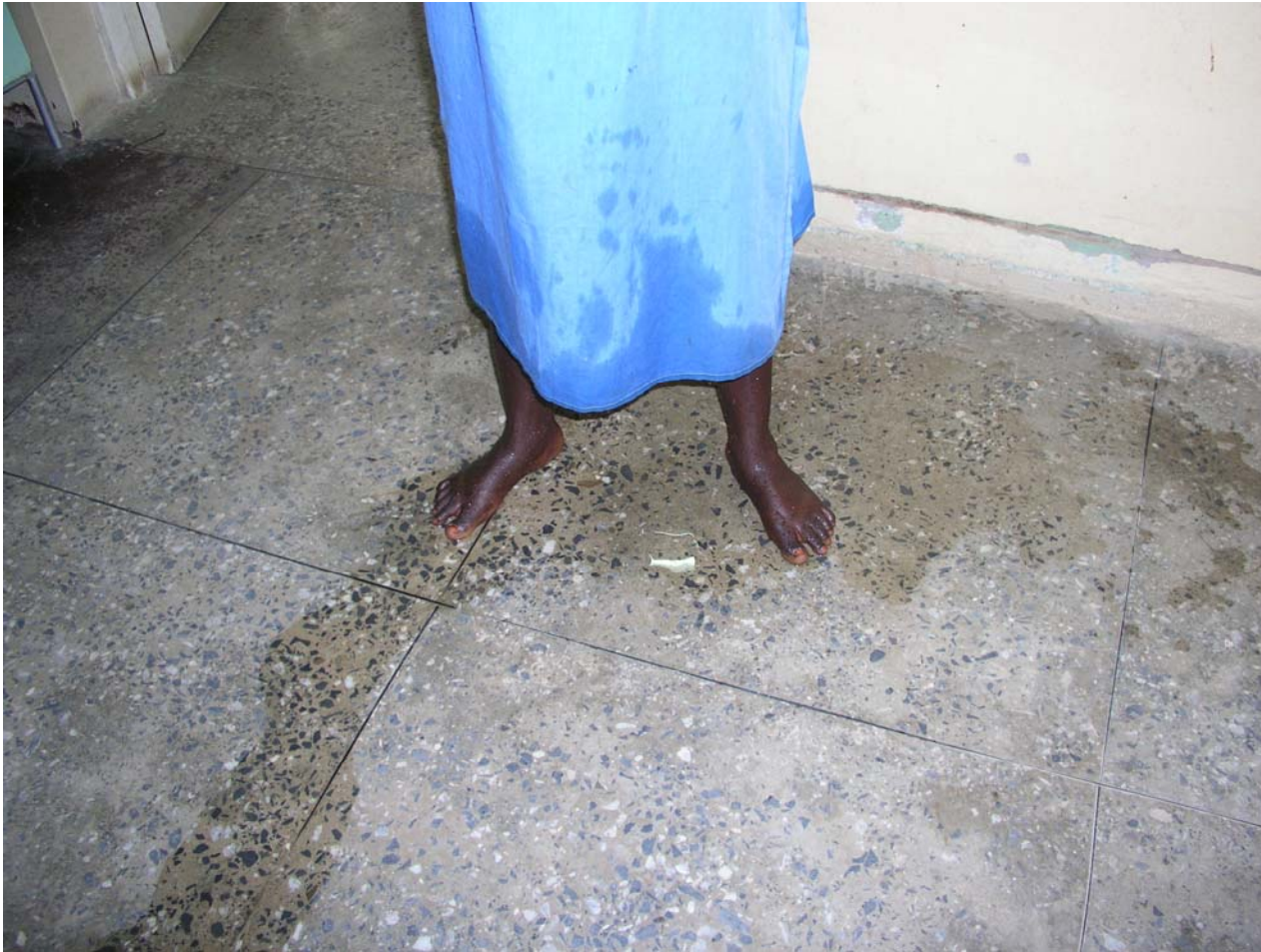catheter treatment



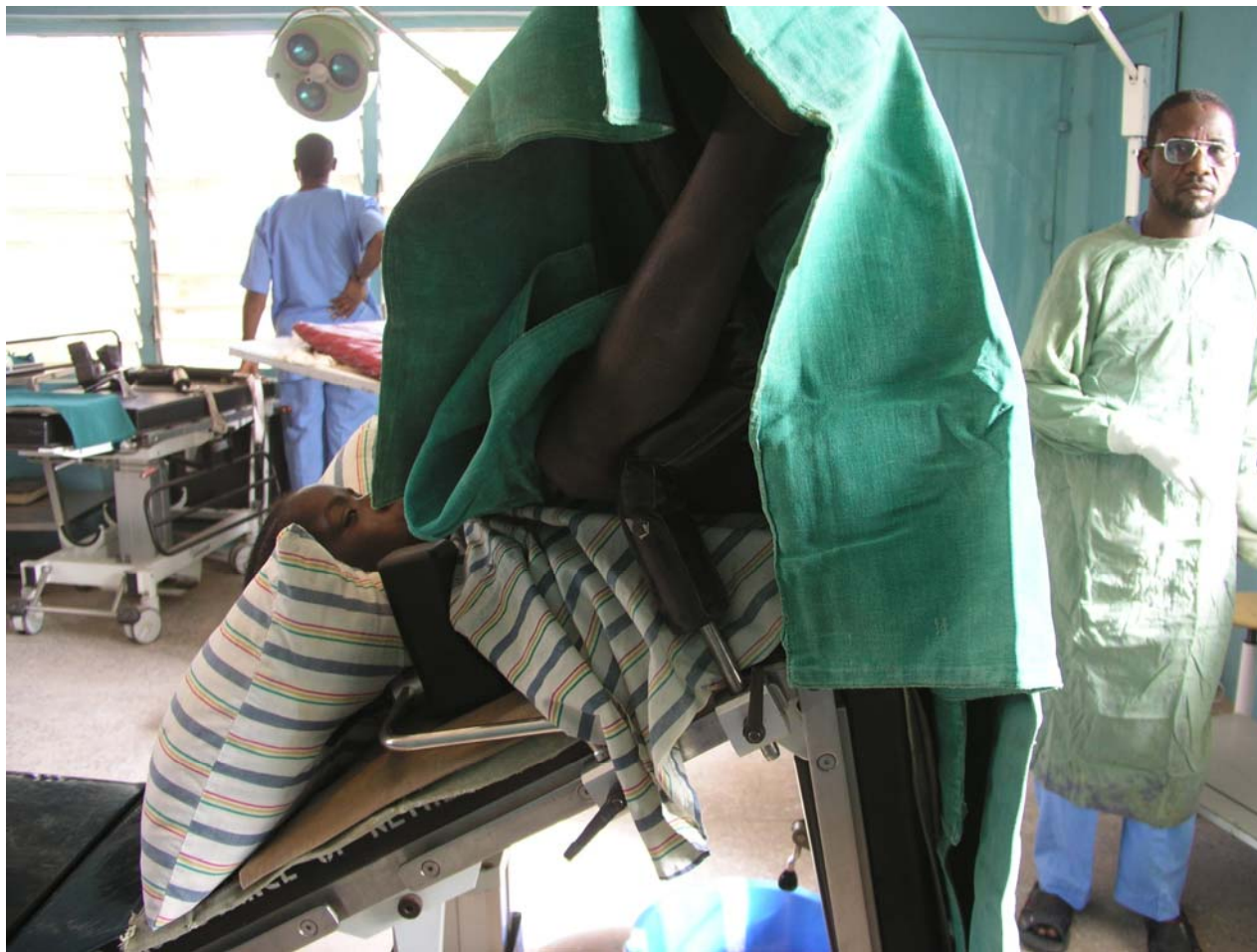slough excision



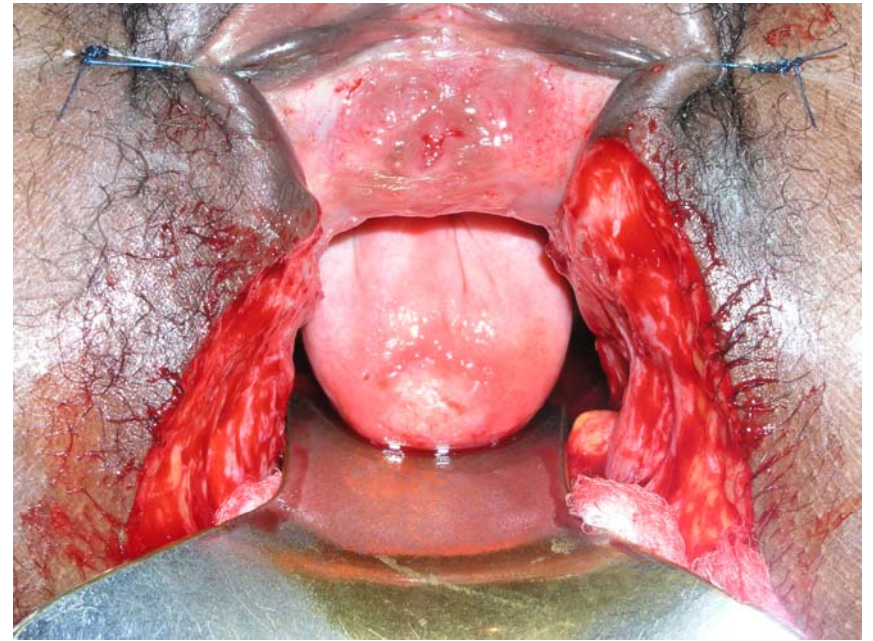
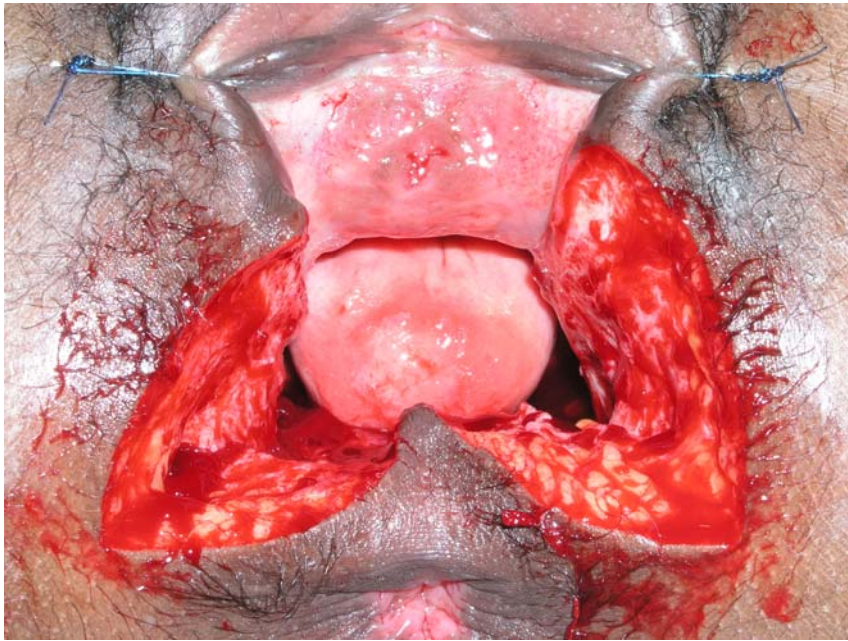
high oral fluid intake urine output



position on operating table

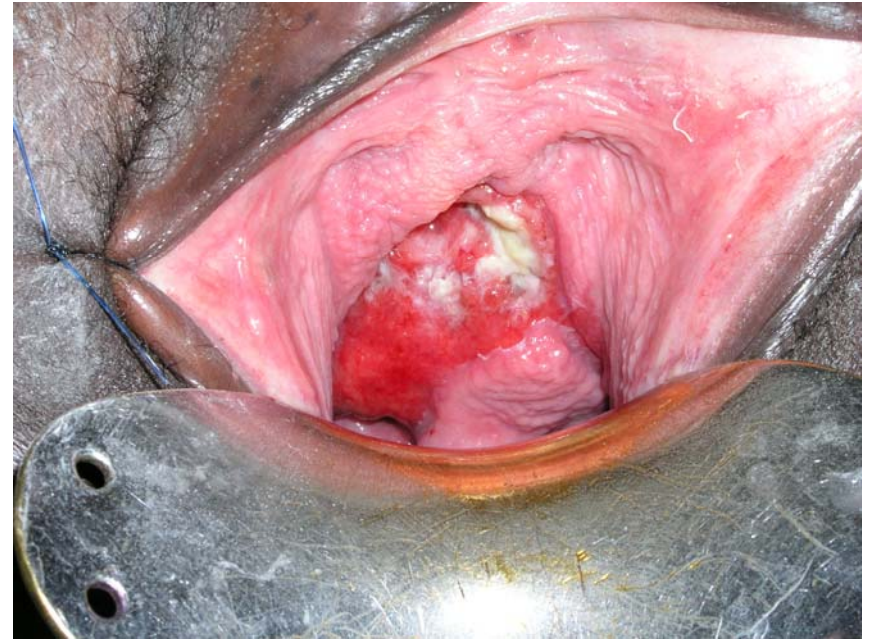
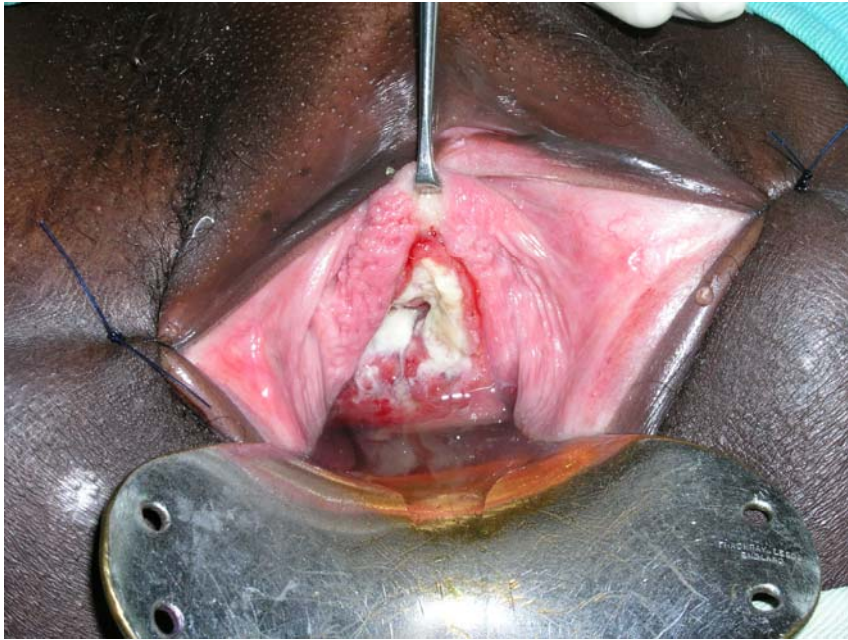

good access



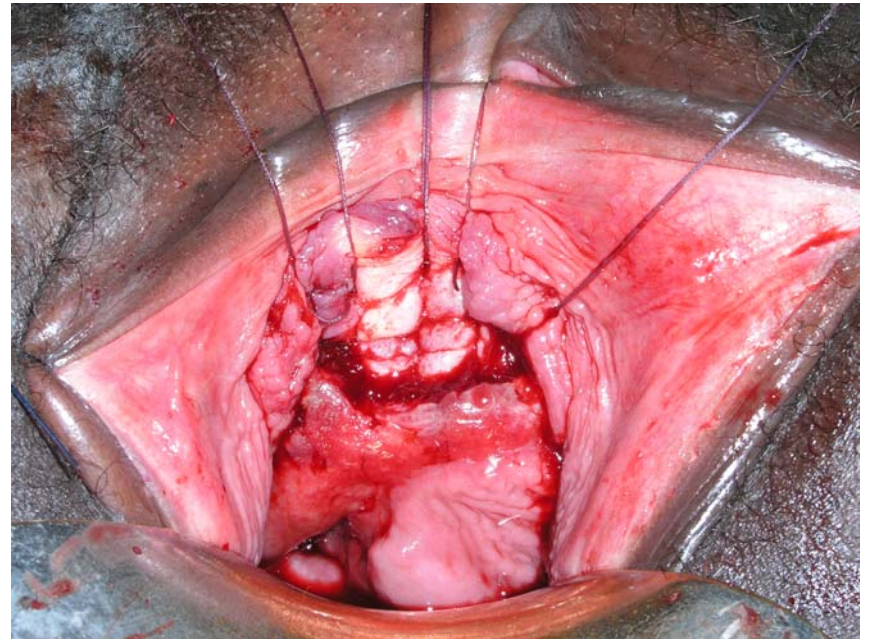
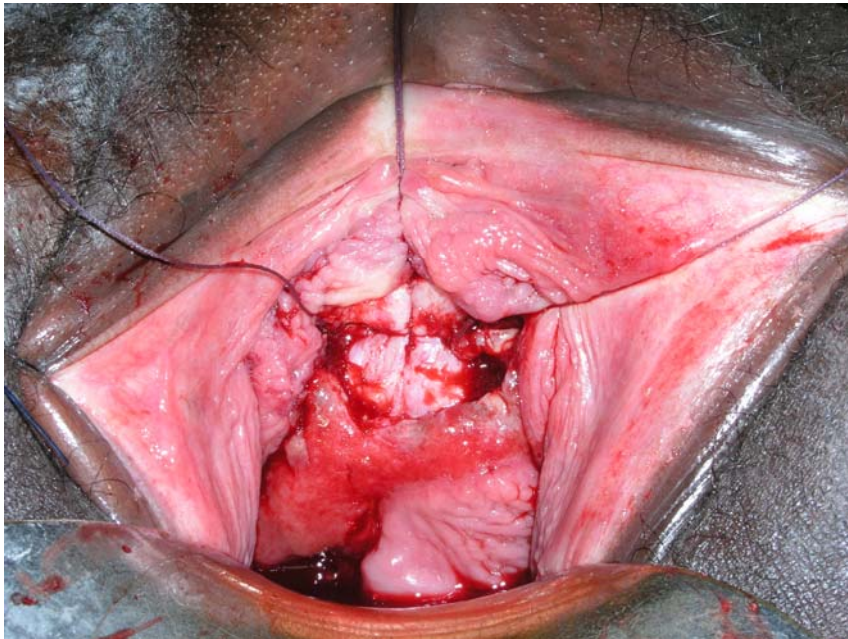
early closure

transverse



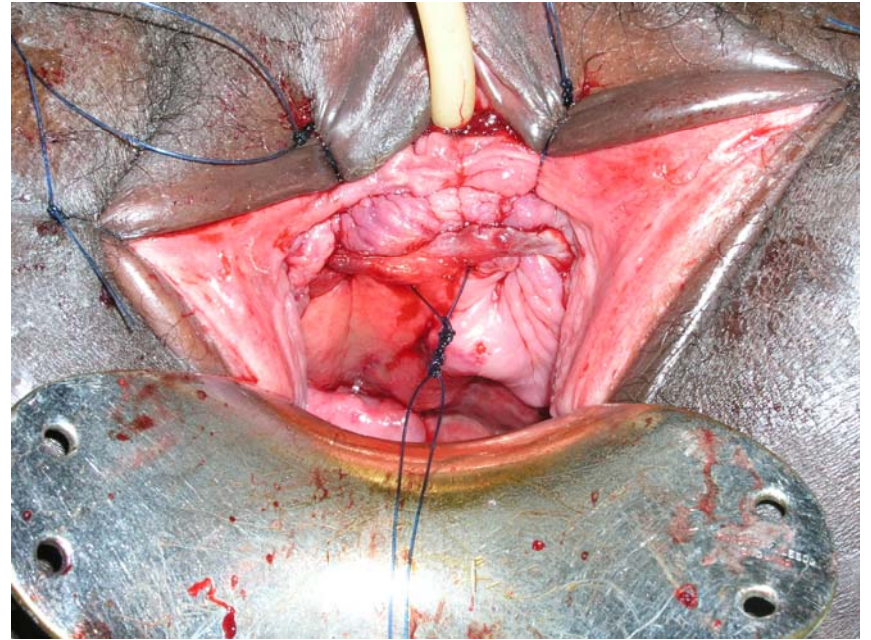
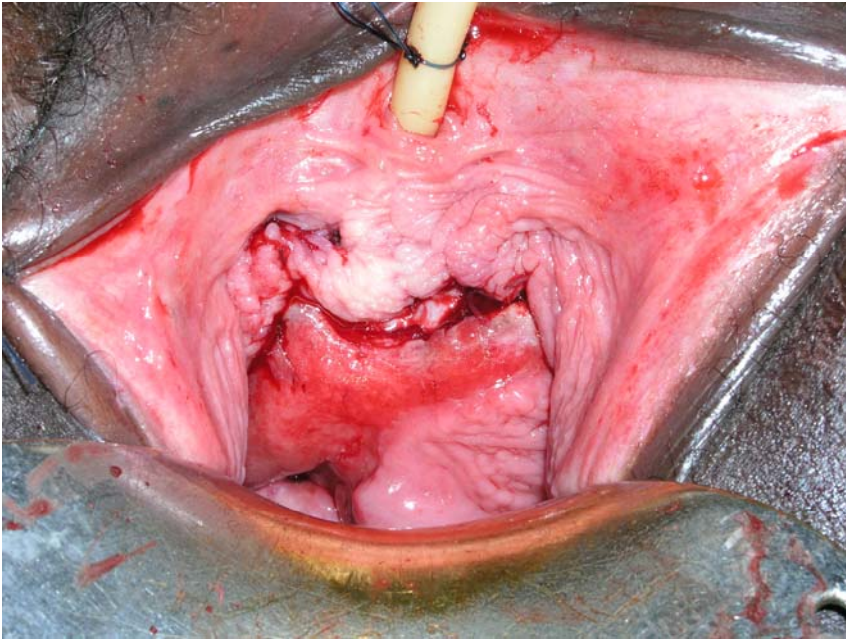
early closure

transverse

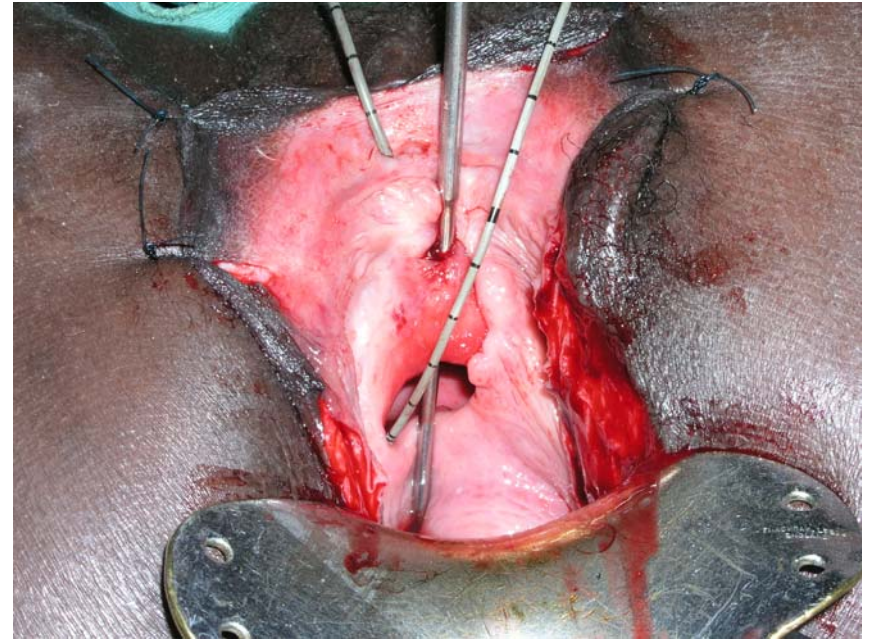
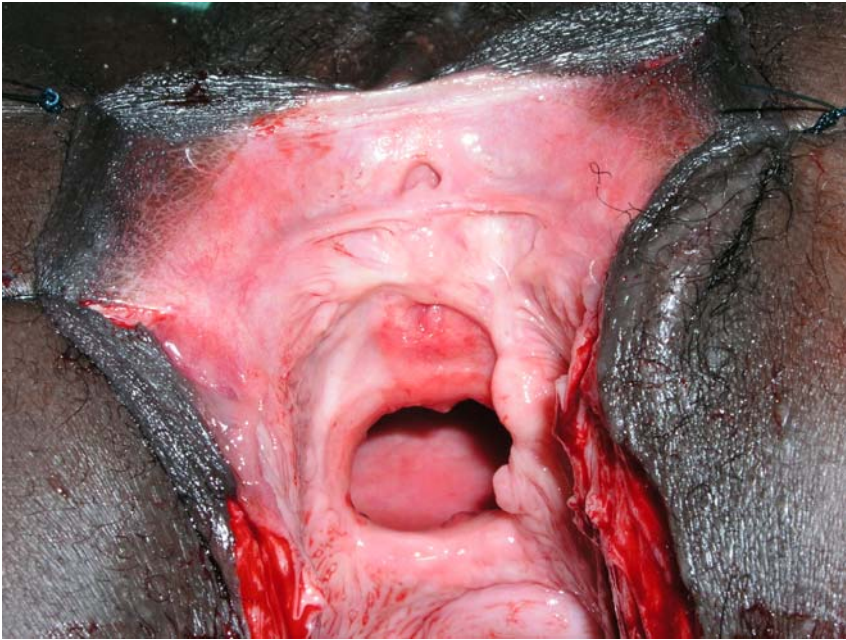

early closure

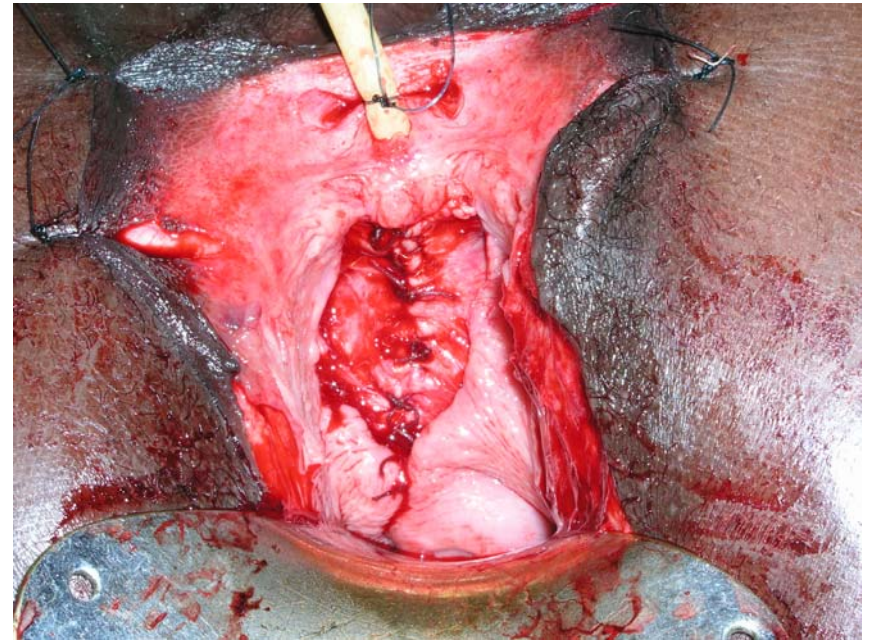
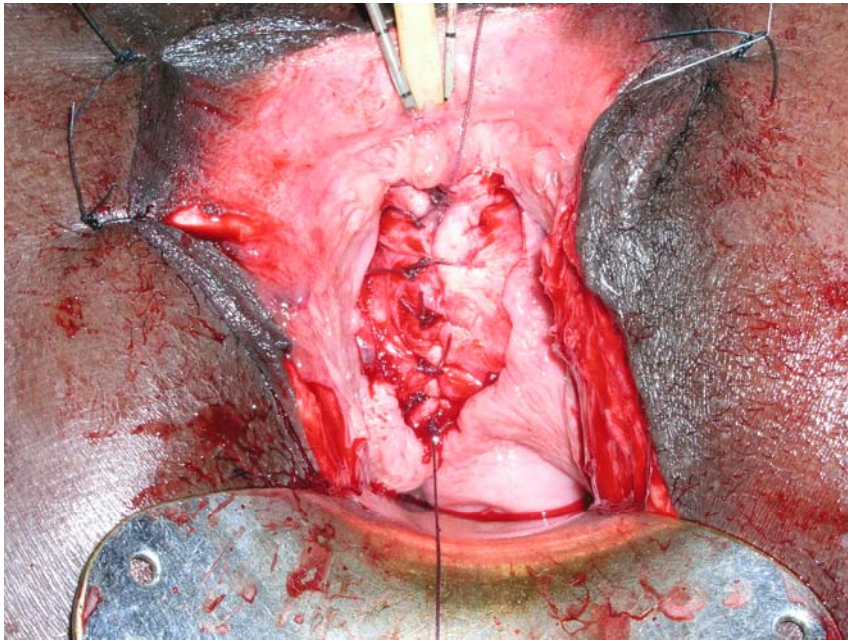
transverse



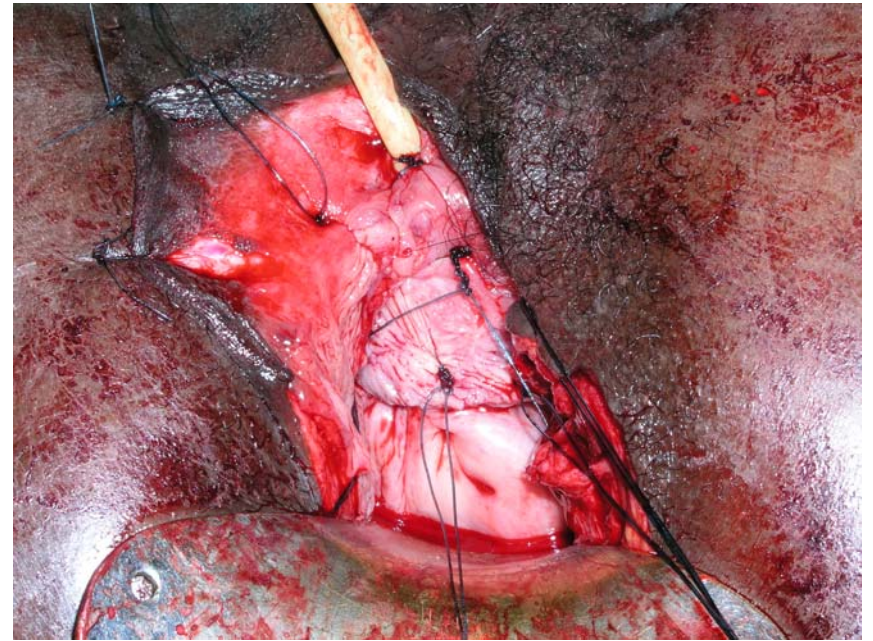
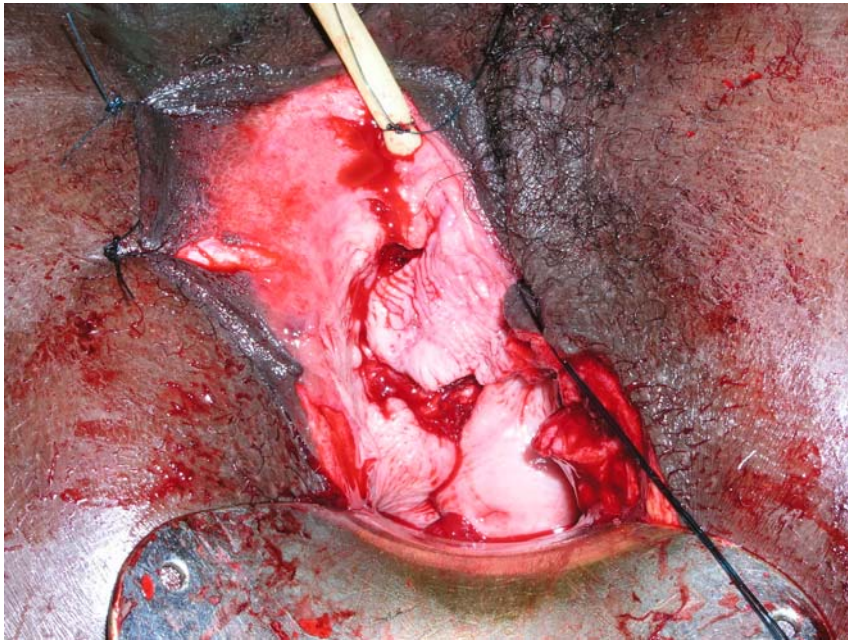
longitudinal closure



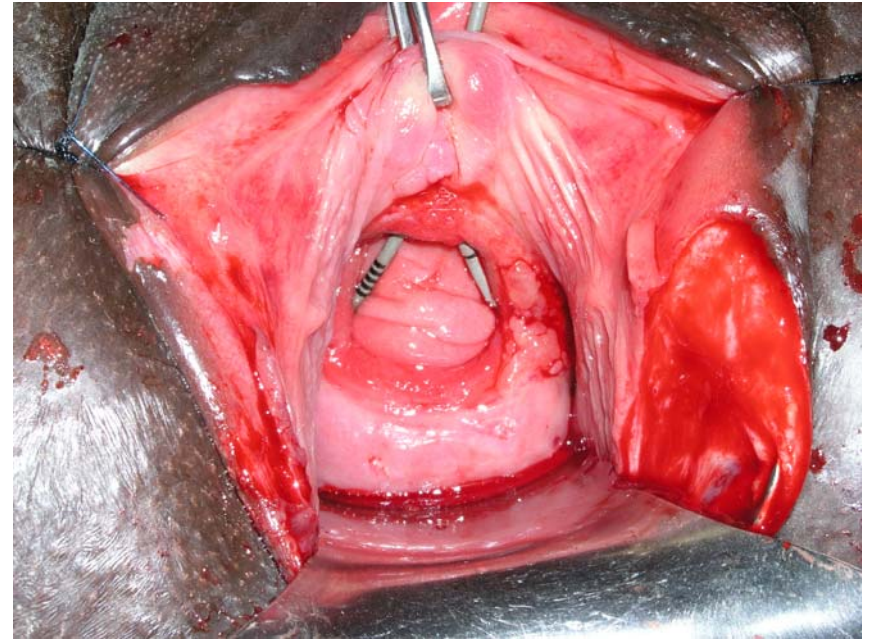
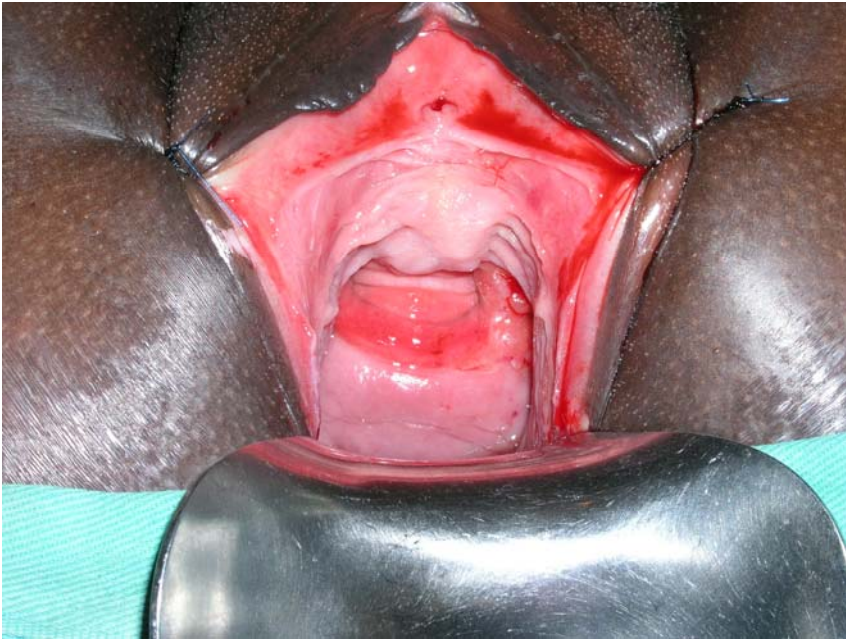
longitudinal closure



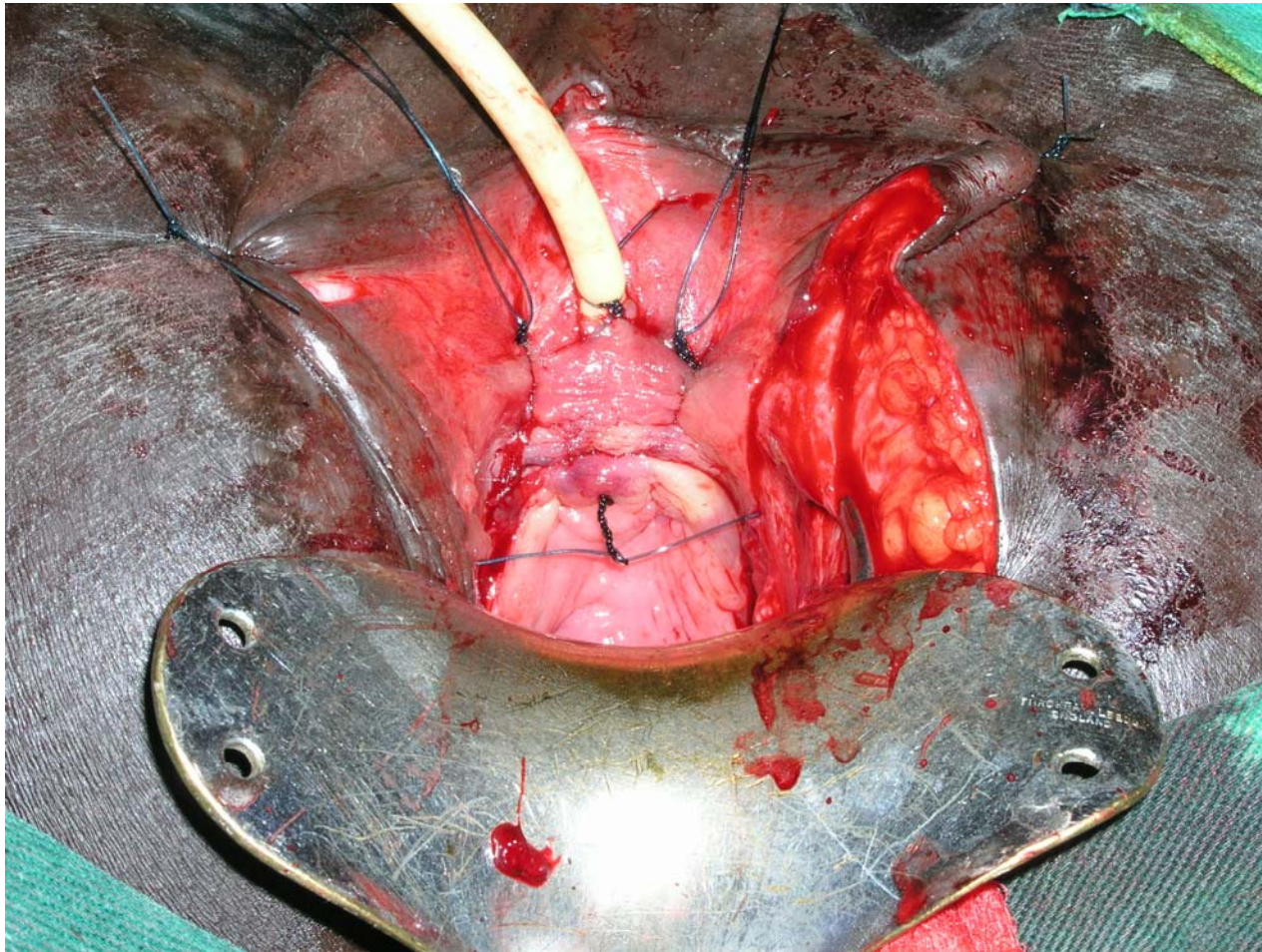
longitudinal closure



ureter catheterization

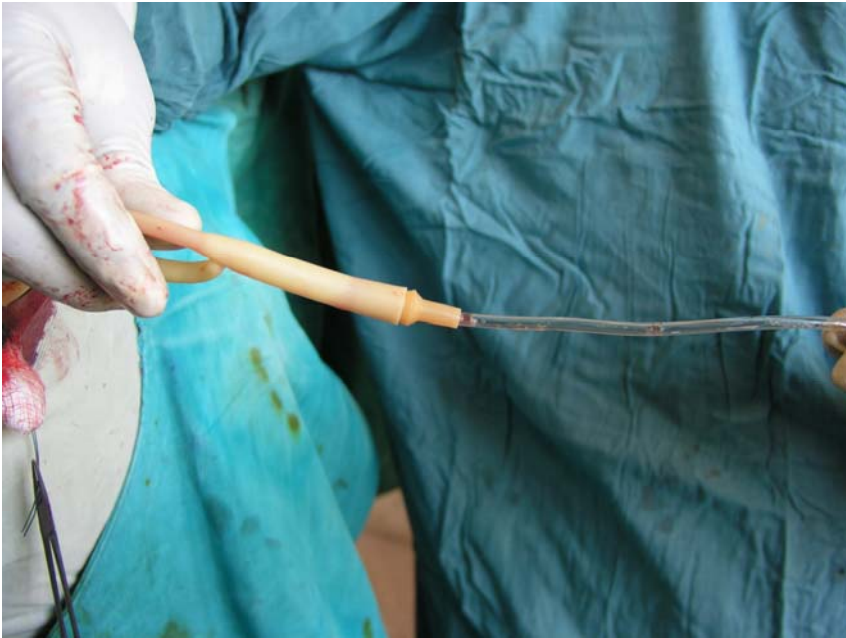

vagina wall adaptation

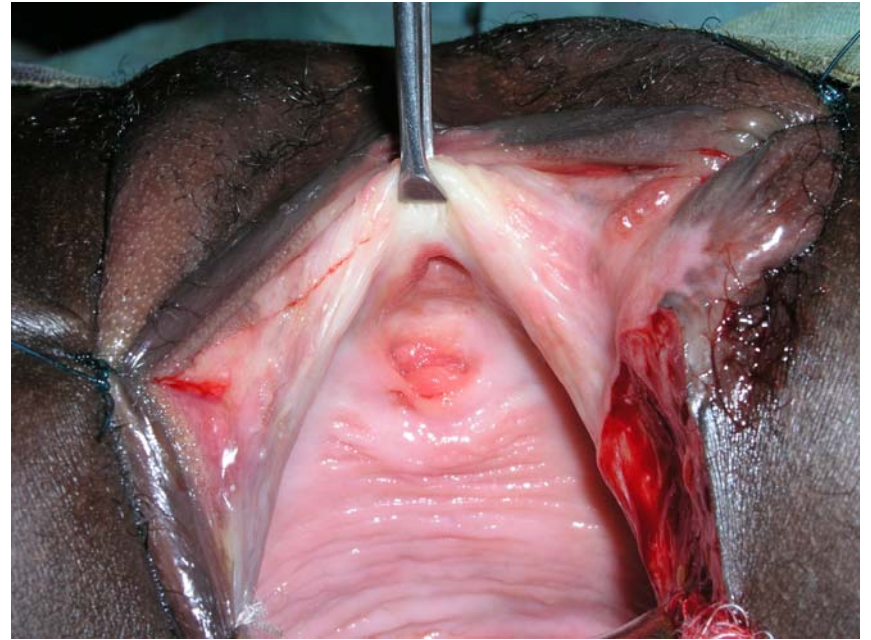
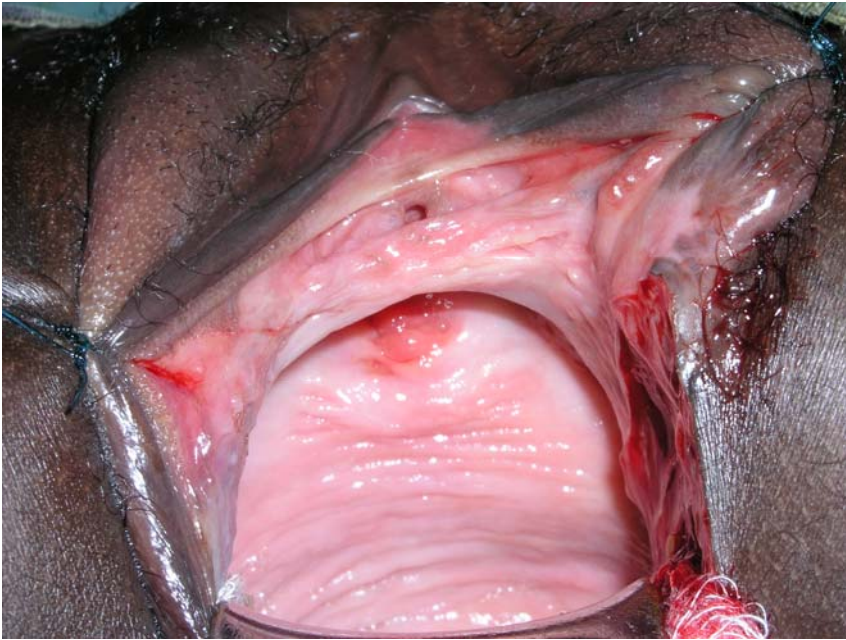


connection catheter_infusion set

for open drainage

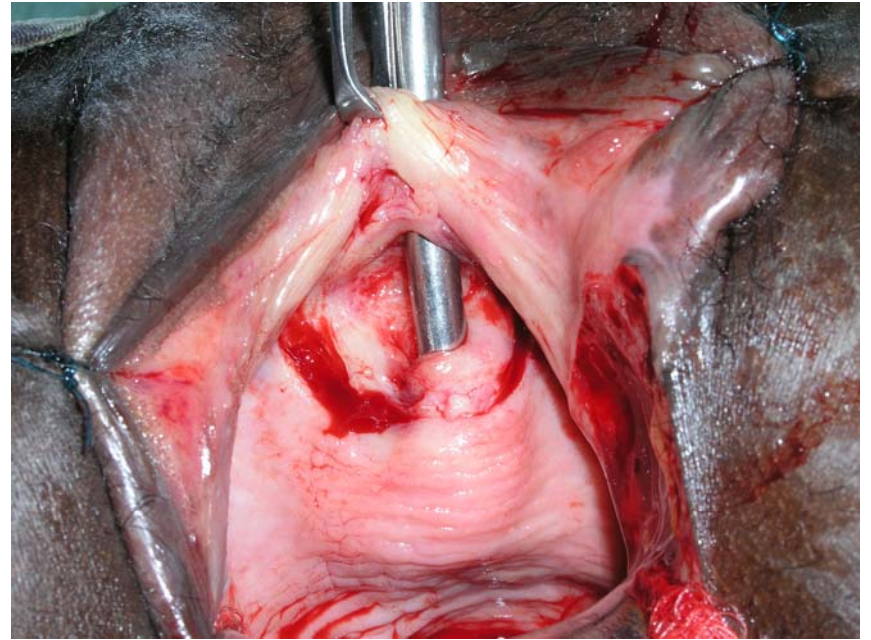
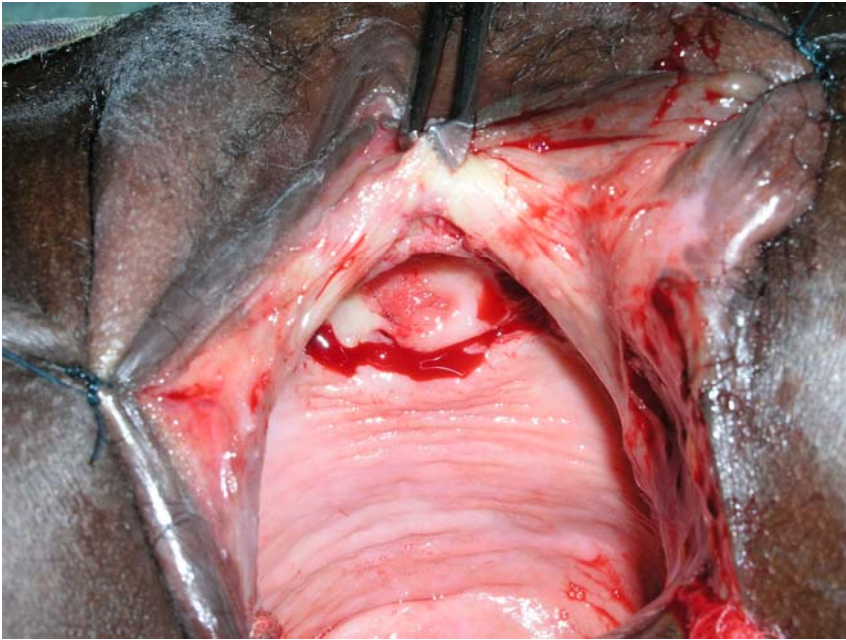


minimum surgery



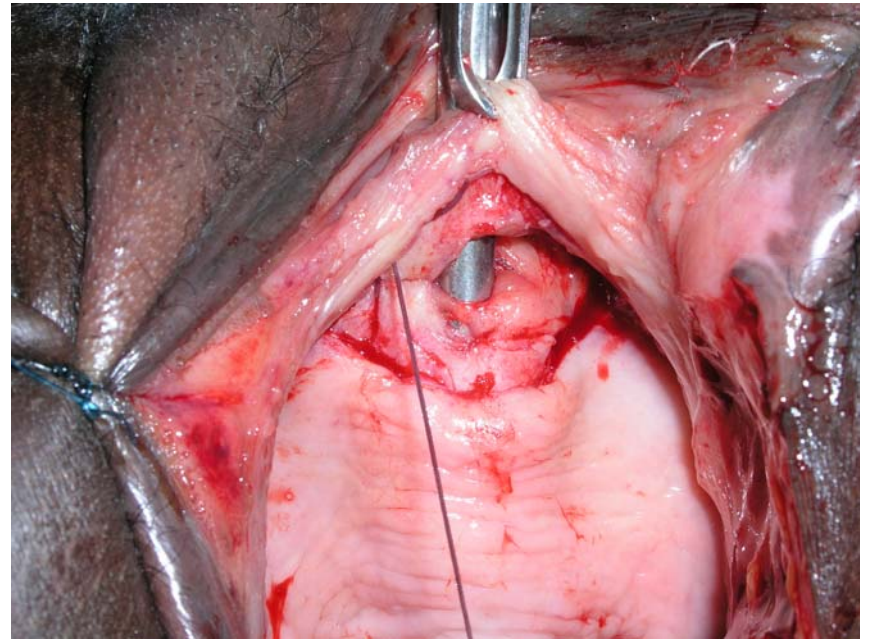
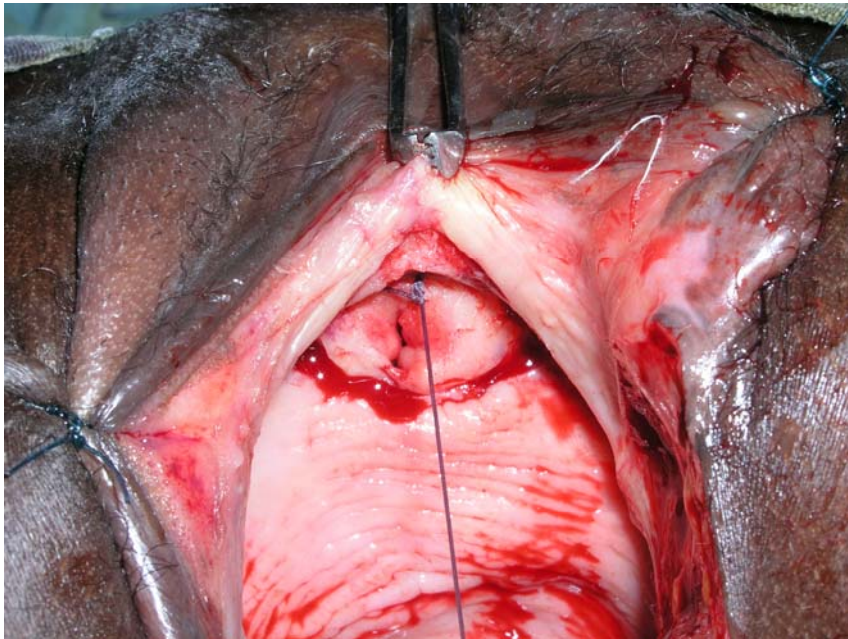
minimum surgery

incision and minimum dissection



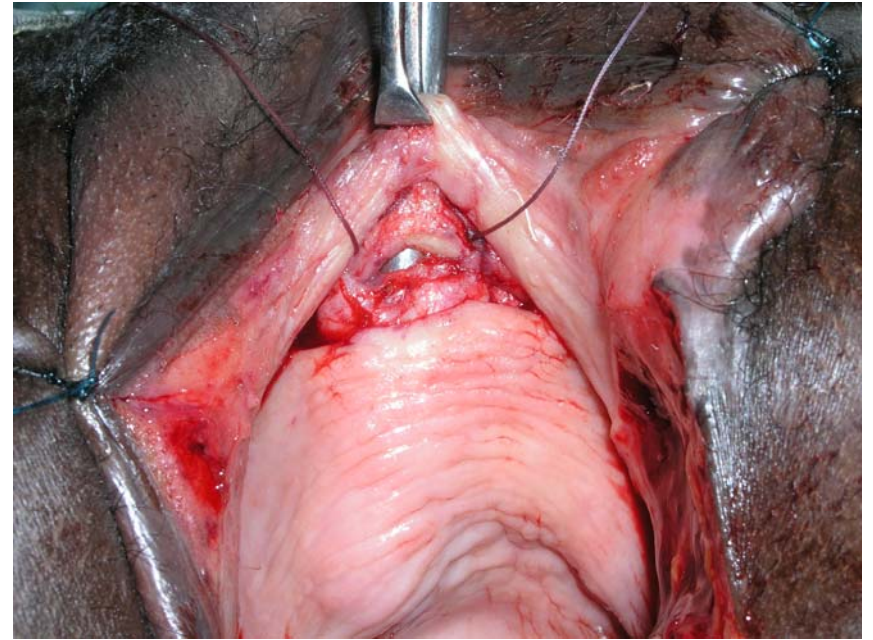
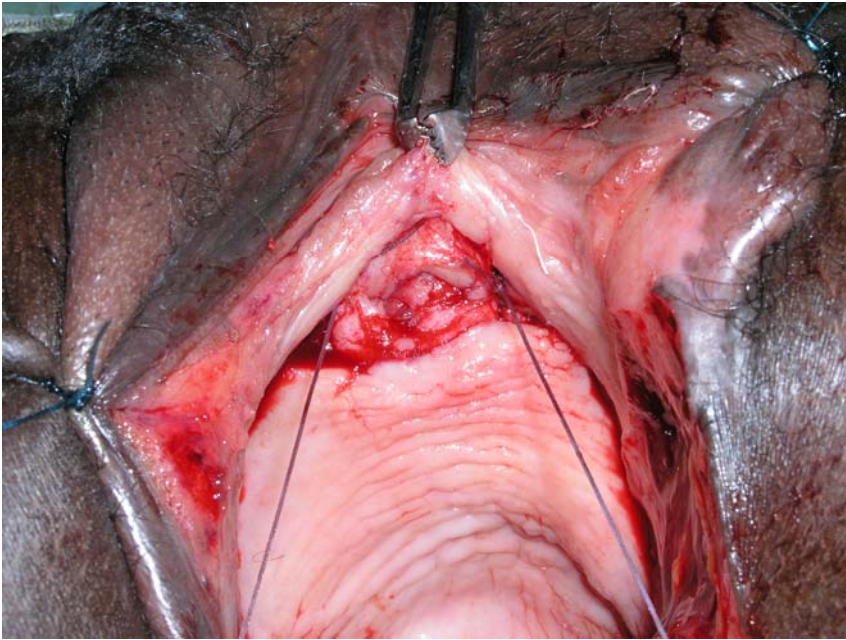
minimum surgery

circumferential closure



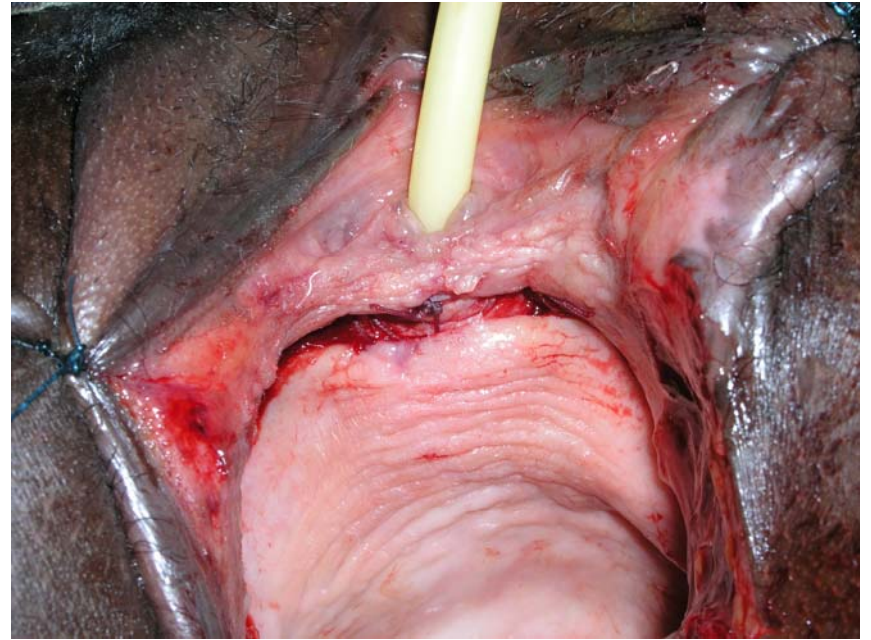
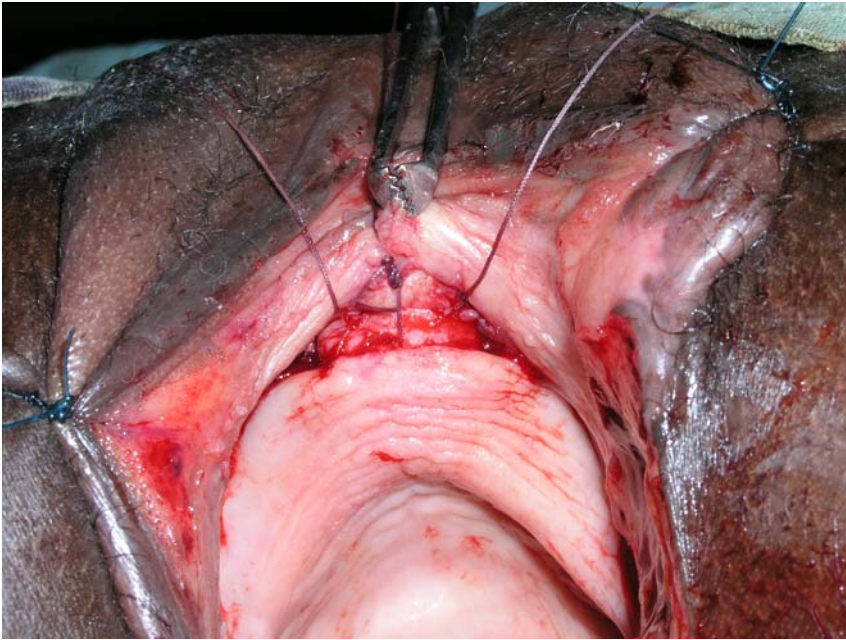
minimum surgery

circumferential closure



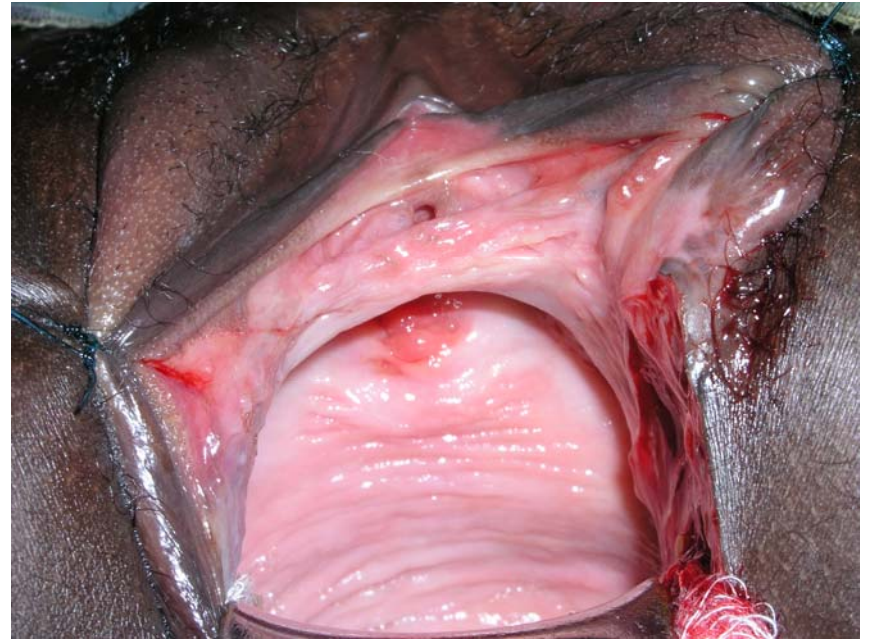
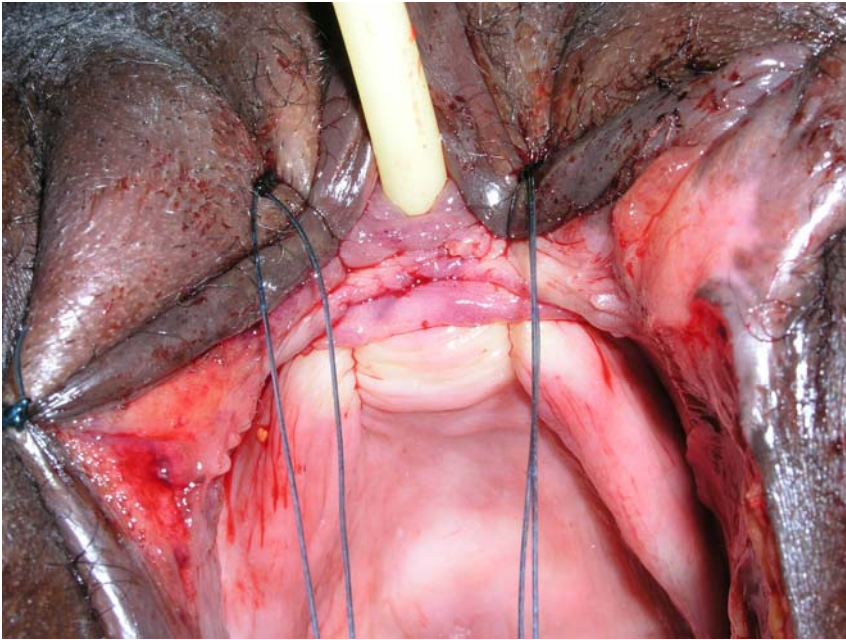
minimum surgery

end-to-end vesicourethrostomy

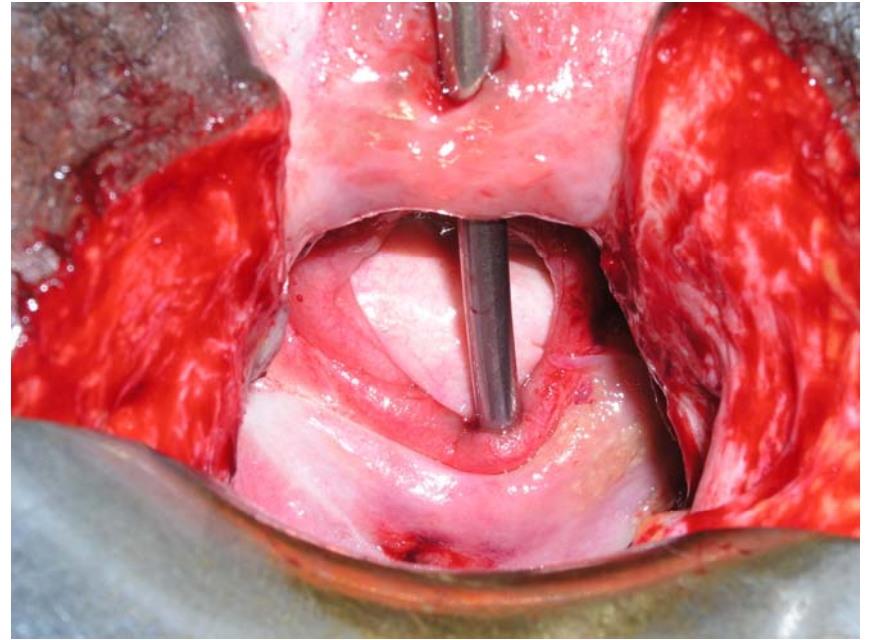
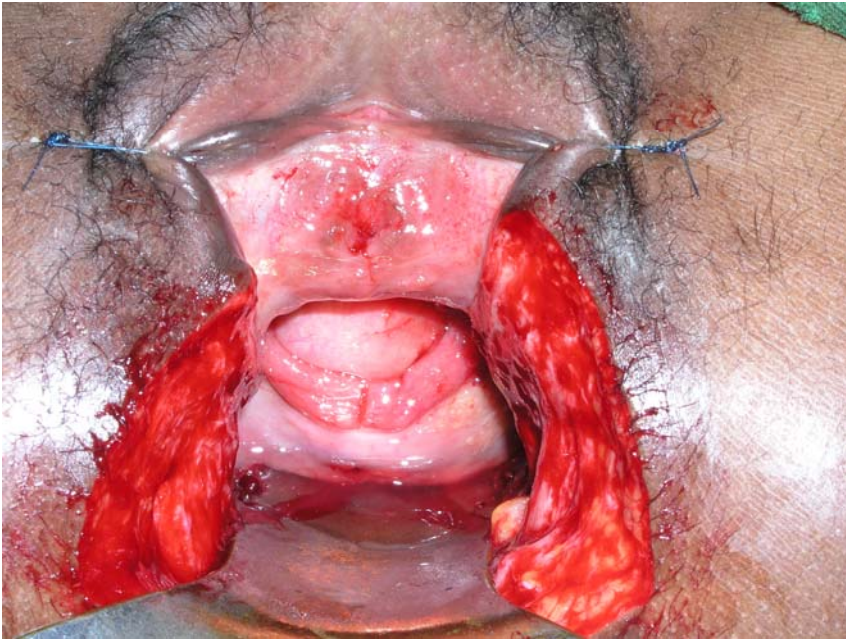


minimum surgery

anterior vagina wall adaptation

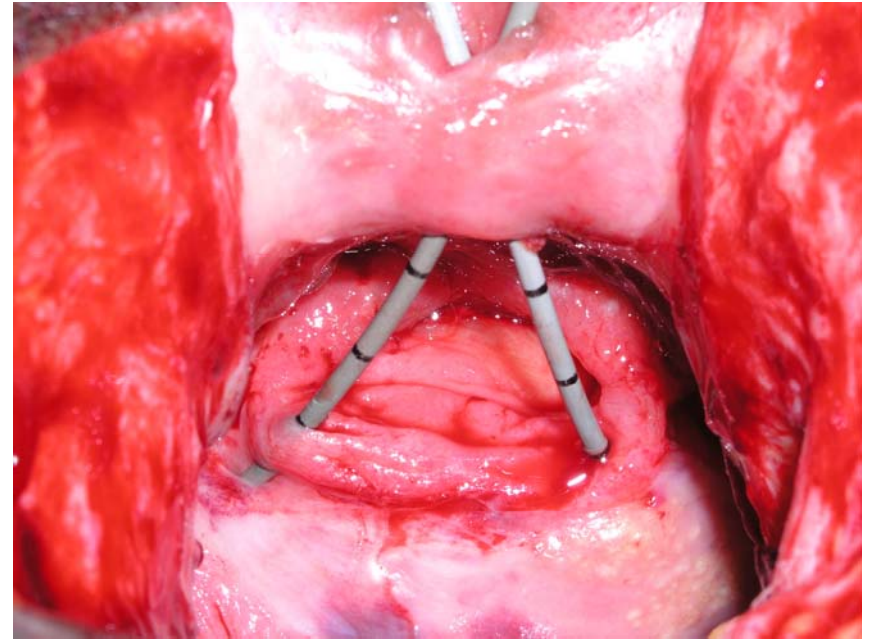
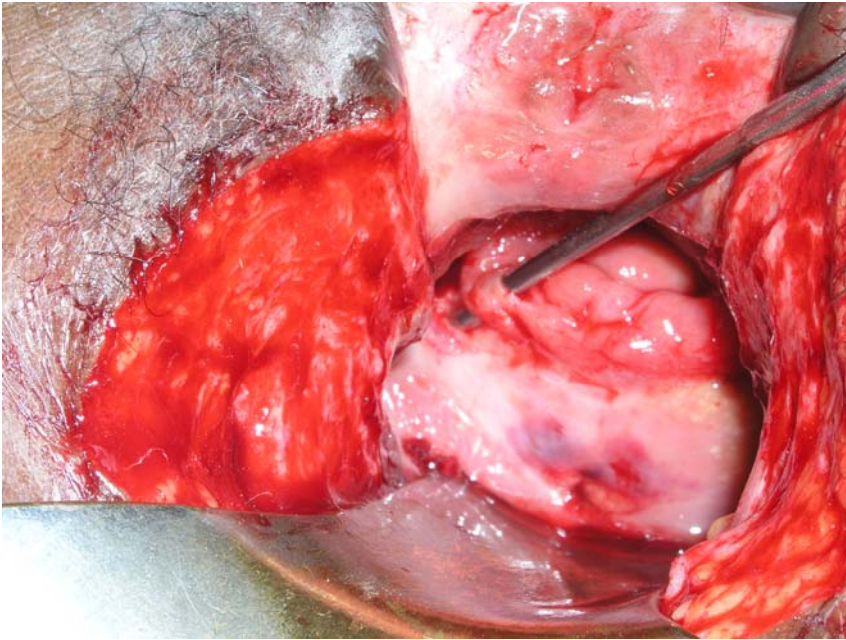


extensive fistula repair



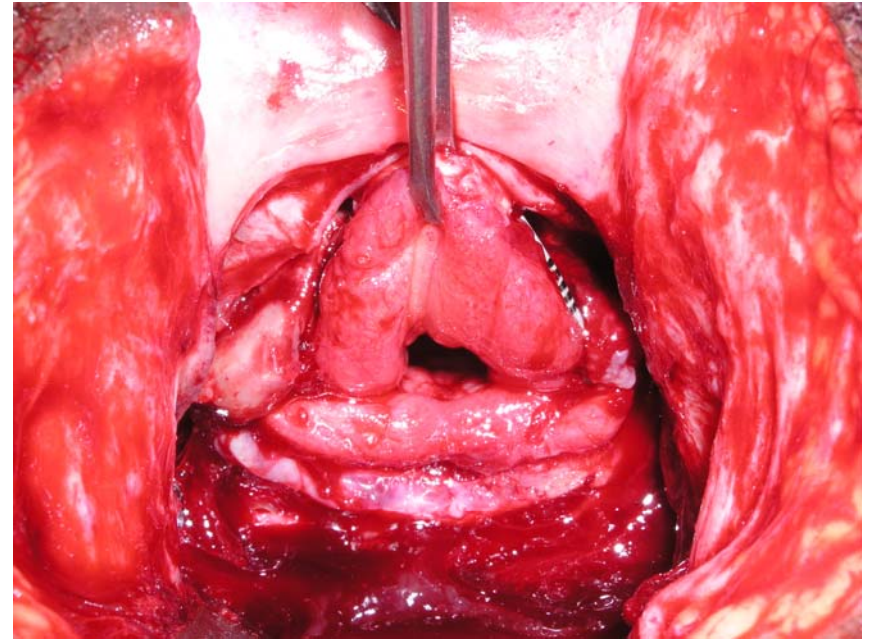
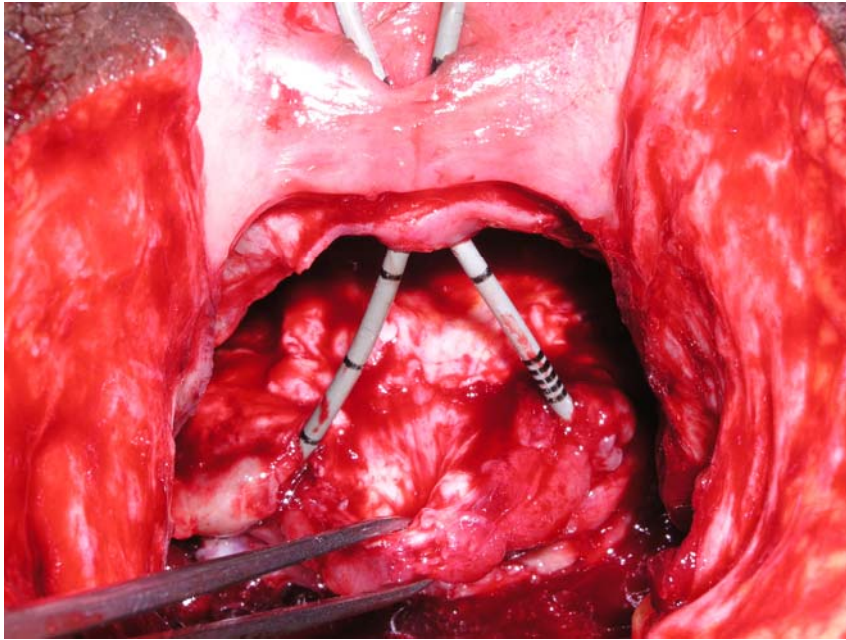
extensive fistula repair

ureter catheterization



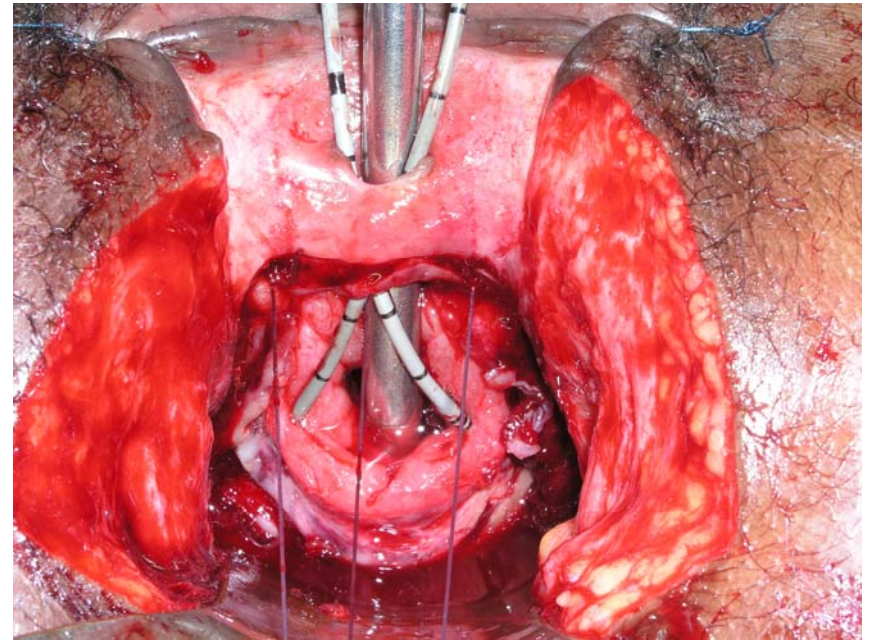
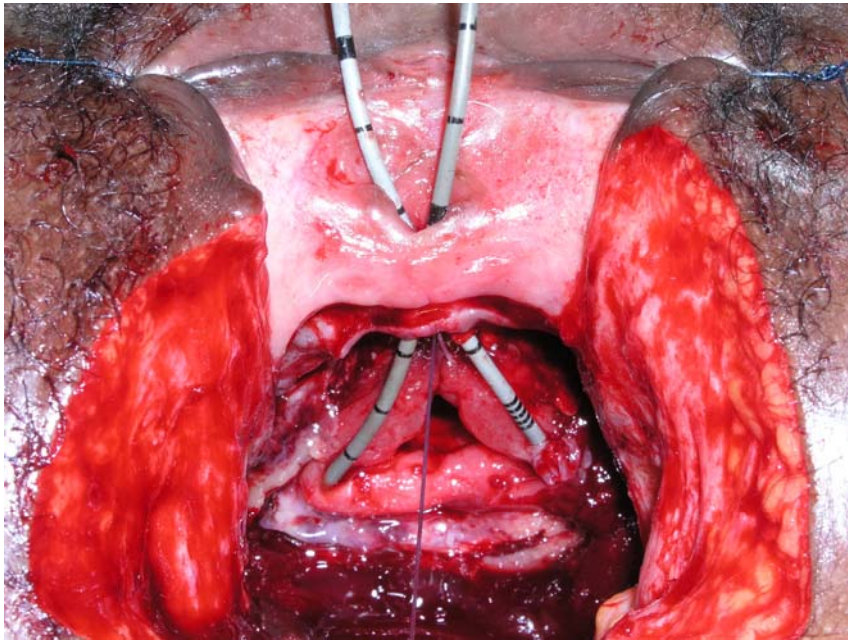
extensive fistula repair

circumferential dissection



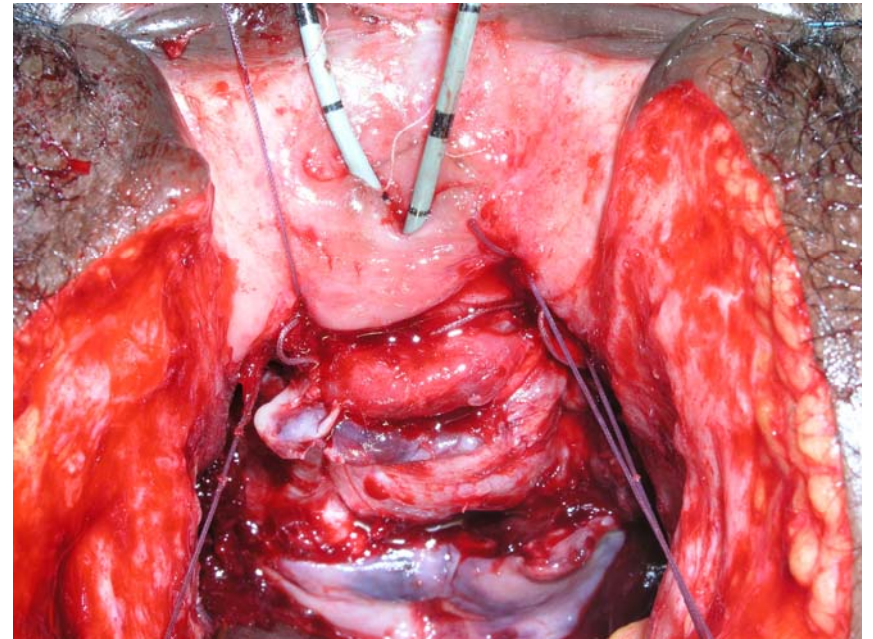
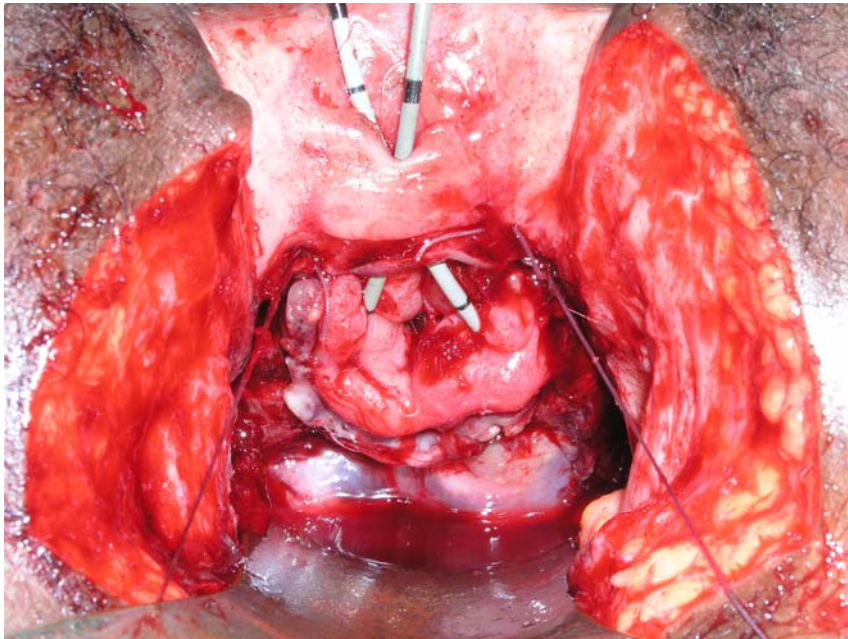
extensive fistula repair

advancement and fixation



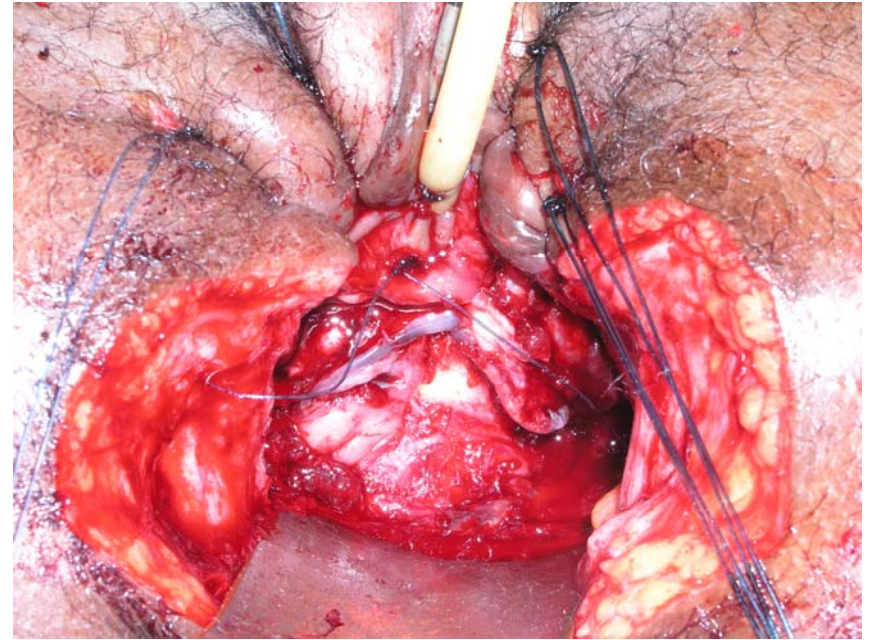
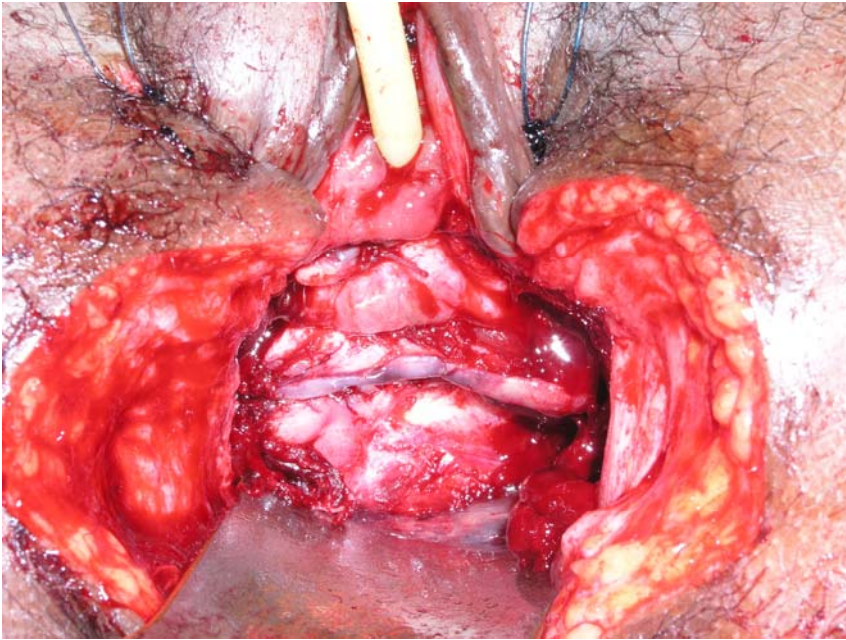
extensive fistula repair

circumferential closure



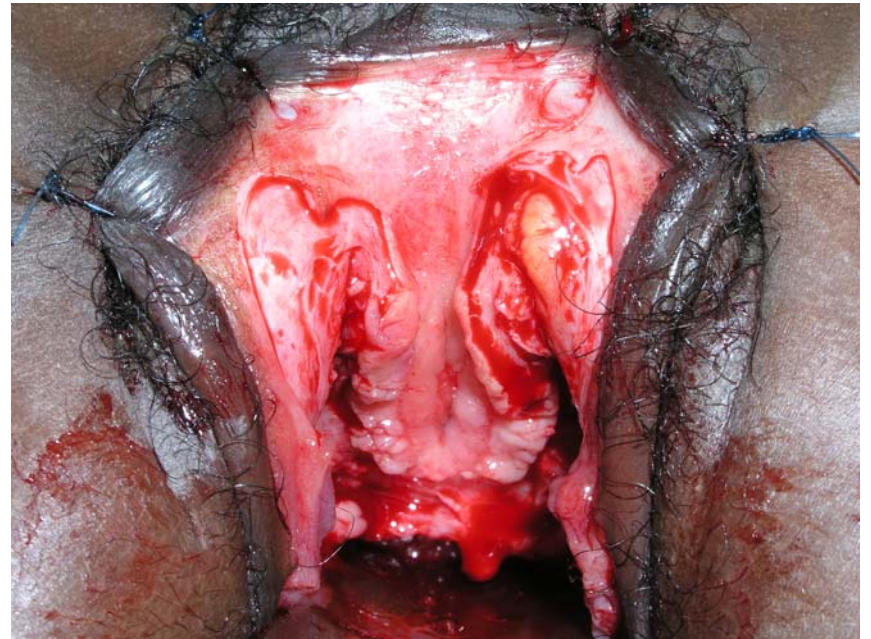
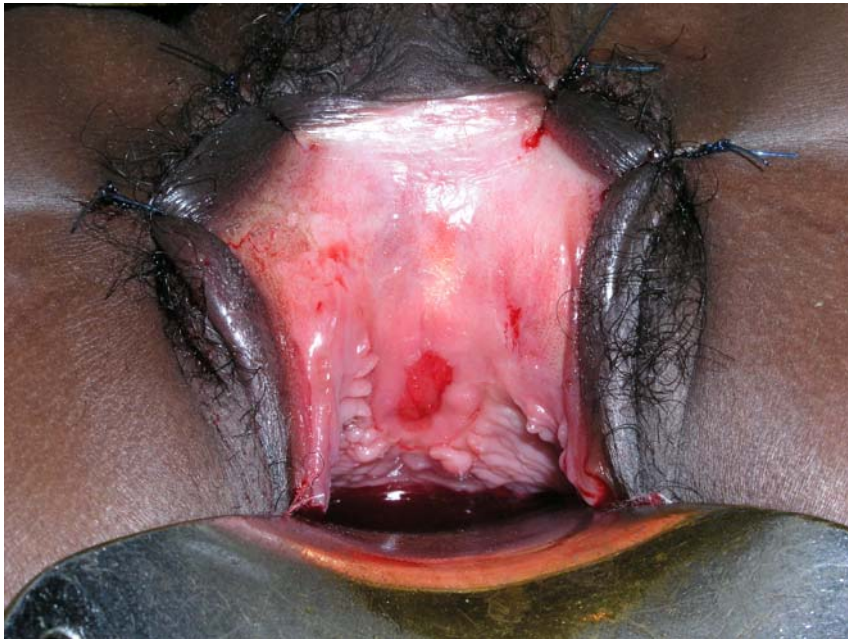extensive fistula repair

end-to-end vesicourethrosthomy



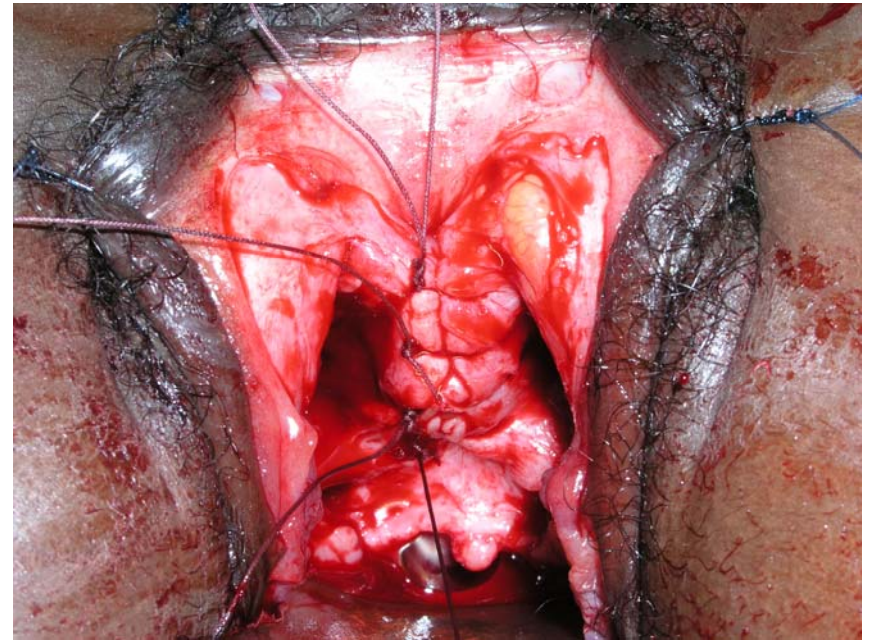
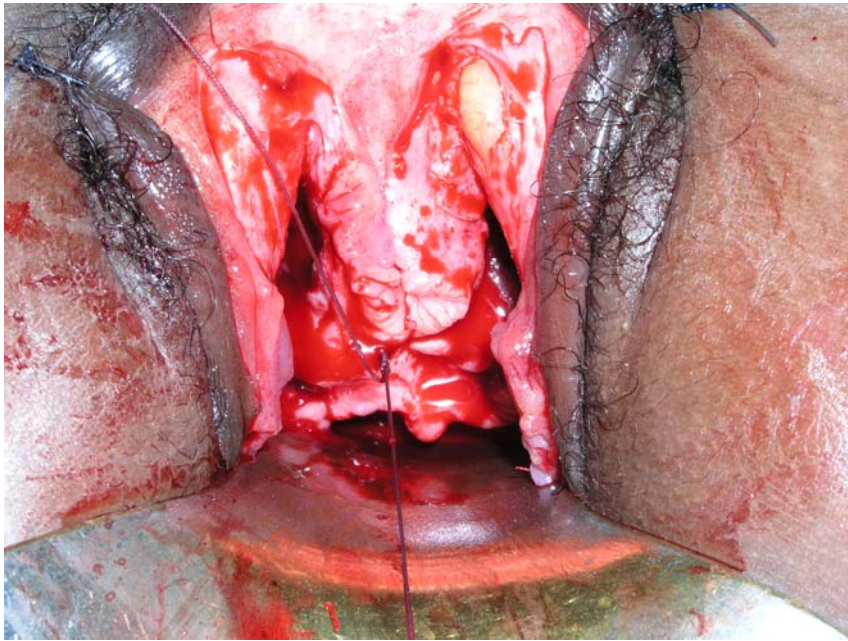
urethra reconstruction

incision and dissection



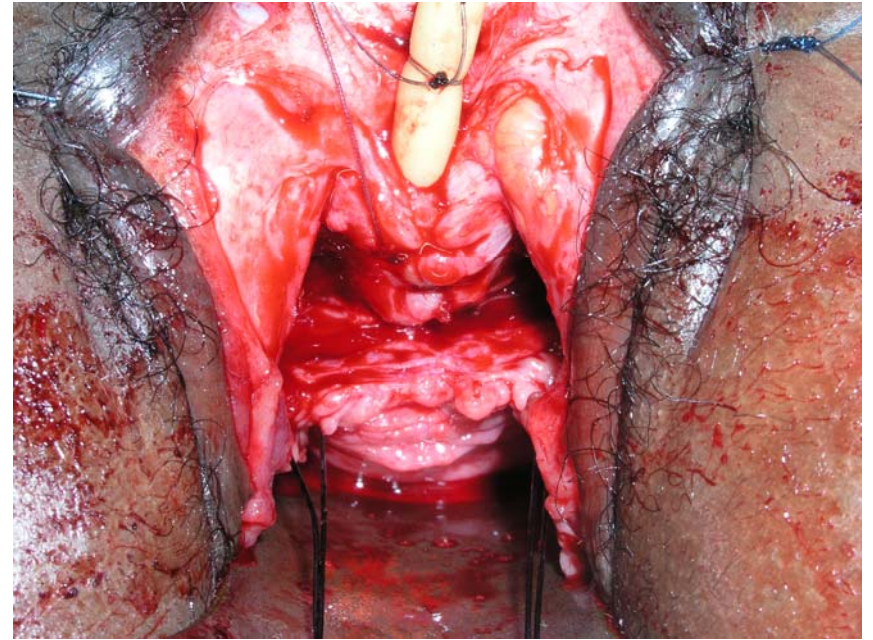
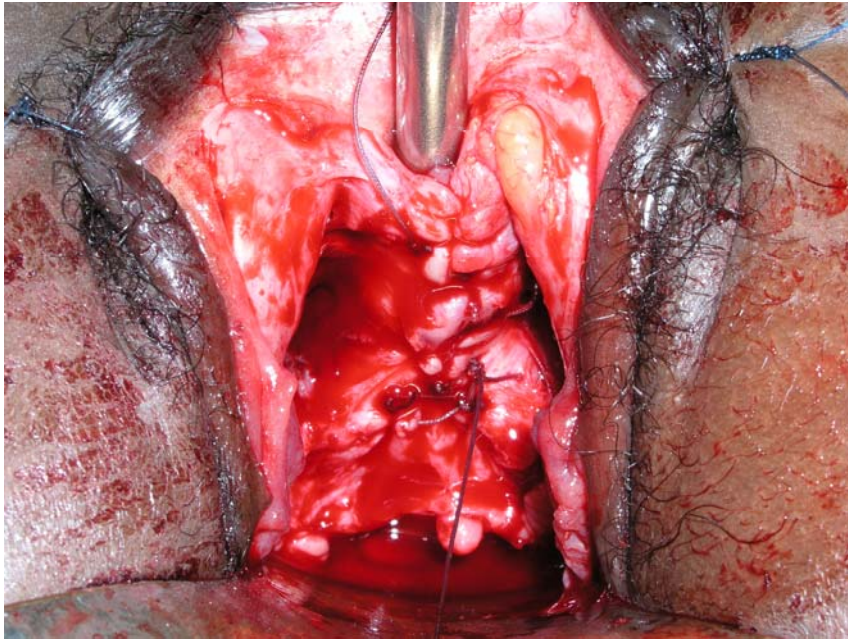
urethra reconstruction

longitudinal reconstruction



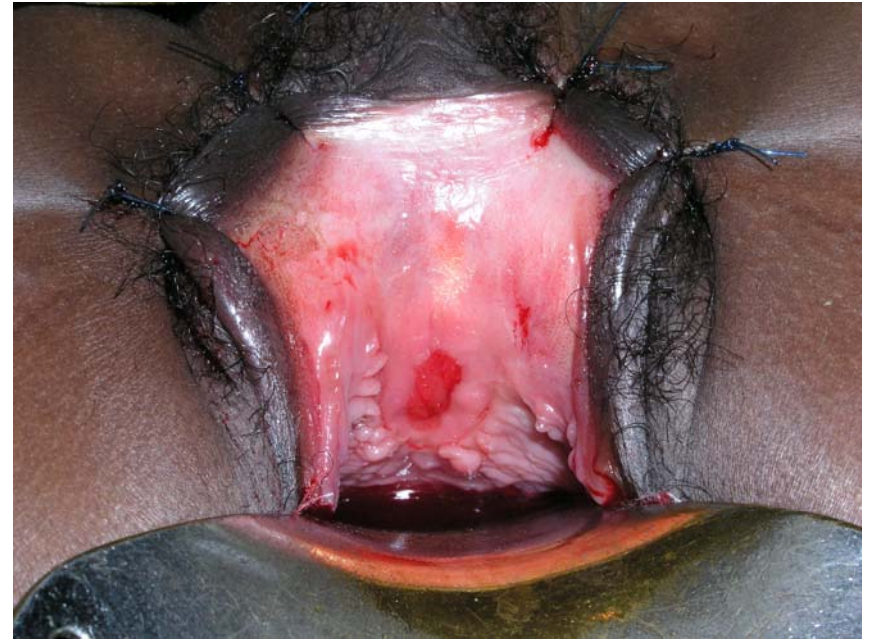
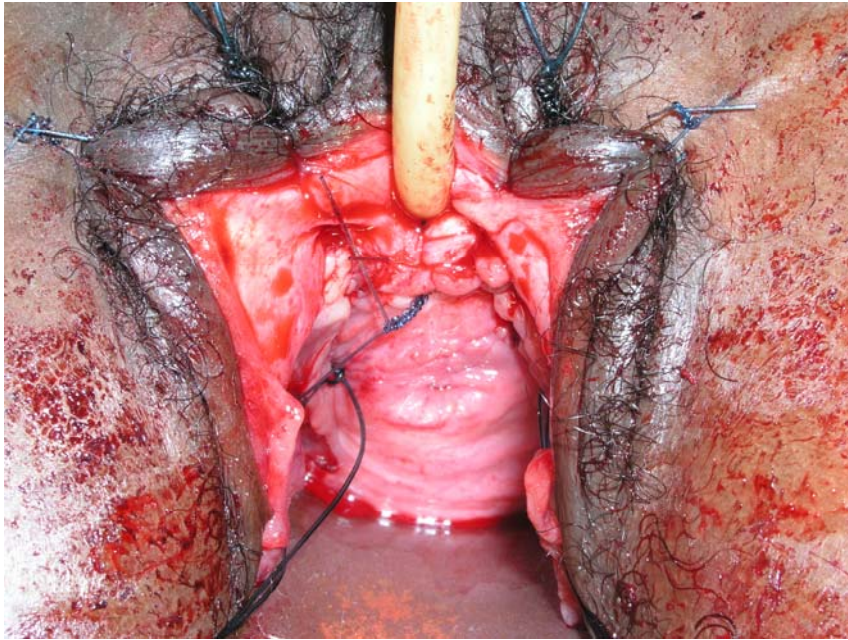
urethra reconstruction

checking diameter



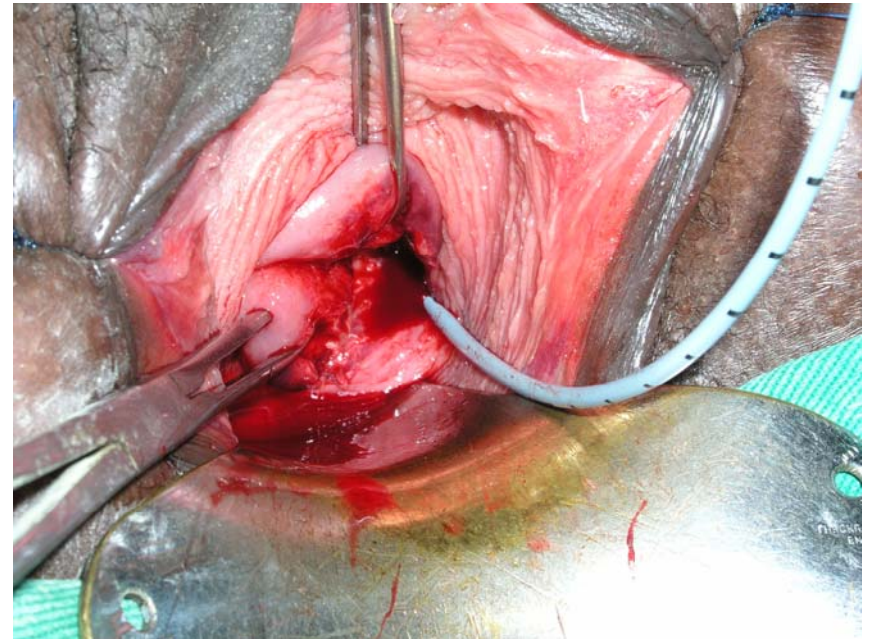
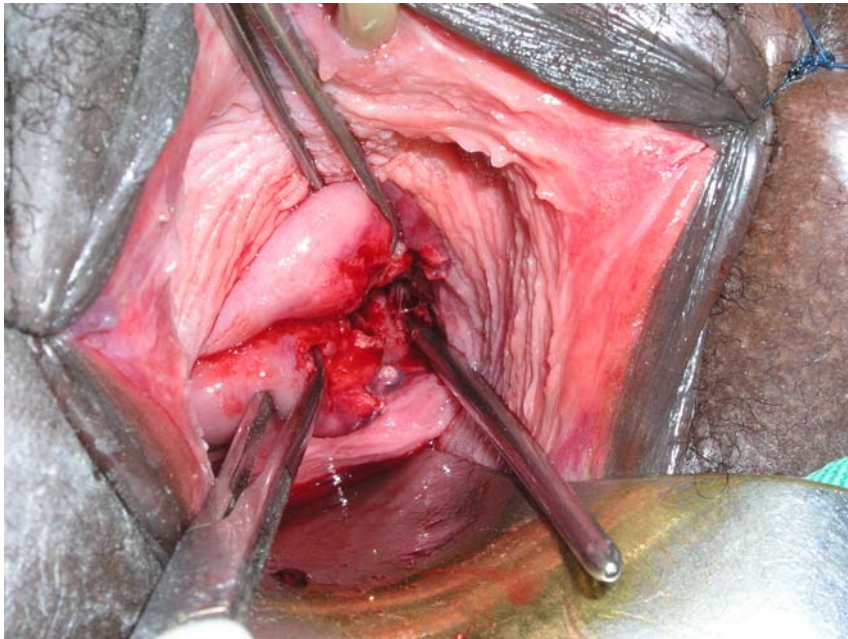
urethra reconstruction

anterior vagina wall advancement flap



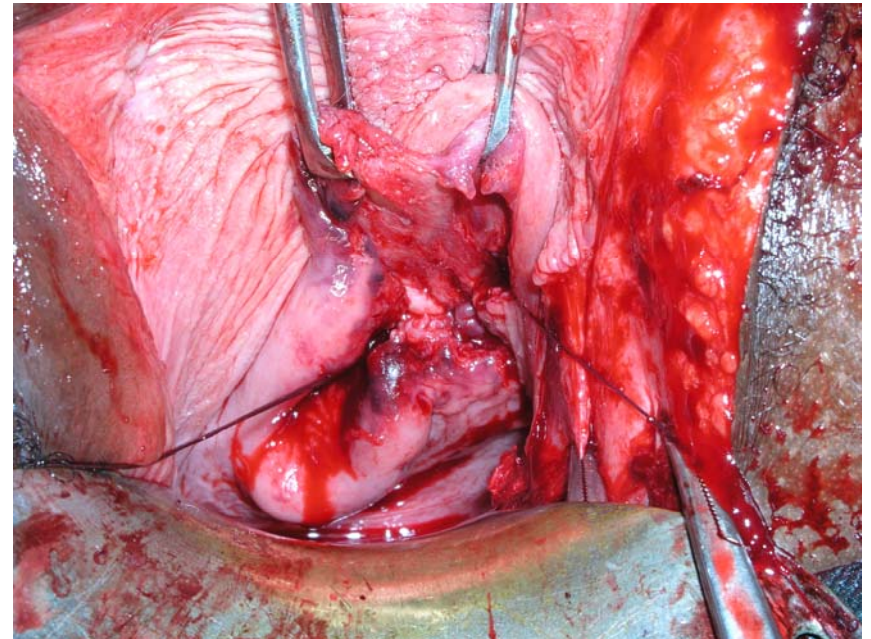
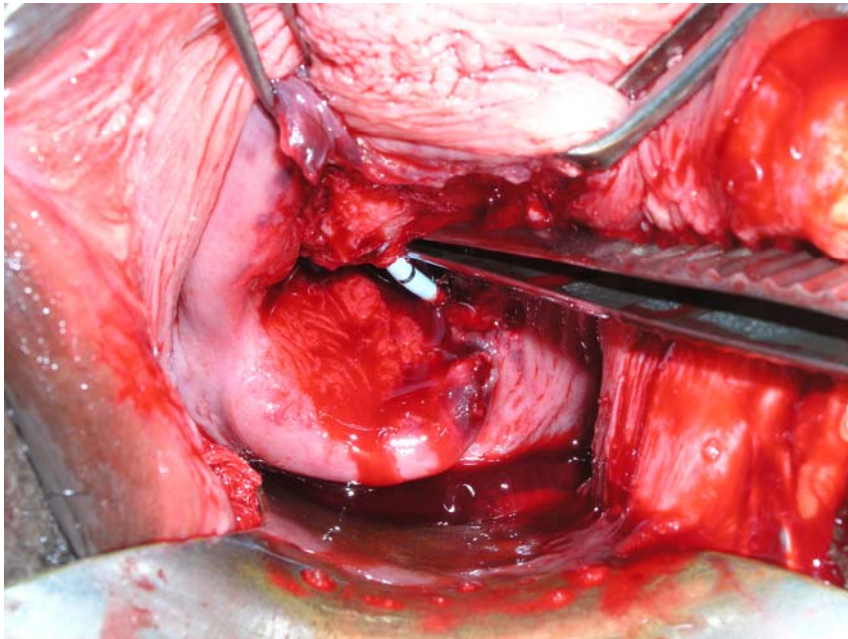
intracervical ureter fistula L

ureter catheterization



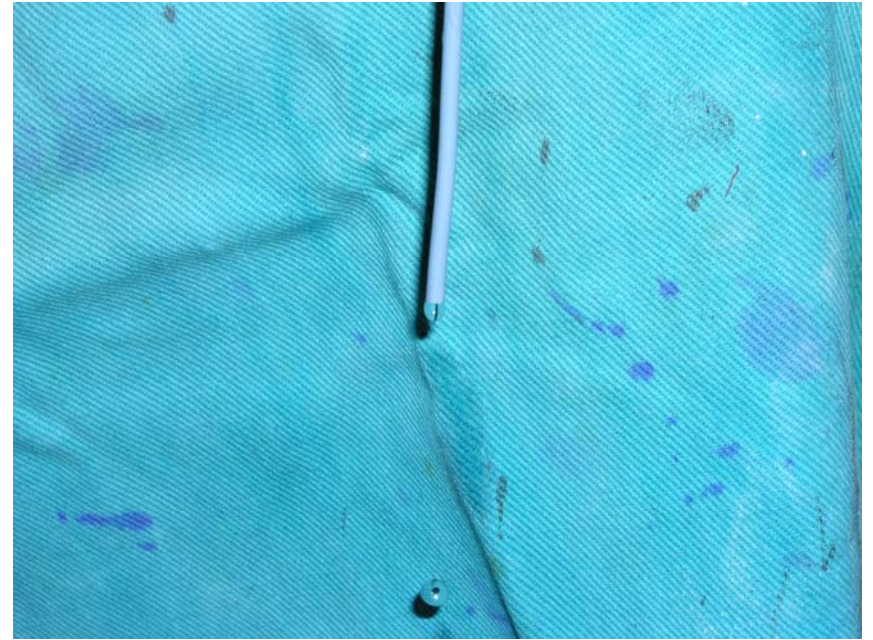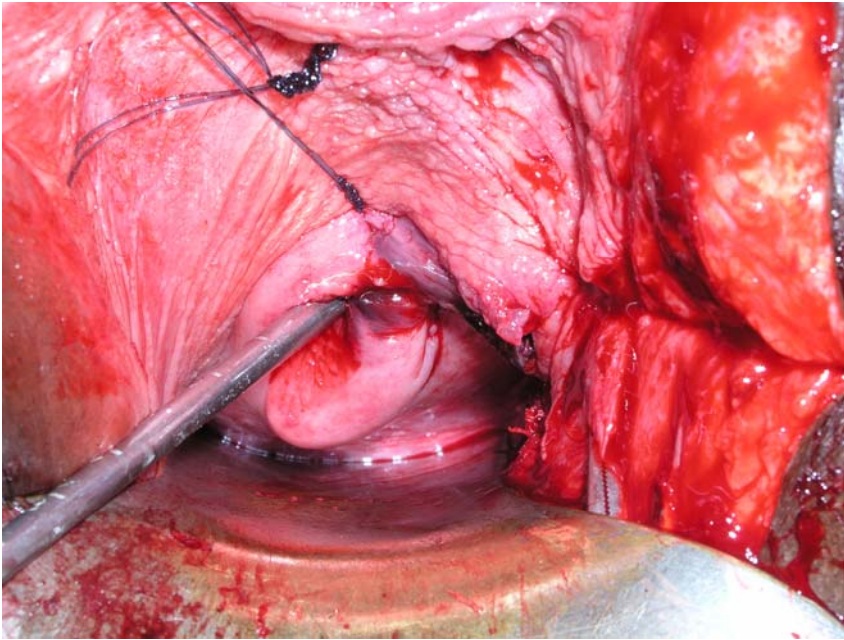
ureter fistula L

opening bladder, routing catheter, closing bladder

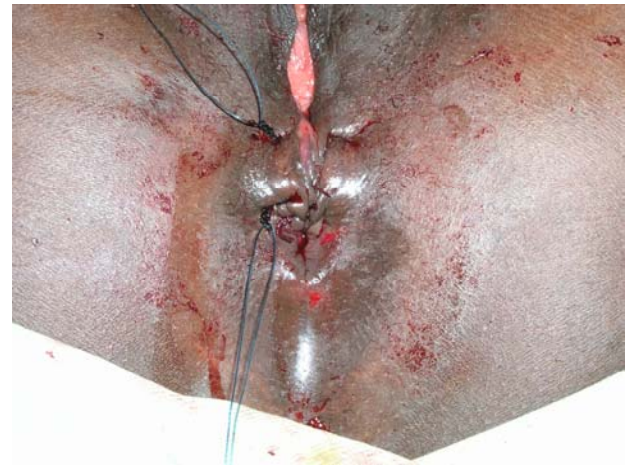
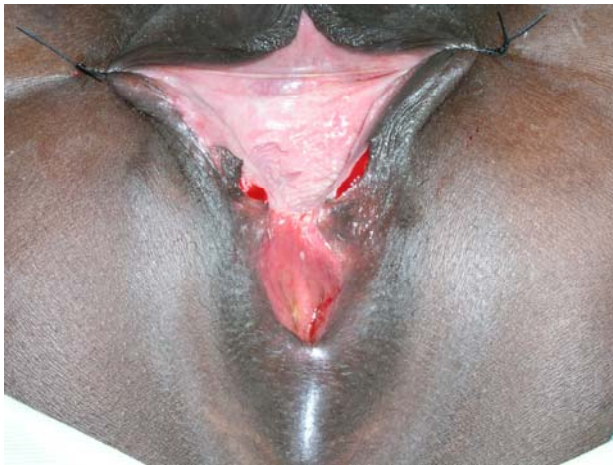
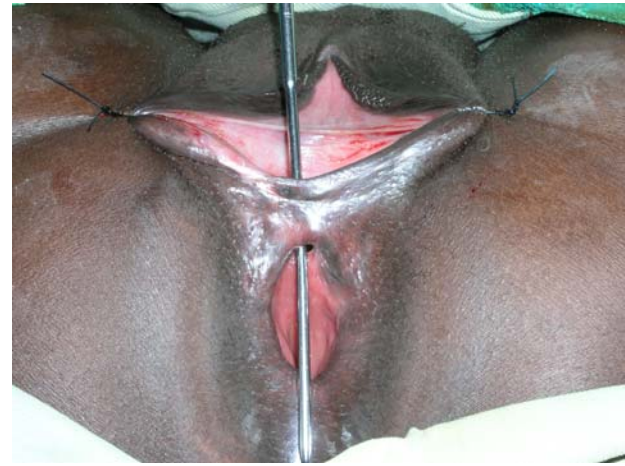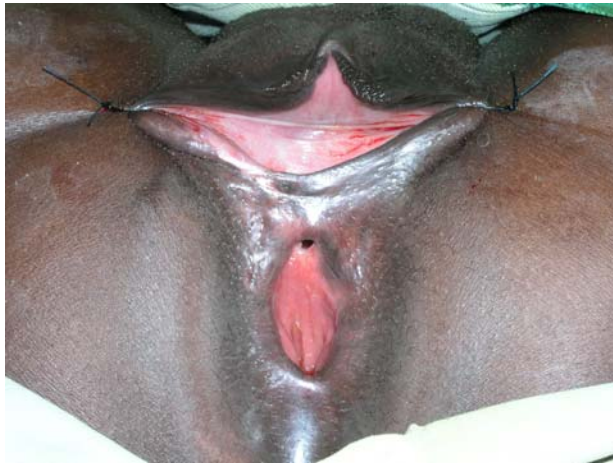ureter fistula L

cervix closure and checking urine flow

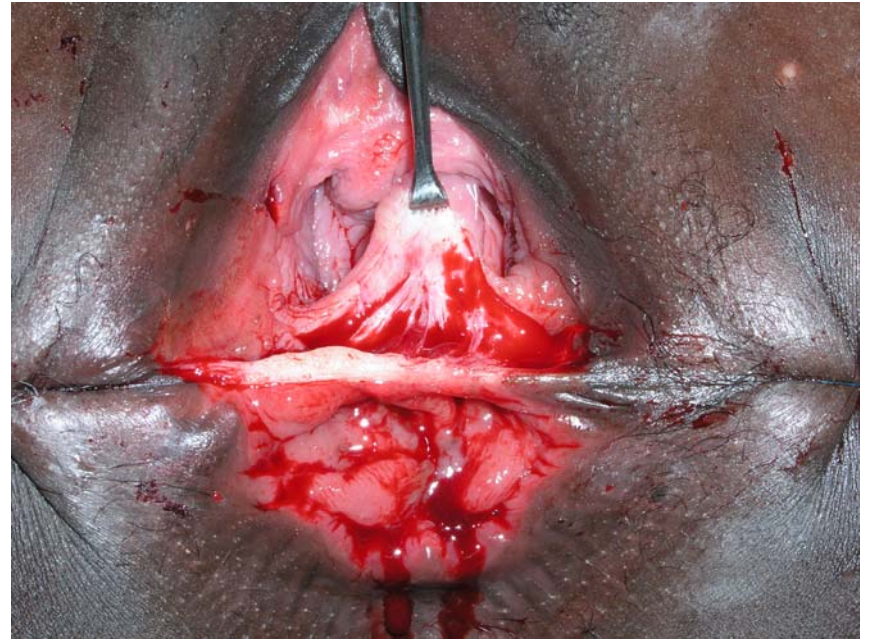
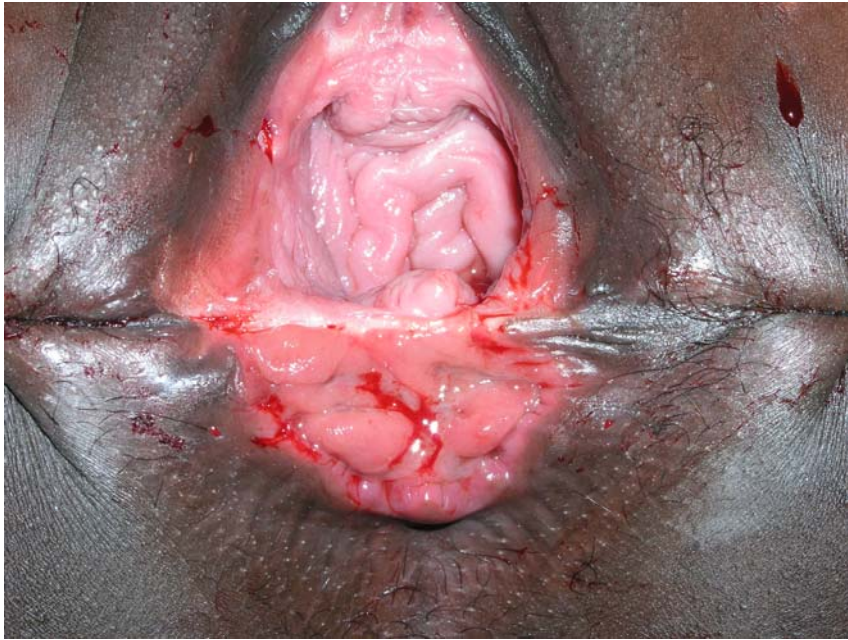

sphincter ani rupture with rectum trauma



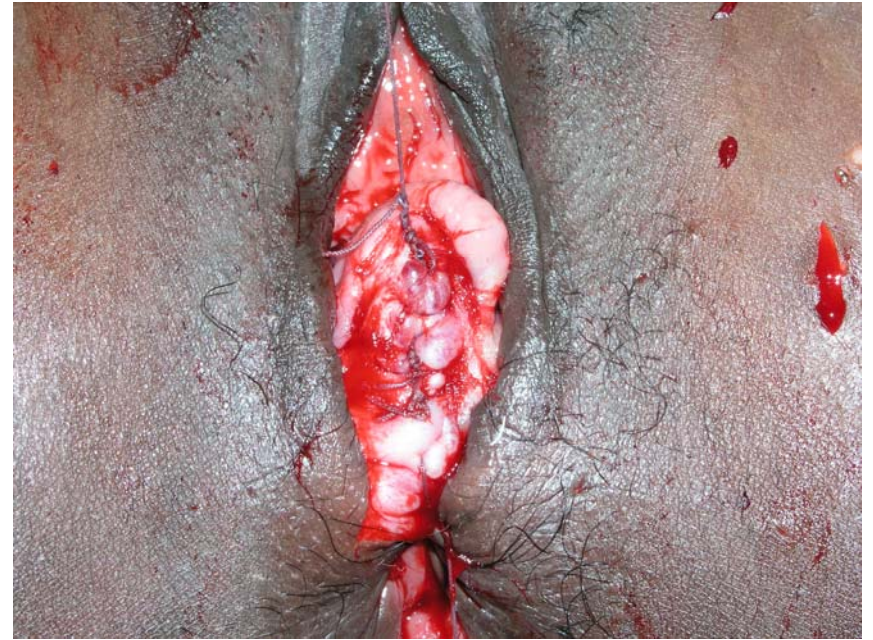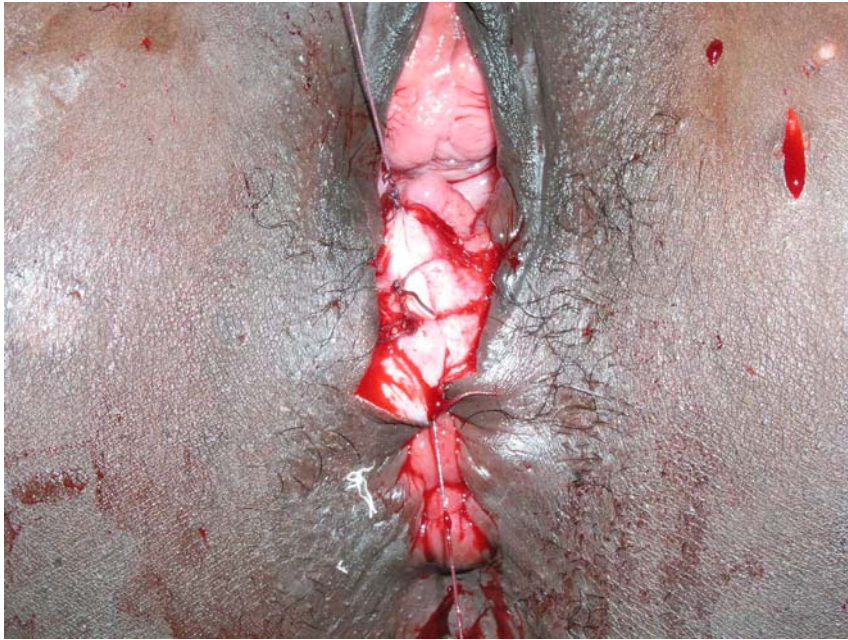sphincter ani repair

with rectum closure



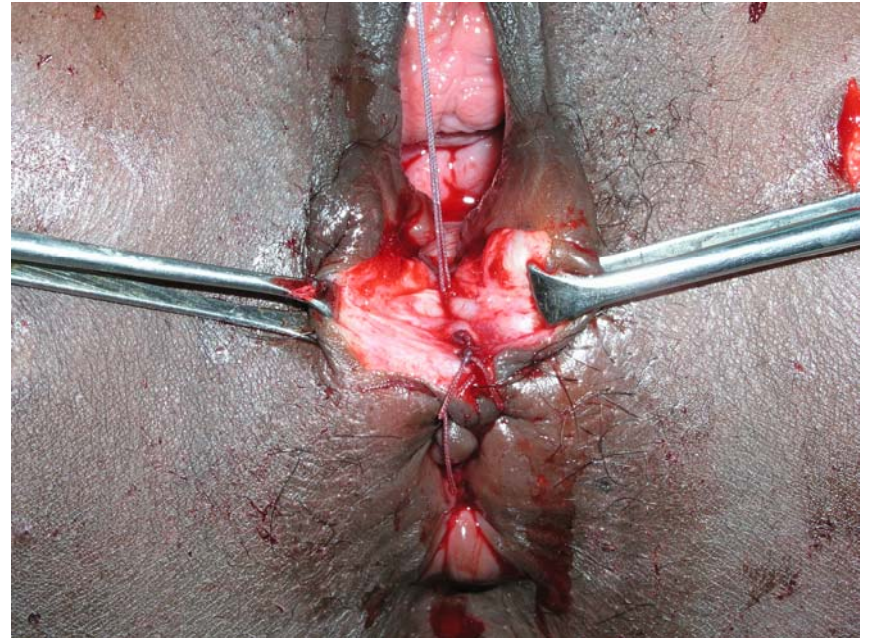
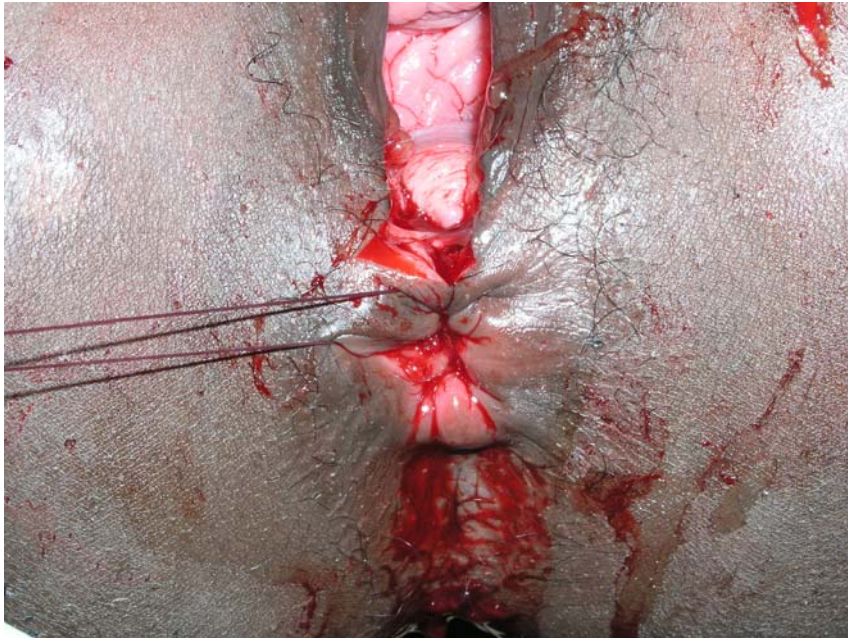sphincter ani repair

rectum closure



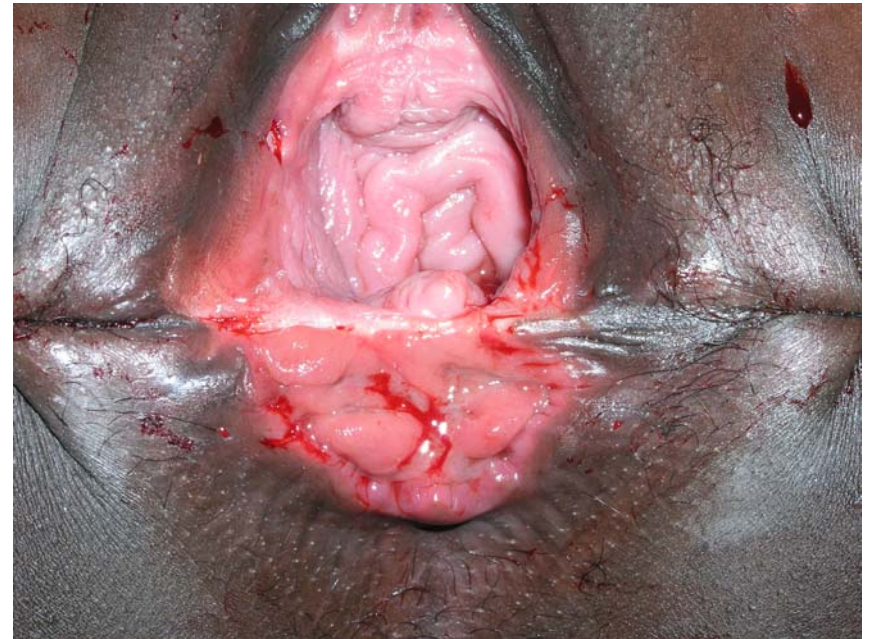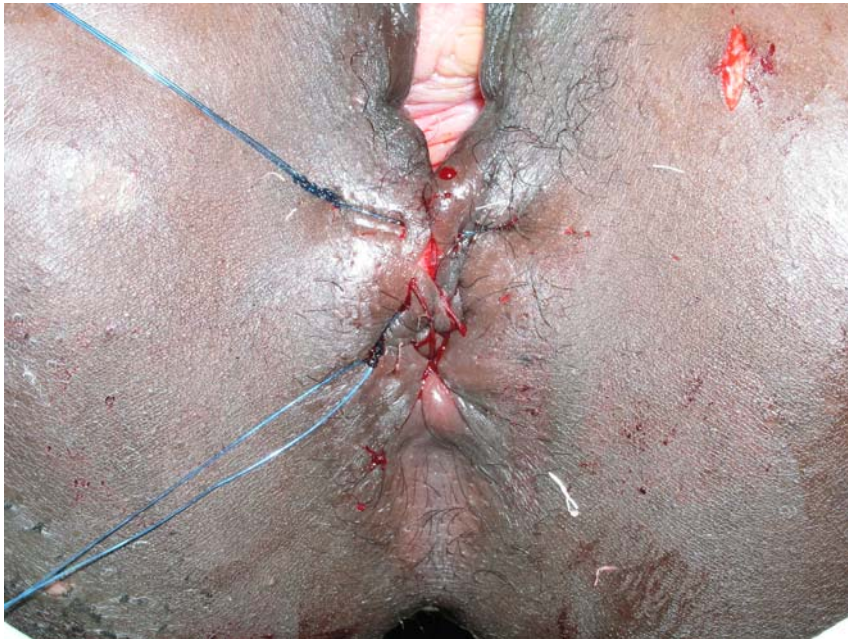sphincter ani repair

sphincter repair

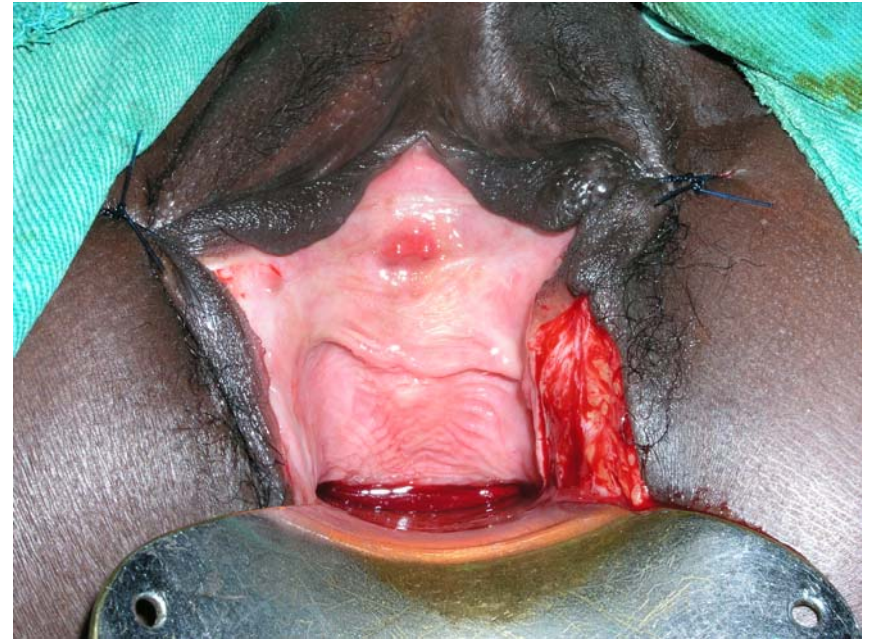
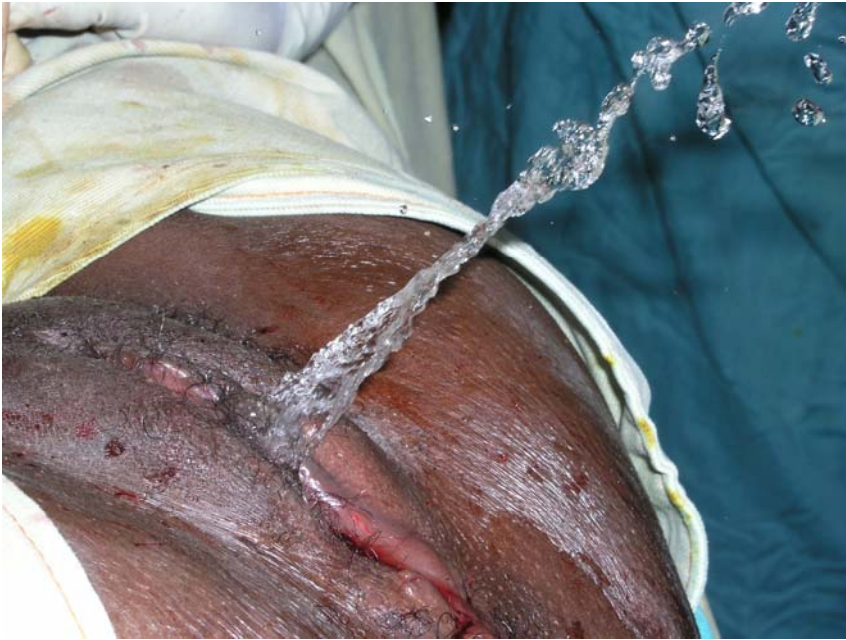

sphincter ani repair

deep low-tension perineum adaptation

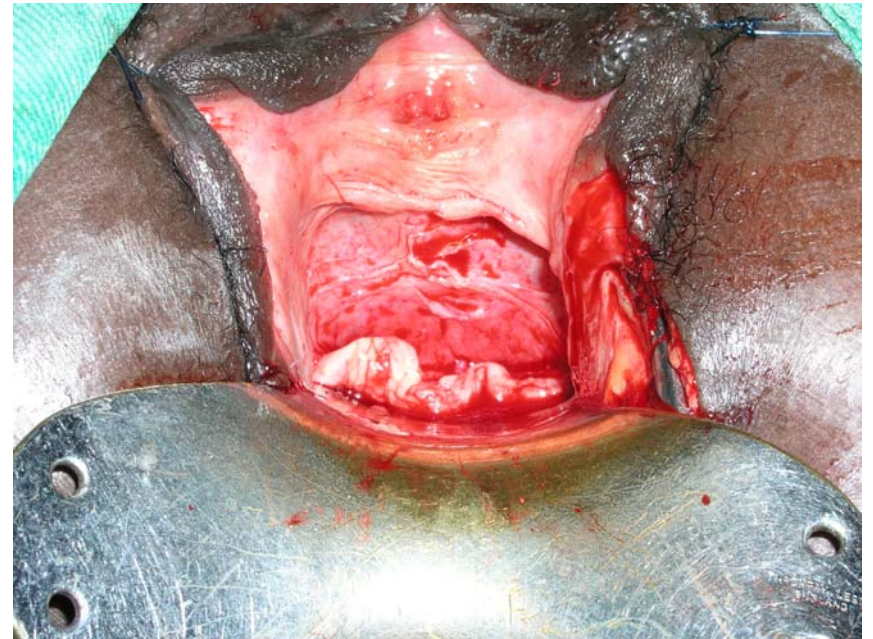
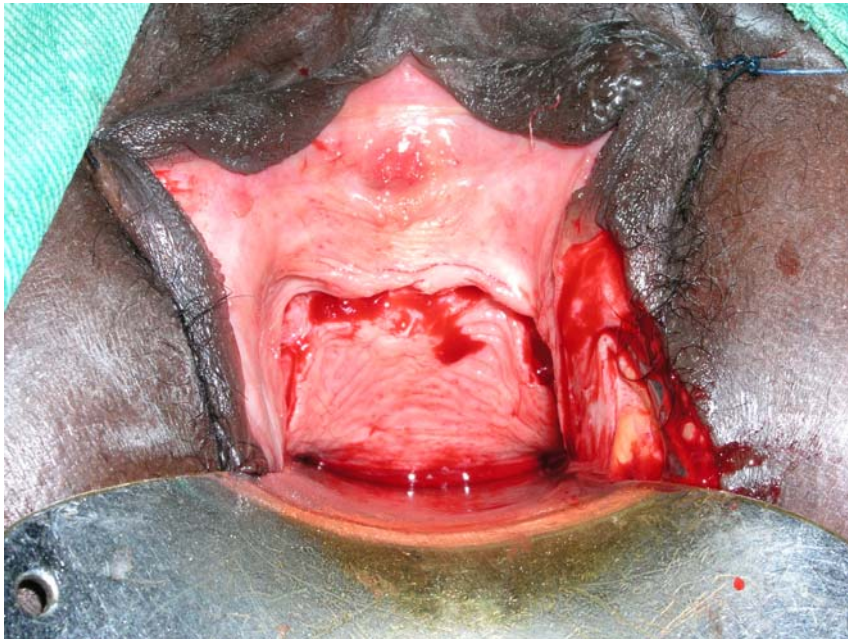


intrinsic_stress incontinence



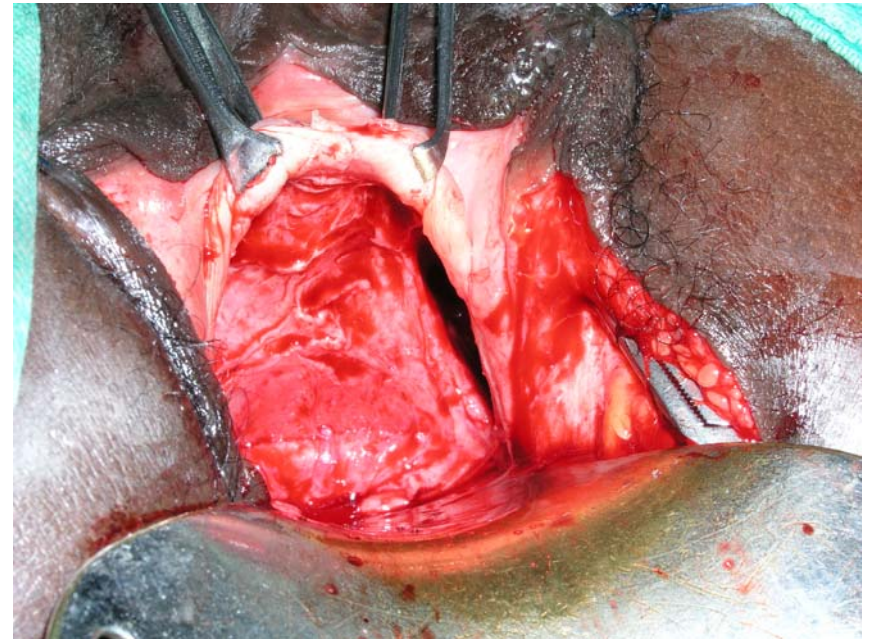
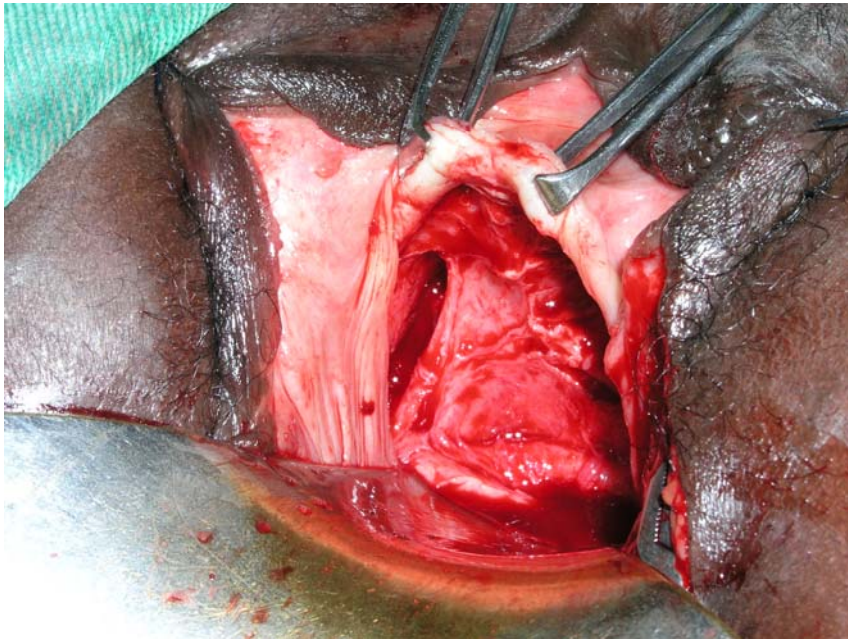
intrinsic_stress incontinence

incision and dissection



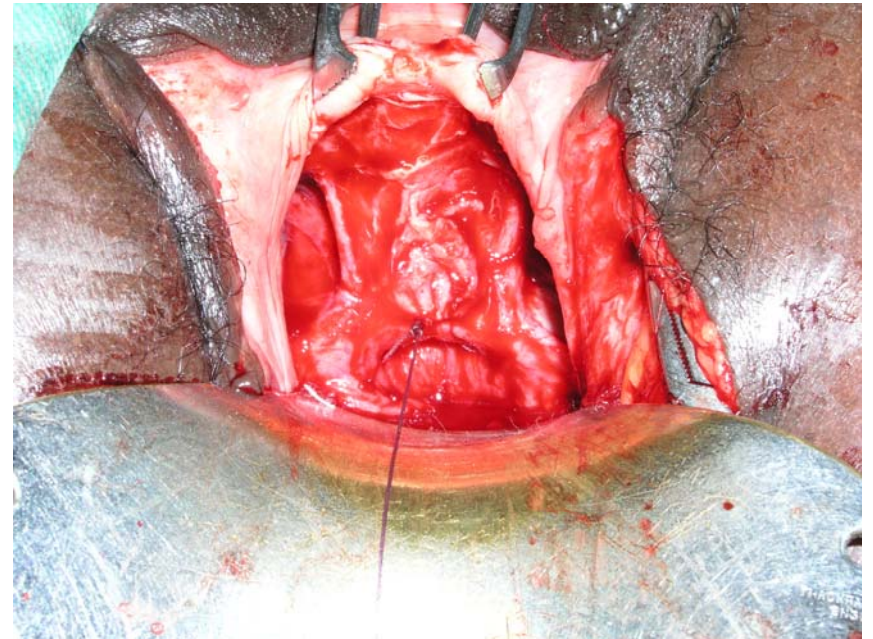
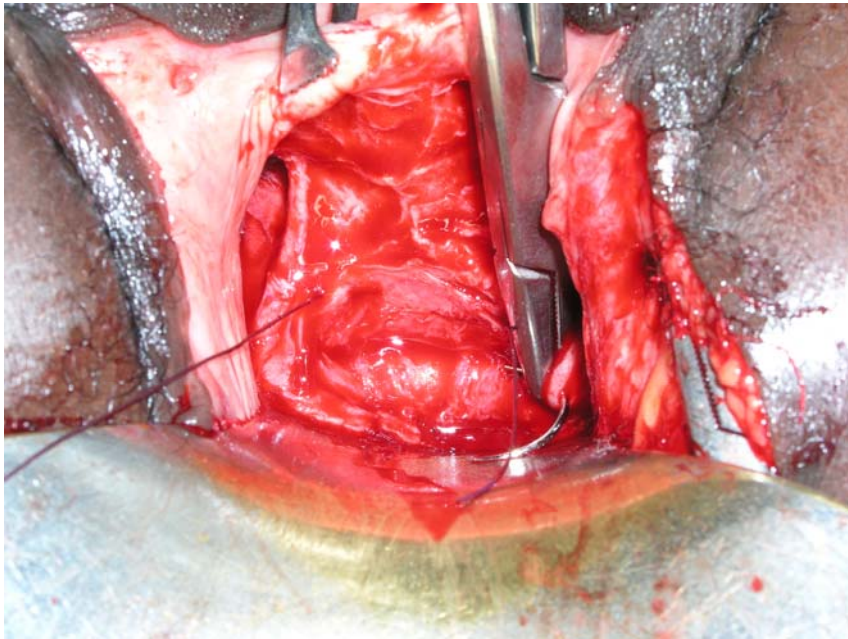
intrinsic_stress incontinence

paravesical spaces



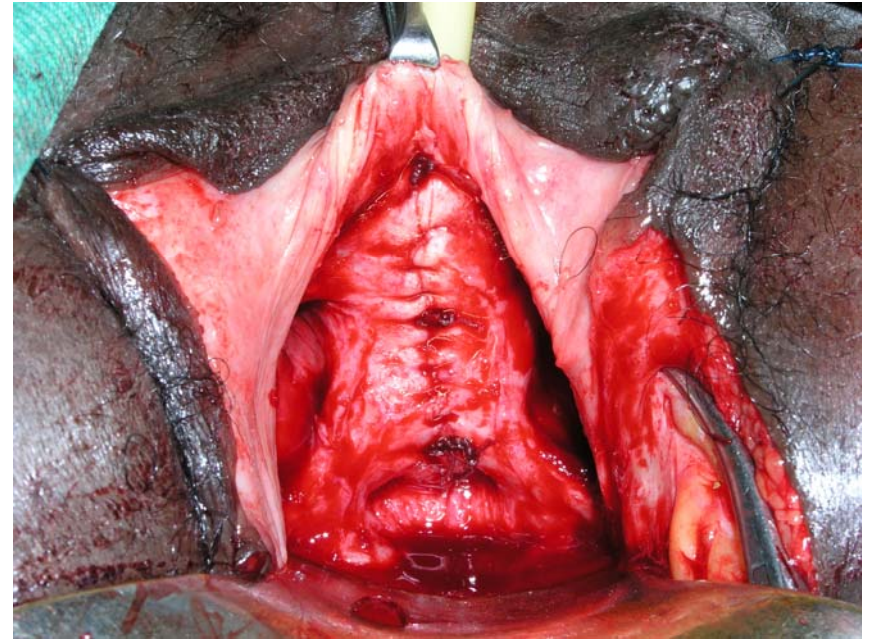
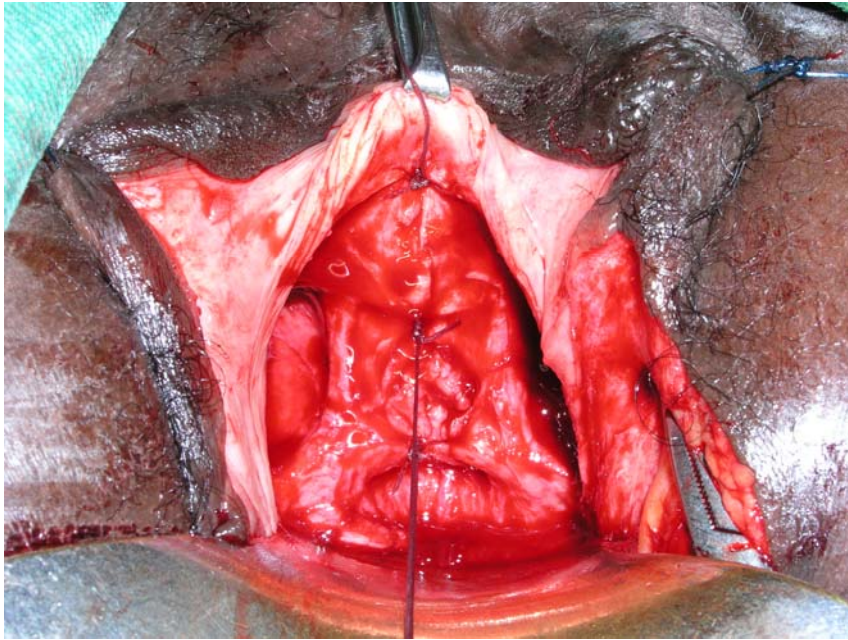
intrinsic_stress incontinence

rhaphy of urethra_fascia



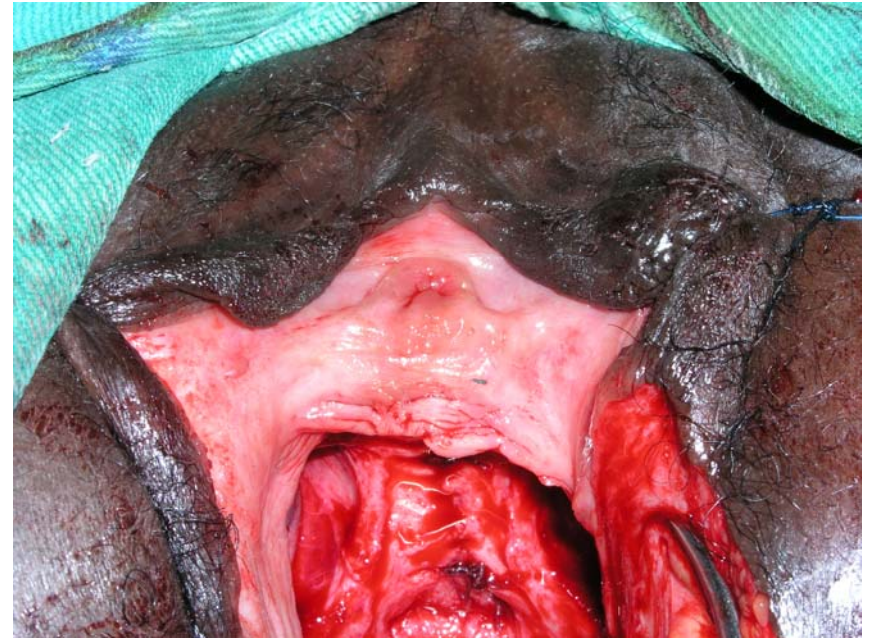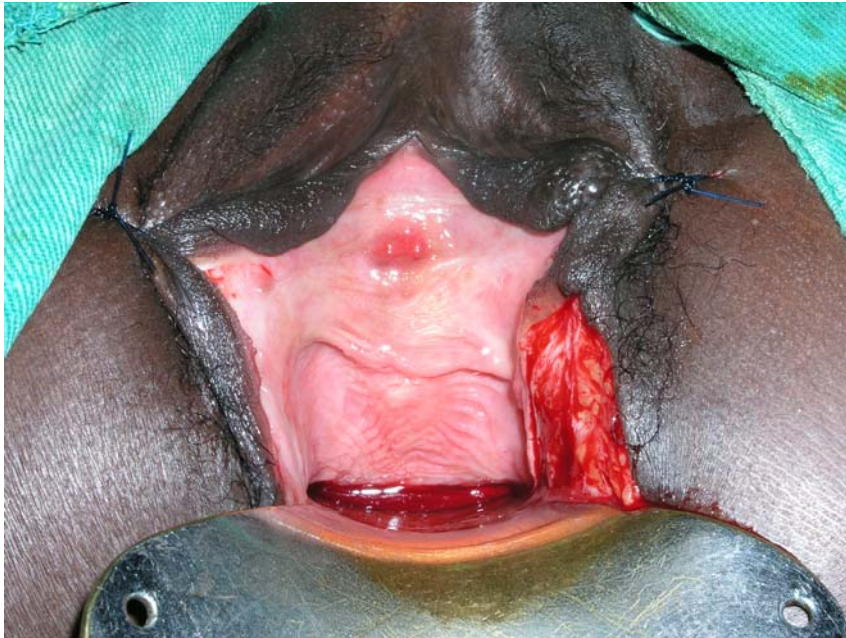
intrinsic_stress incontinence

interrupted_continuous raphy



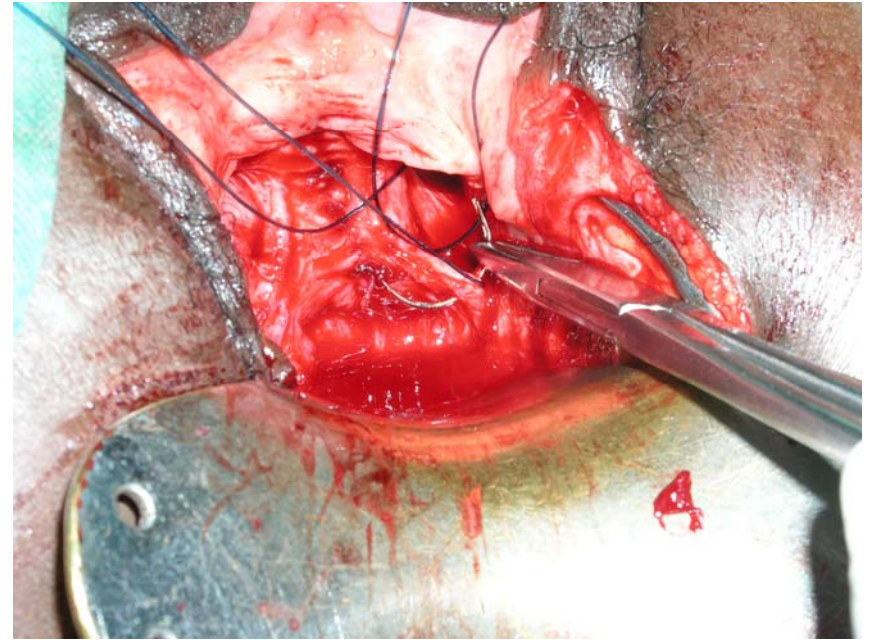
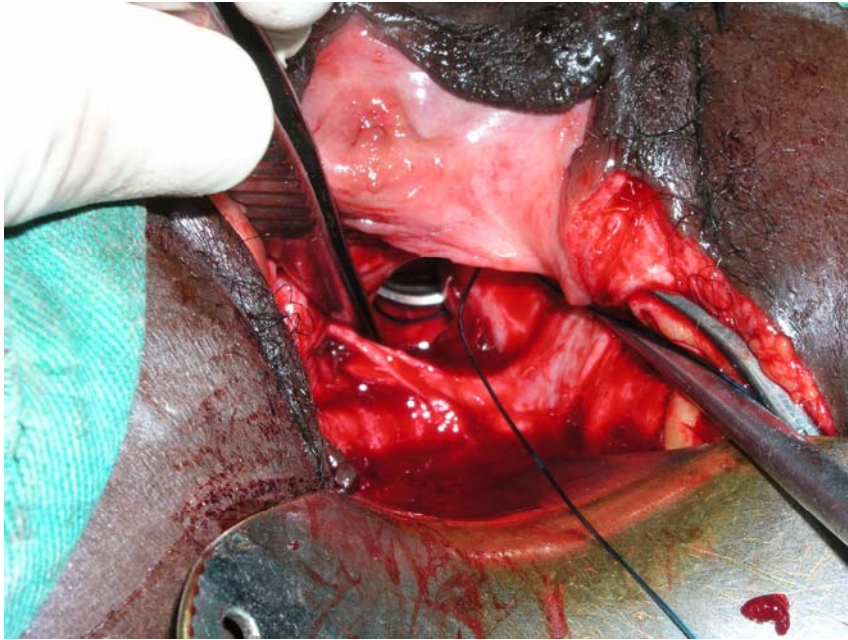
intrinsic_stress incontinence

external urethra opening before/after



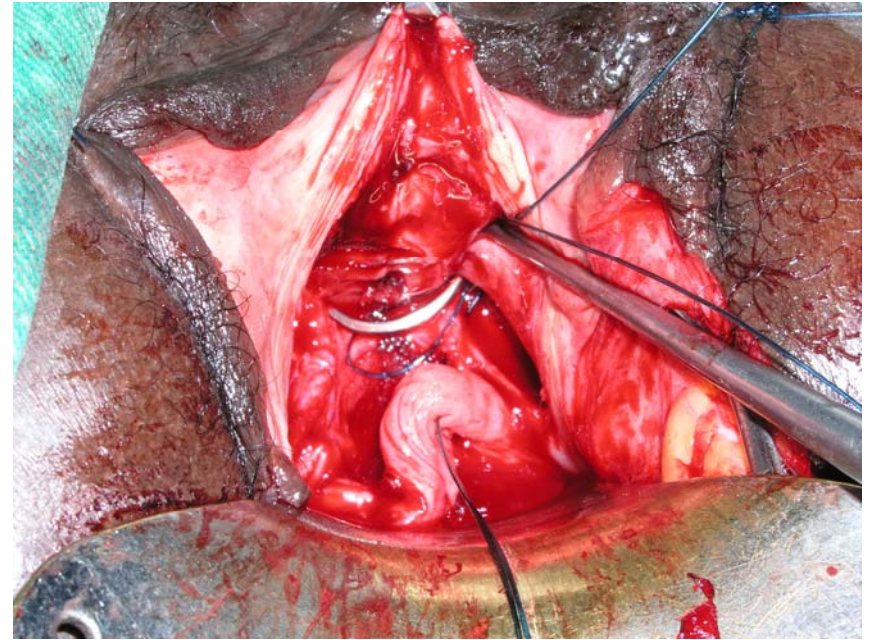
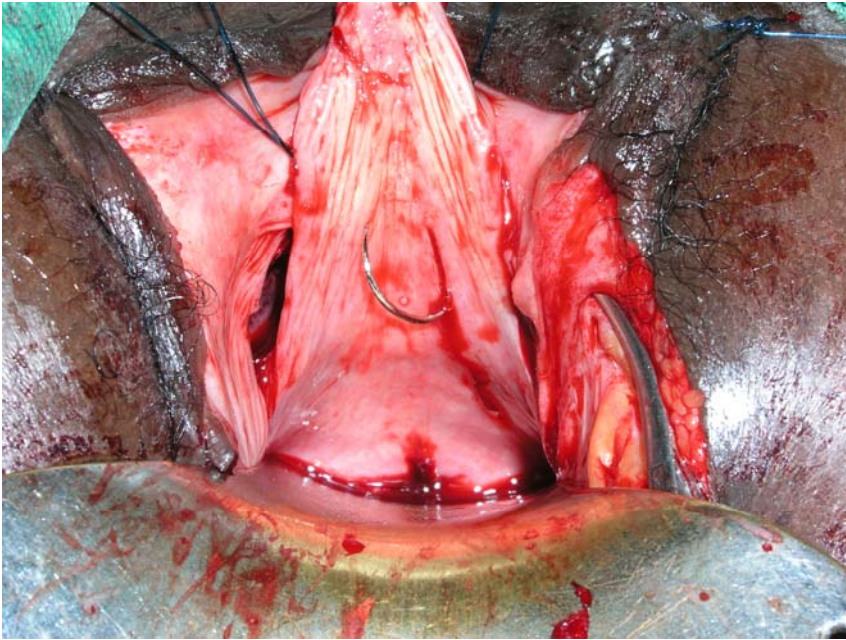
intrinsic_stress incontinence

fasciocolposuspension



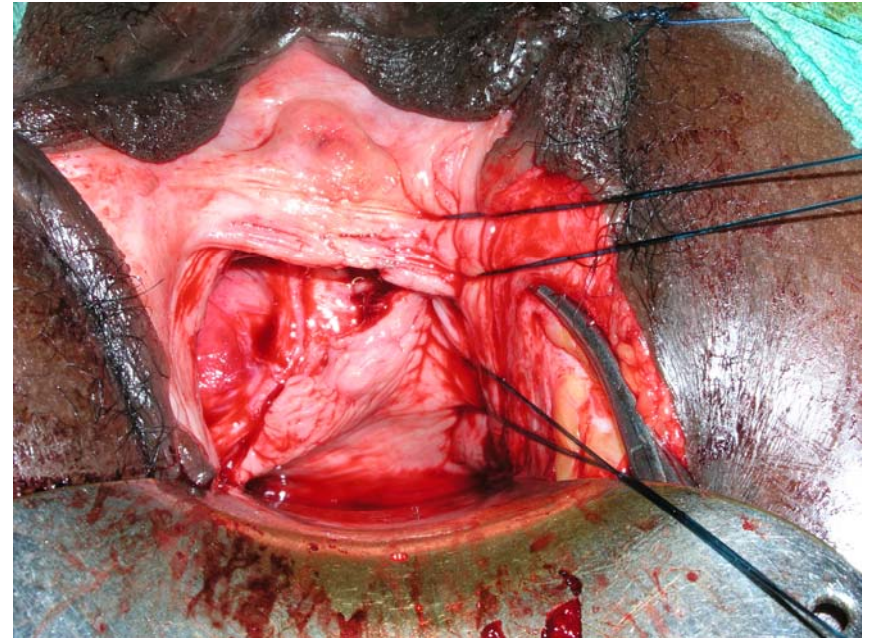
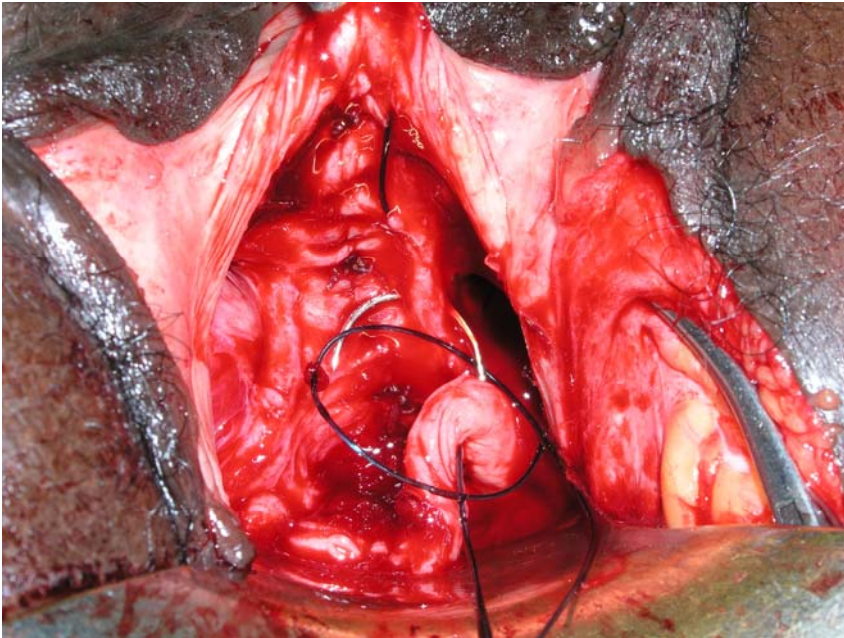
intrinsic_stress incontinence

fasciocolposuspension



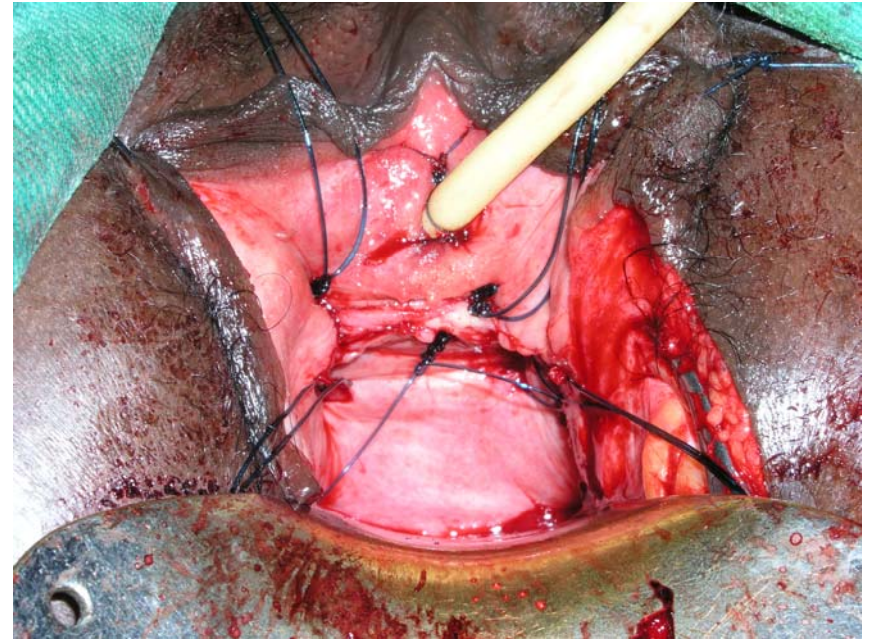
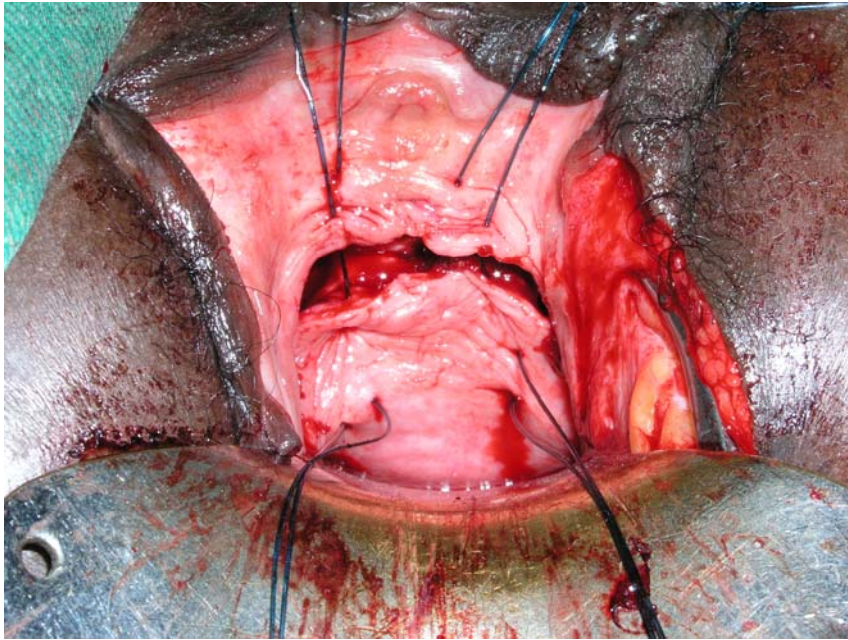
intrinsic_stress incontinence

fasciocolposuspension



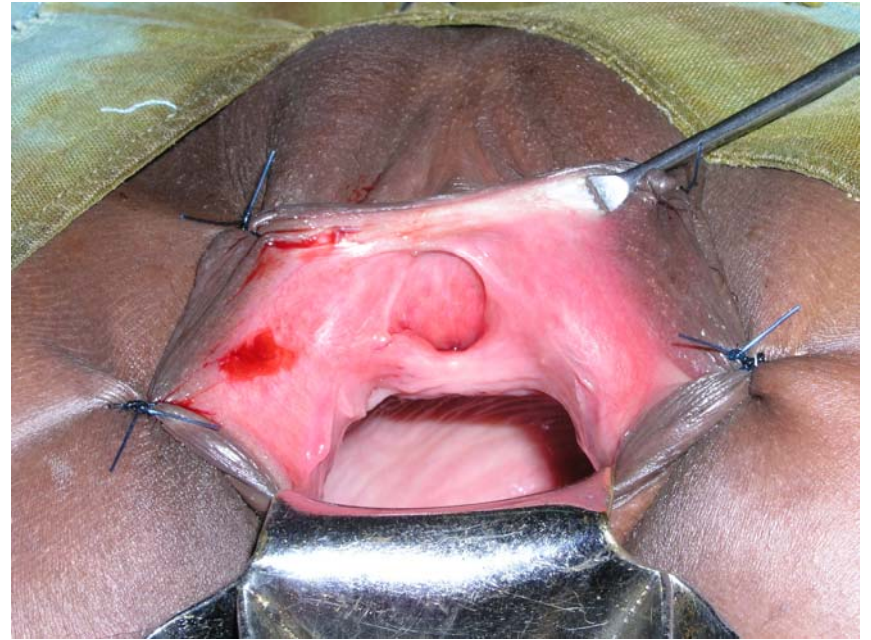
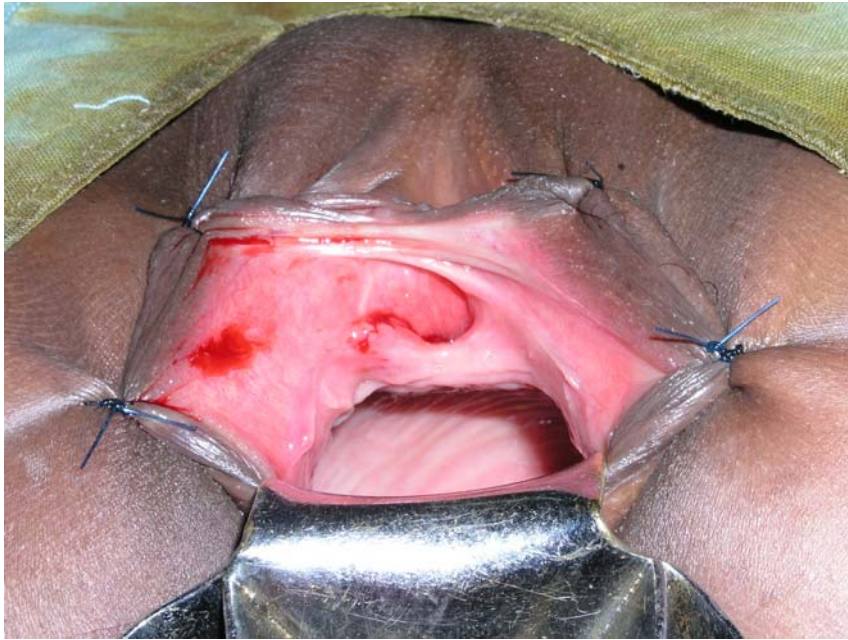intrinsic_stress incontinence

fasciocolposuspension



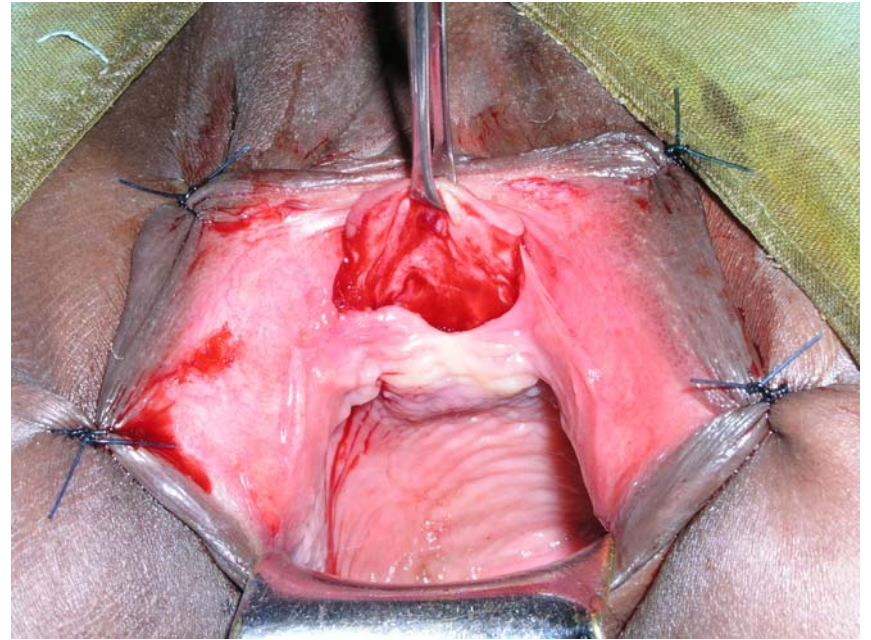
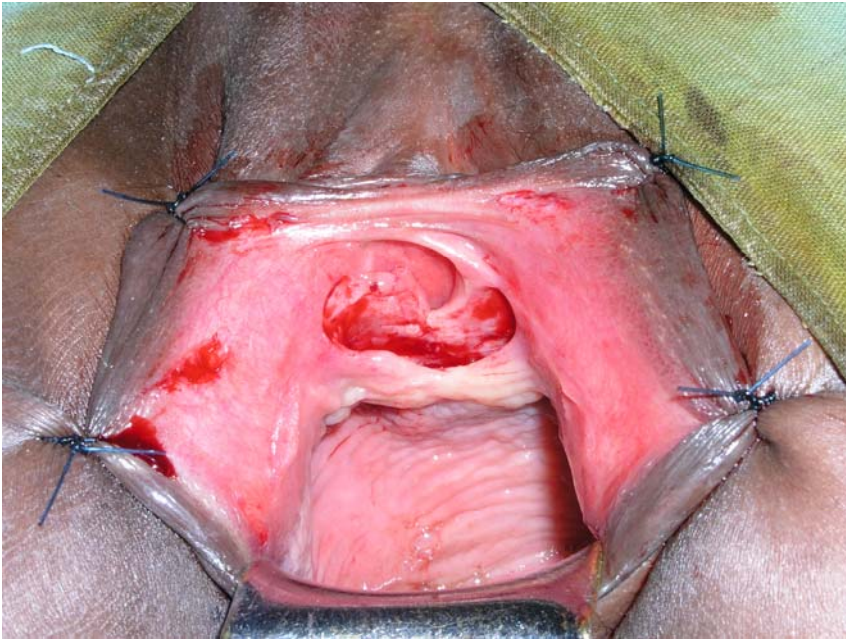
open urethra

with intrinsic_stress incontinence

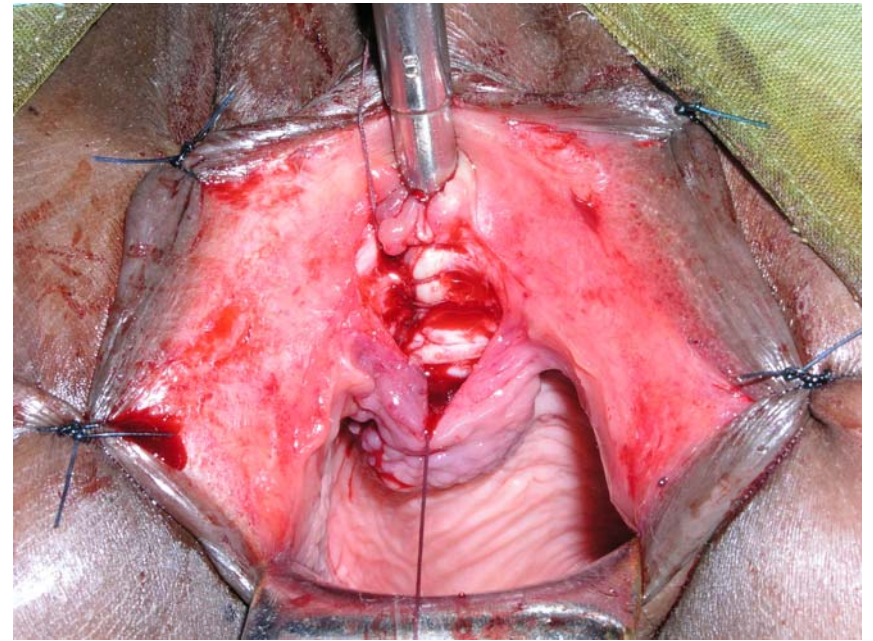
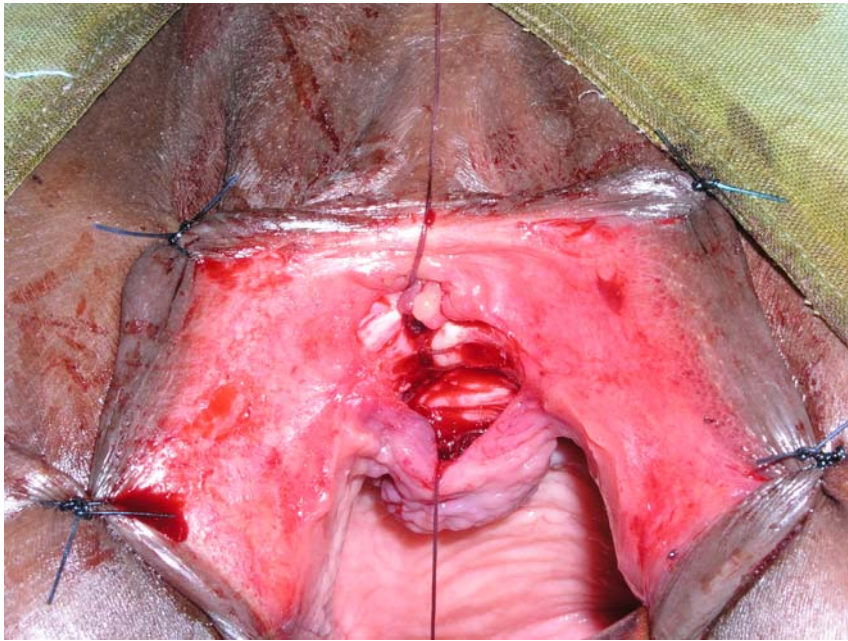


open urethra

incision and dissection



open urethra rhaphy



open urethra

anterior vagina wall closure

