



Clinique
GENERALE - BEAULIEU



Retrograde Robotic Extraperitoneal Laparoscopic Prostatectomy (RRELPS)

C.H. Rochat, Geneva
P. Dubernard, Lyon

IRUS 2009,
Las Vegas

Laparoscopic prostatectomy (LP)

Sept. 1991

First intraperitoneal

WW. Schuessler, U.S.A

June 1997

First extra-peritoneal

A. Raboy, U.S.A

Nov. 1997

French first

*R. Gaston (followed by CC. Abbou,
B. Guillonneau and G. Vallencien)*

March 1999

Swiss first

C.H. Rochat, R. Gaston

Dec. 1999

First retrograde extra-peritoneal

P. Dubernard

Robotic Laparoscopic Prostatectomy (RLP)

May 2000	<i>J. Binder, Frankfurt</i>
July, 2000	<i>C.C. Abbou, Paris</i>
Sept. 2000	<i>G. Vallencien, Paris</i>
Nov. 2001	<i>M. Menon, Detroit</i>
Jan. 2003	<i>C.-H. Rochat, R. Gaston, Geneva</i>

Robotic Retrograde Extraperitoneal Laparoscopic Prostatectomy (RREL P)

- History of heavy abdominal surgery
- Prevention of intra abdominal complications
- Interest in reproducing the classic RP

Clinique Generale Beaulieu

Geneva

Robotic Prostatectomy Preliminary Results N=303

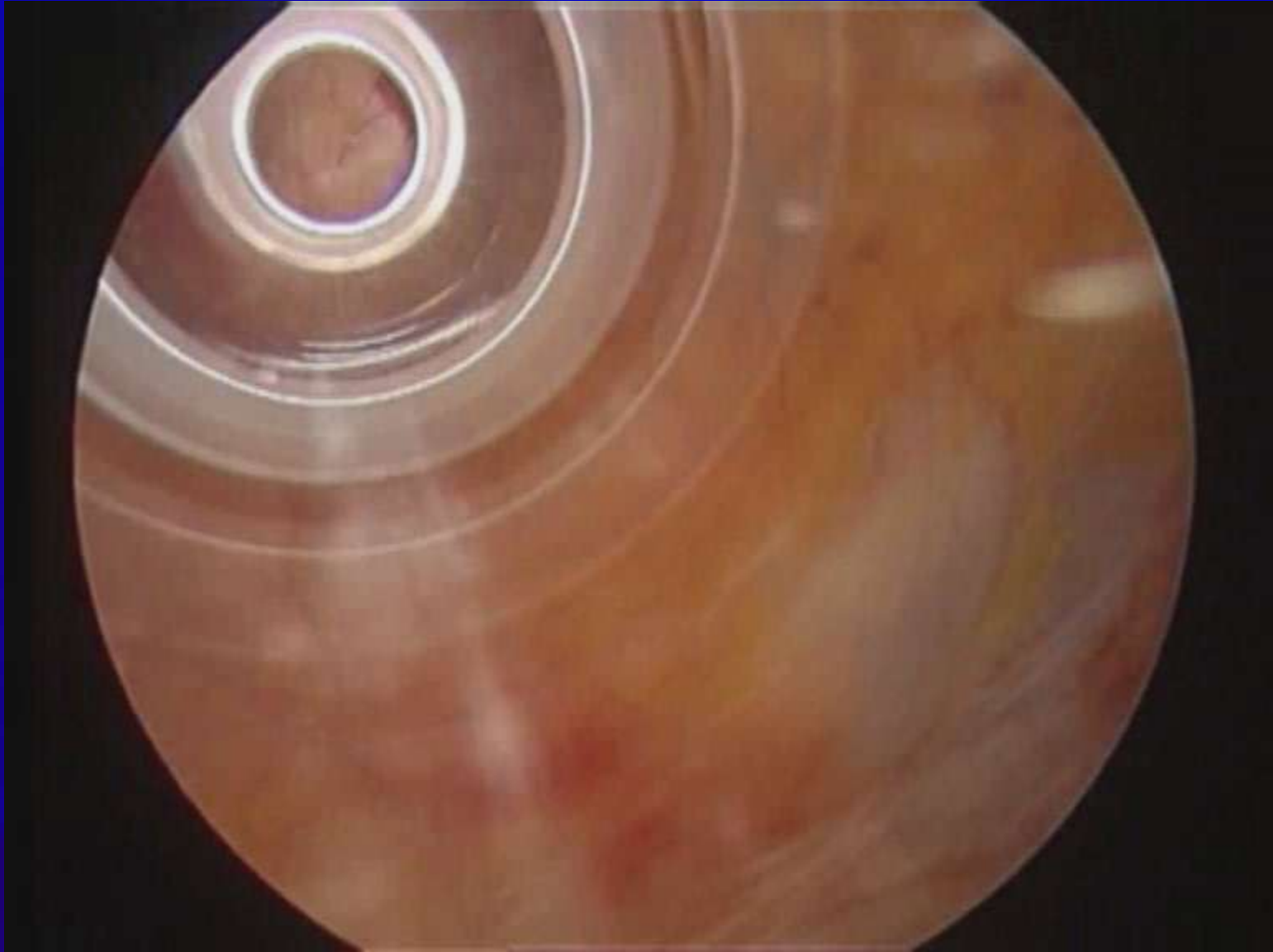
Operative Technique : 91% transperitoneal
 9% extraperitoneal

All cases of RRELP completed by 2 surgeons :
C.H. Rochat, P. Dubernard

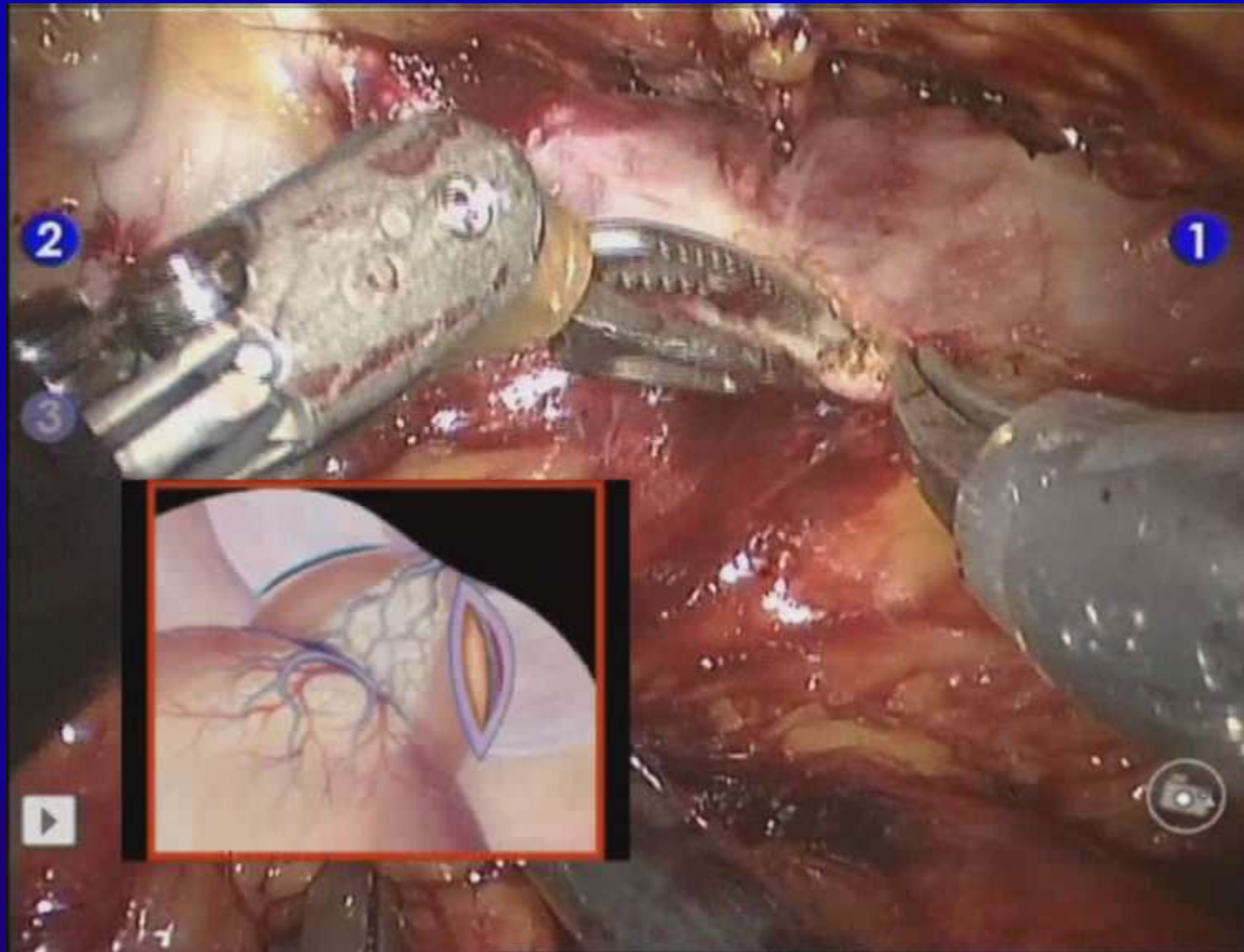
Operative technique (6 steps)

- Exposure and trocars placement
- Initial approach to the N.V.B.
- Exposure of the anterior half of the urethra
- Lateral and posterior dissection of the apico-urethral junction
- Retrograde prostatico-seminal-rectal cleavage
- Final section of the bladder neck and latero-vesical prostatic pedicles

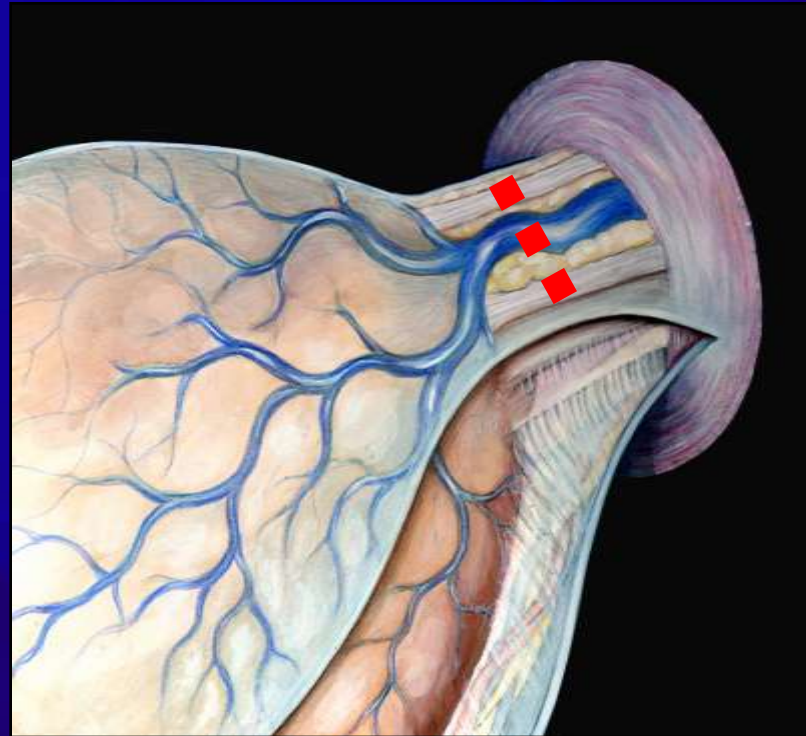
Exposure and trocars placement



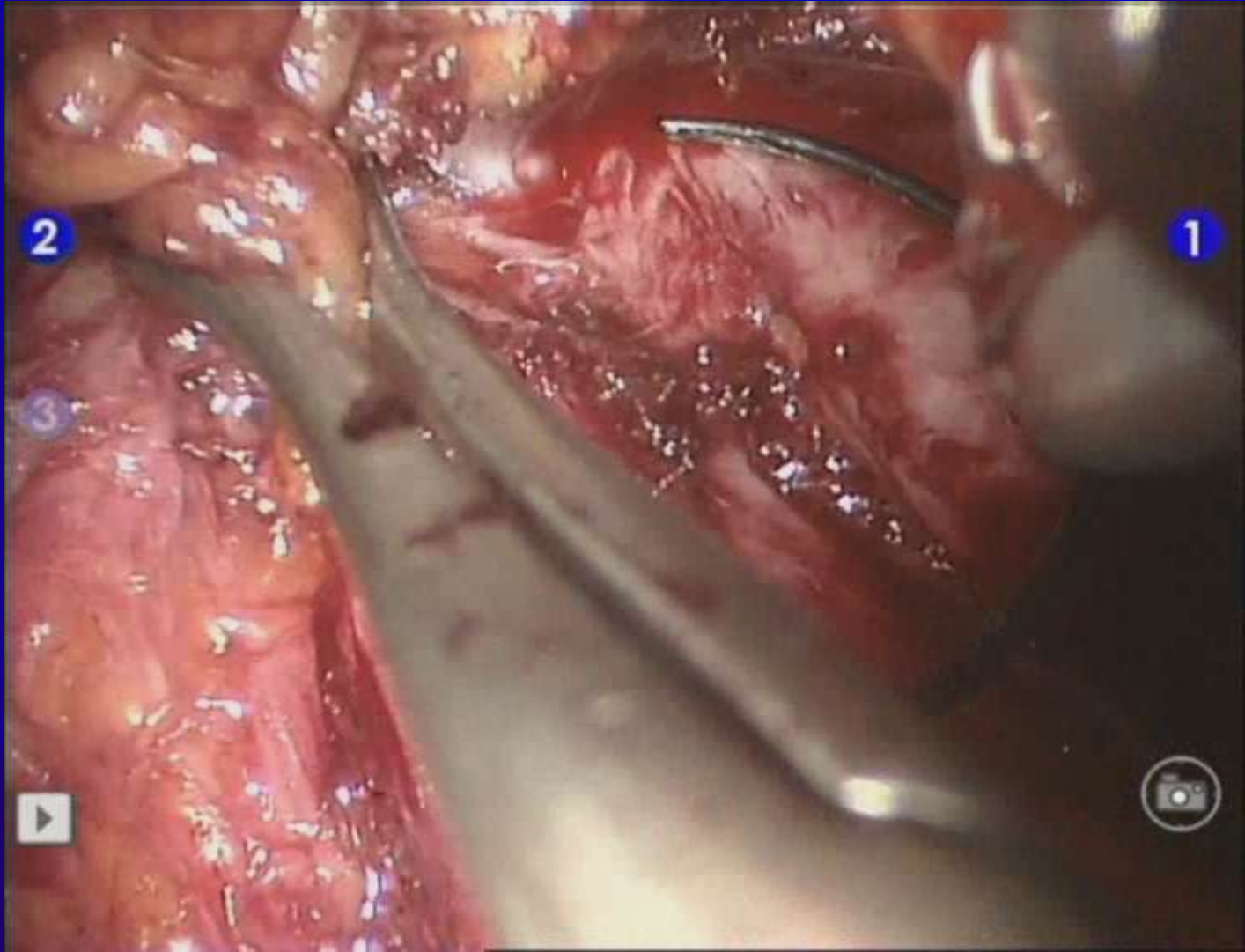
Initial approach to the N.V.B.



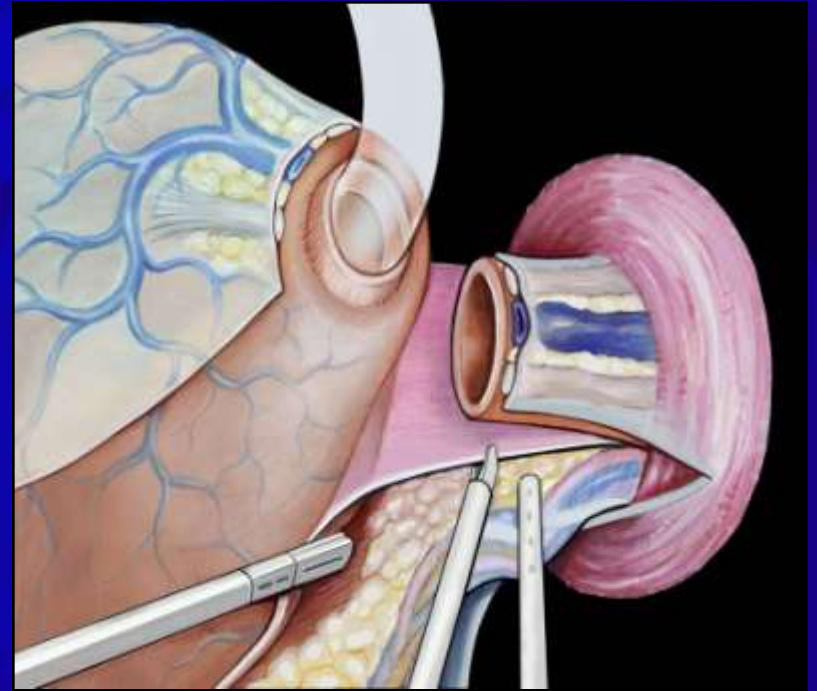
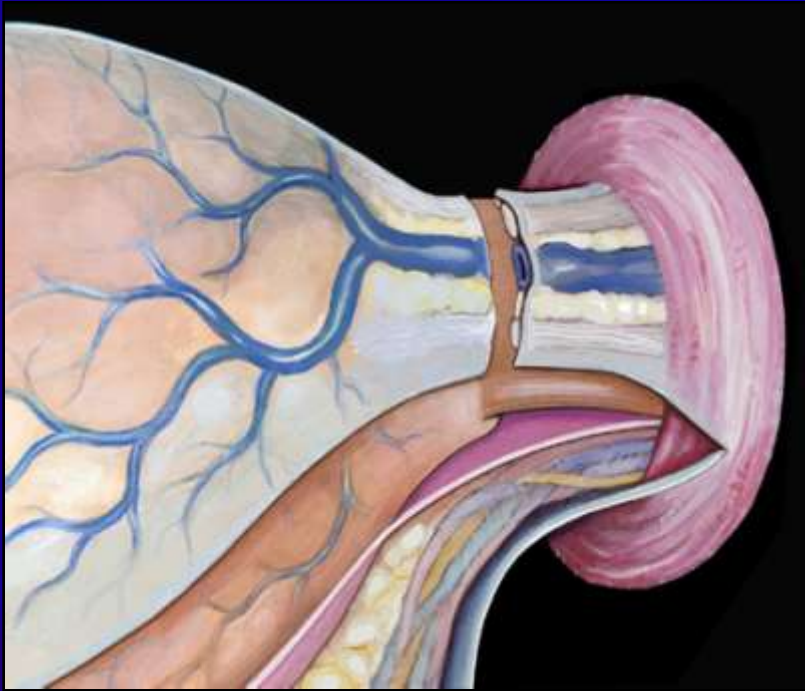
Exposure of the anterior half of the urethra



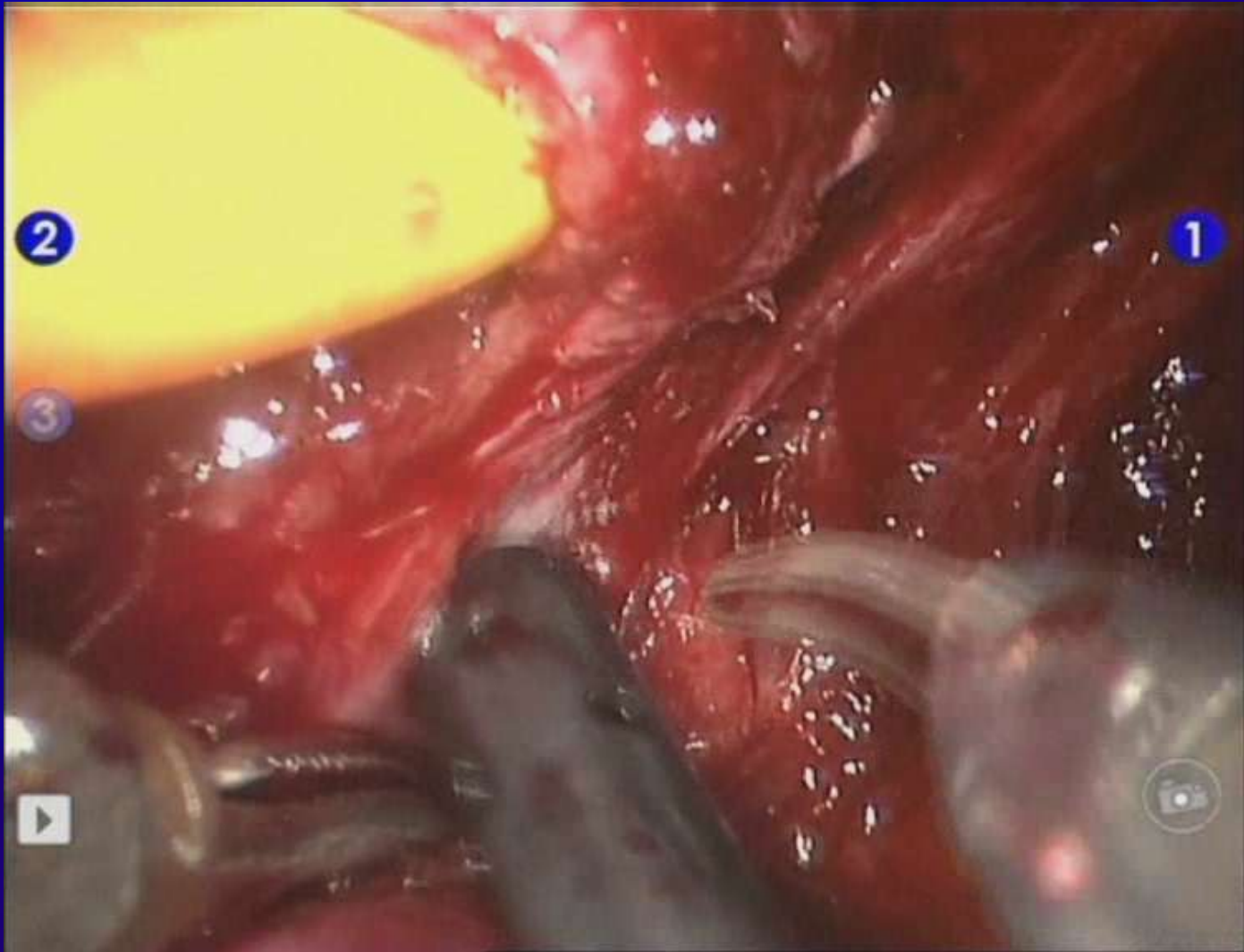
Exposure of the anterior half of the urethra



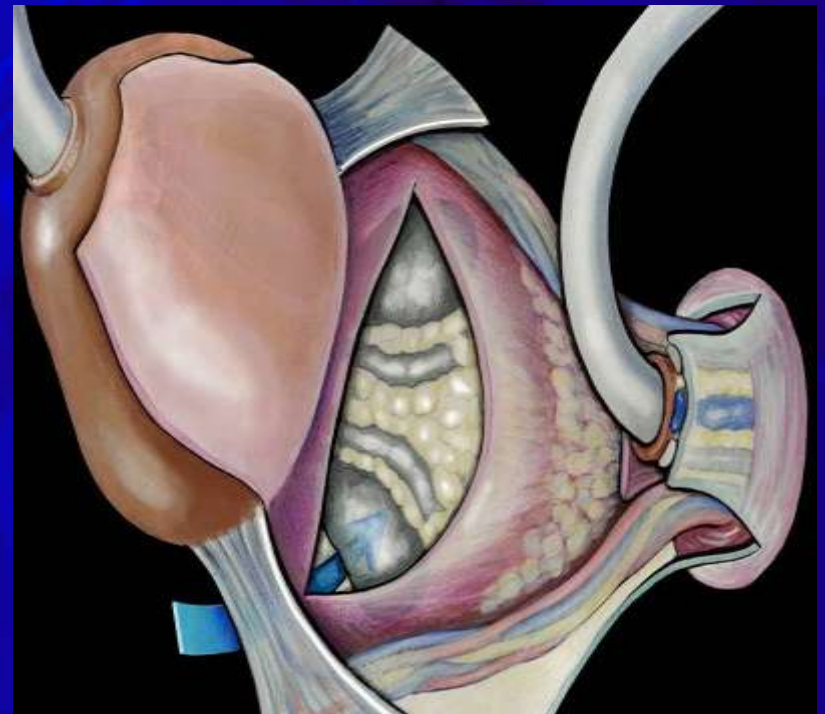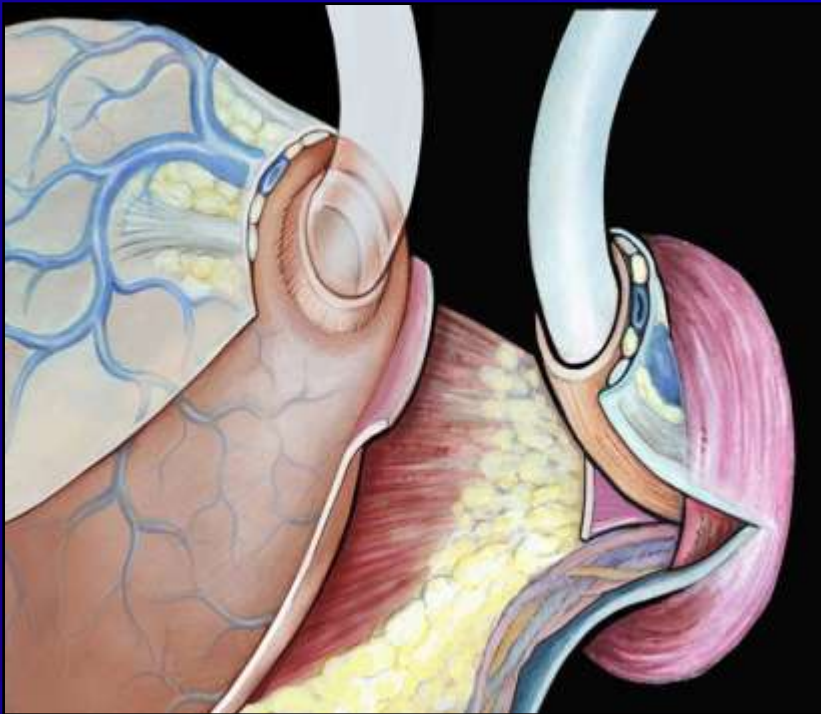
Lateral and posterior dissection of the apico-urethral junction



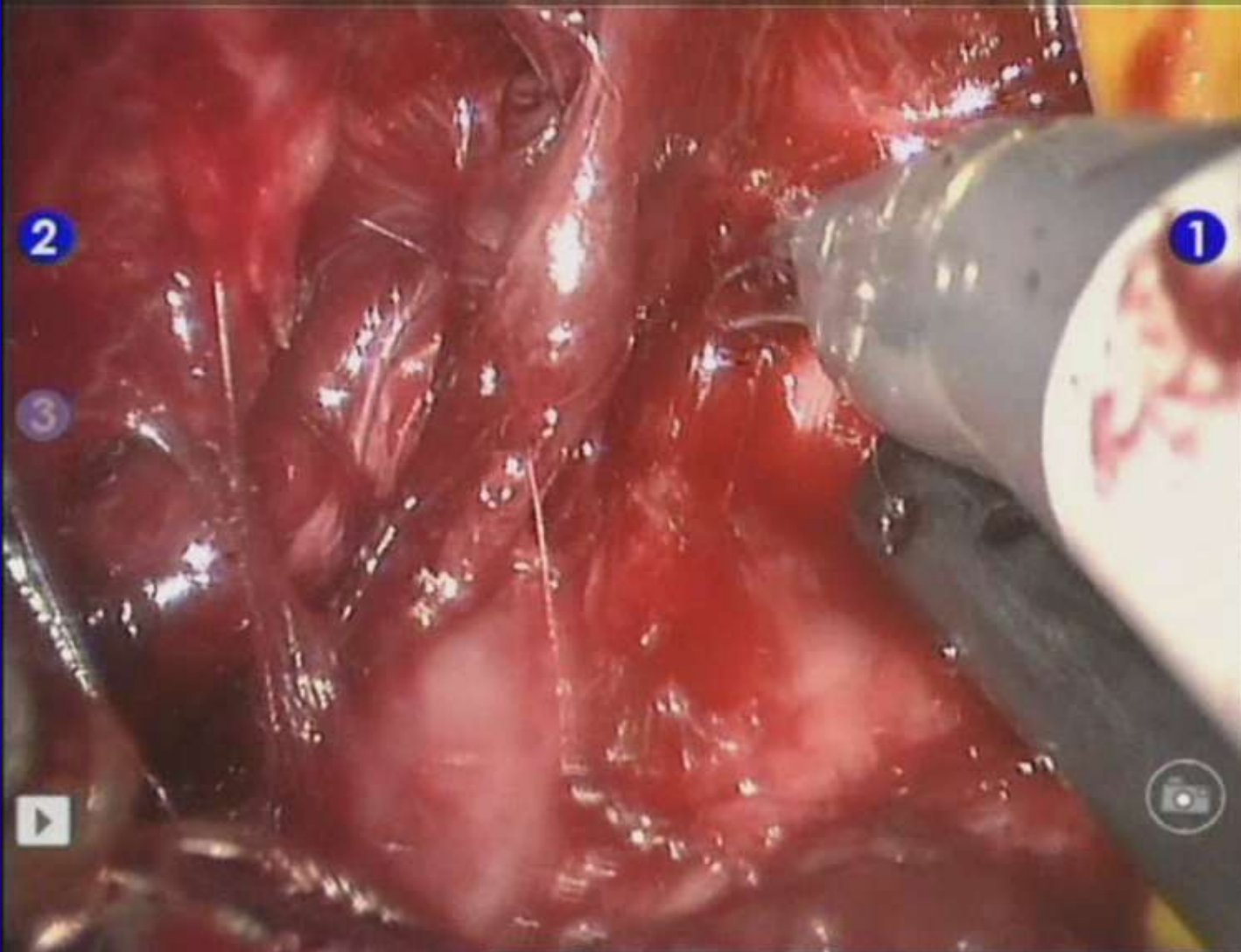
Lateral and posterior dissection of the apico-urethral junction



Retrograde prostatoseminal vesicle cleavage

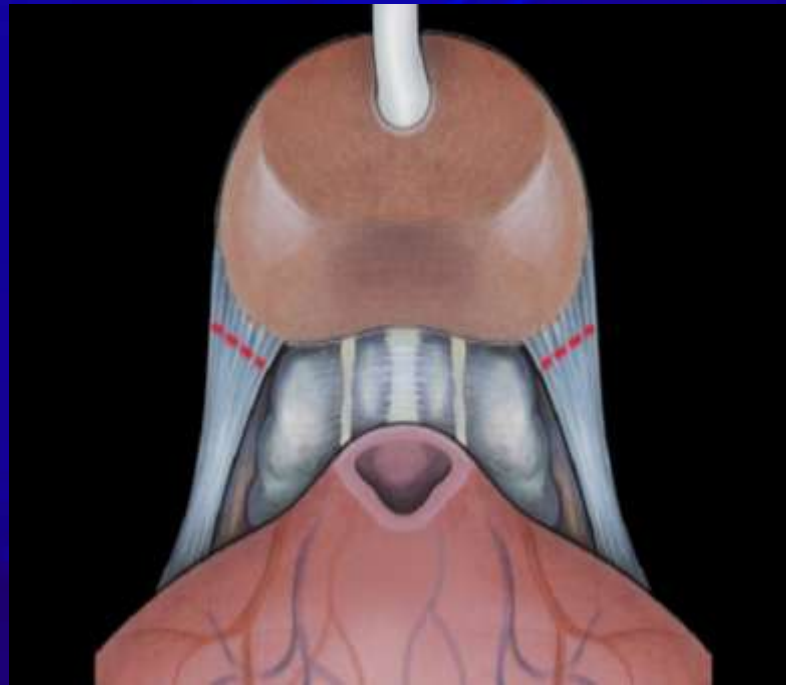


Retrograde prostato-semi-no-rectal cleavage

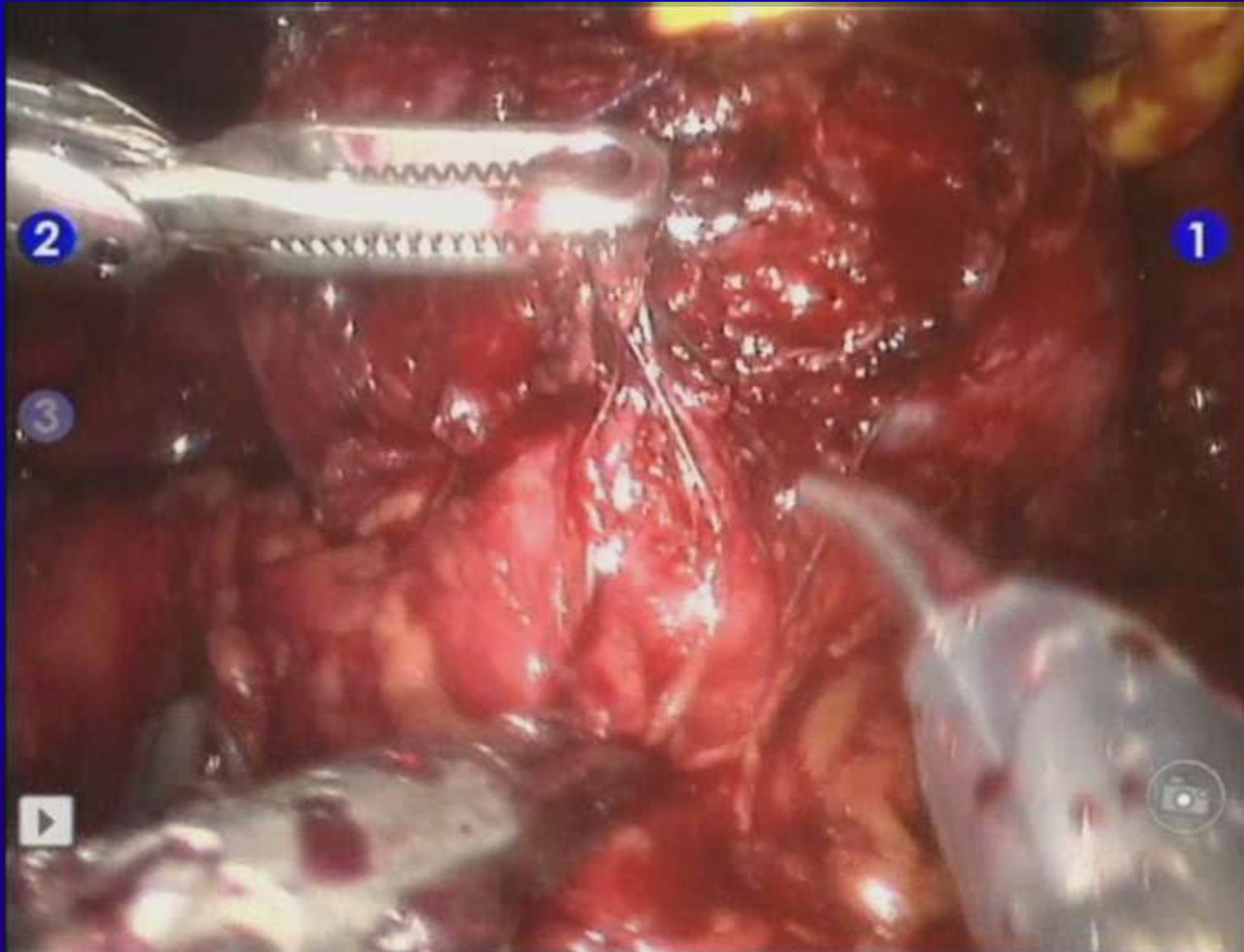

Duration :01:57

Final section of the bladder neck and latero-vesical prostatic pedicles



Final section of the bladder neck and latero-vesical prostatic pedicles

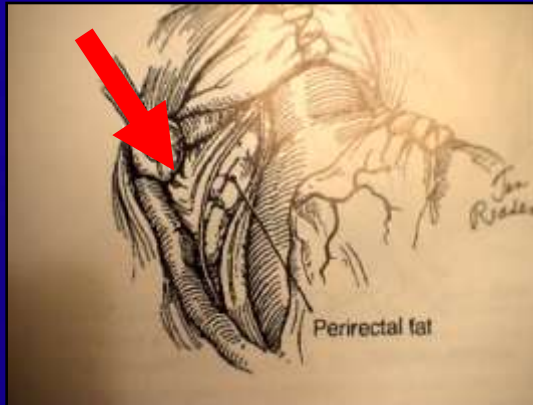


Summary

Three technical supports for the RRELP

Scardino

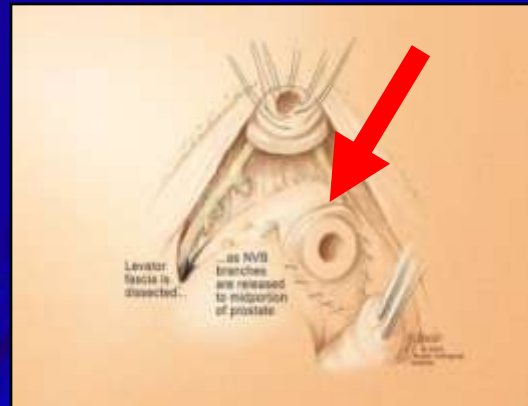
1



Initial lateralisation of the ENVB

Walsh

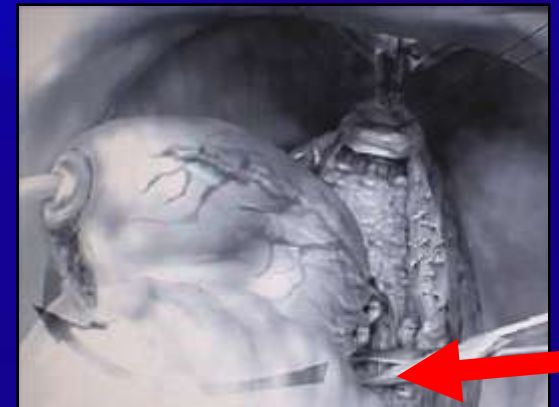
2



Anatomical retrograde dissection of the apex

Barré

3



Subtrigonal dissection of lateral pedicles and SV

