

Carcinoid tumors of the appendix in children: a reminder

Amin J. Barakat¹, David Reese², Geetha Menezes³

1 Clinical Professor of Pediatrics, Georgetown University Medical Center, Washington, D. C., U.S.A.

2 Associate Professor of Pediatrics, Georgetown University Medical Center, Washington, D. C., U.S.A.

3 Pathologist, Inova Fairfax Hospital, Falls Church, Virginia, U.S.A.

key words: carcinoid • appendix

SUMMARY

Background: Carcinoid tumors are rare malignant neuro-endocrine tumors found mainly in the bowel and lung. They are the most common tumors of the appendix. In children, they occur more commonly in white females with a median age of 13 years.

Case Report: We report here, a 14-year-old white female who presented with the clinical picture of acute appendicitis. Carcinoid tumor was diagnosed on histological examination of the removed appendix.

Conclusions: Clinical presentation of carcinoid of the appendix is similar to acute appendicitis, but more commonly it is an incidental finding on appendectomy, abdominal surgery or histological examination of the surgical specimen. Localized disease has an excellent prognosis, and the tumor usually has little metastatic potential. Patients with metastatic carcinoid fare poorly. Clinical awareness and early diagnosis of carcinoid tumor of the appendix are important in preventing morbidity and mortality

BACKGROUND

Carcinoid tumors are rare malignant neuro-endocrine tumors found mainly in the bowel, stomach and lung, and they are the most common tumors of the appendix. Clinical presentation of these tumors is similar to acute appendicitis, but more commonly they are found incidentally on appendectomy, abdominal surgery or histological examination of the surgical specimen. The purpose of this report is to describe a 14-year-old female with carcinoid of the appendix, and to remind pediatricians of this rare tumor, as clinical awareness and early diagnosis are important in preventing morbidity and mortality.

CASE REPORT

The patient is a 14-year-old white female who presented with severe right lower quadrant abdominal pain of one-day duration. She gave history of mild, intermittent abdominal pain for a few weeks, not severe enough to seek medical care. There was no history of flushing, diarrhea, vomiting, urinary symptoms, food allergies, weight loss or fever. Her maternal grandmother had breast cancer; family history was otherwise negative.

Physical examination revealed a healthy looking female with mild distress, a temperature of 100.8 degrees, weight 125 lbs (75th percentile), height 63 in (50th percentile), and blood pressure 110/60. She had severe direct and rebound tenderness in the right lower quadrant. Rectal examination revealed moderately severe tenderness in the area of the appendix, but no masses or blood. She had no hepatosplenomegaly or lymphadenopathy, and the rest of her physical examination was normal.

White blood count was 20,700 with 93% granulocytes, hemoglobin 14.3 gm%, hematocrit 40%, and platelets 178,000/uL. Serum glucose was 100 mg%, urea nitrogen 11 mg%, creatinine 0.7 mg%, calcium 9.8 mg% and normal electrolytes. Urinalysis showed a specific gravity of 1.010, 1+ protein and normal microscopy. Twenty-four-hour urine 5-hydroxyindole acetic acid (5-HIAA) was normal at 4 mg/24 hours. Computerized tomography (CT) of the abdomen with contrast revealed an appendicolith consistent

Author's address: Amin J. Barakat 107 North Virginia Avenue, Falls Church, Virginia 22046, email: aybarakat@aol.com

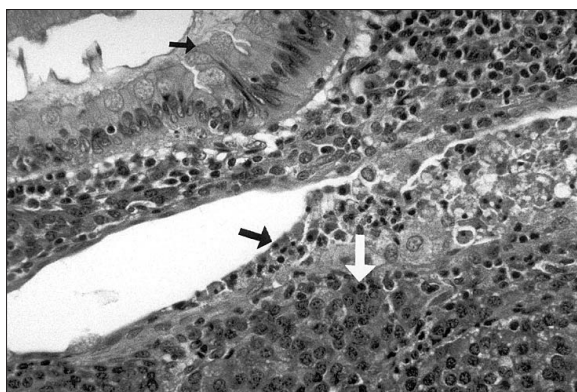


Figure 1. Uniform tumor cells demonstrating a nesting growth pattern (white arrow) are seen surrounding non-neoplastic mucosal glands (smaller black arrow) and associated with acute inflammation (larger black arrow).

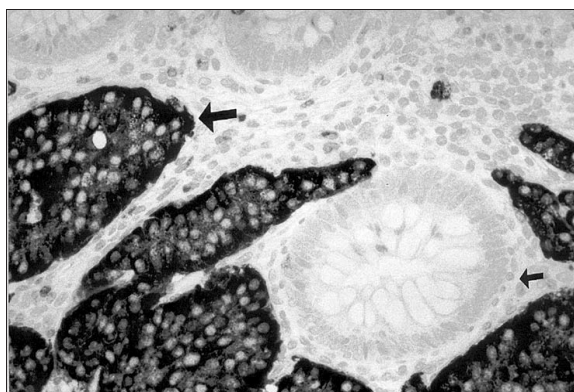

Figure 2. Chromogranin stain demonstrates strong positive staining of tumor cells (larger arrow), and surrounding a non-neoplastic mucosal gland (smaller arrow).

with appendicitis; the rest of the abdominal and pelvic organs were normal. CT of the chest was normal. She underwent a laparoscopic appendectomy. The appendix was inflamed and revealed a carcinoid tumor breaking through the mucosa.

Pathology

The serosal surface of the appendix was covered with a fibrinopurulent exudate. The lumen was dilated and a 1.1 cm, circumscribed, nonencapsulated, firm, tan-yellow nodule was identified within the proximal half of the appendix, located at a distance of 0.6 cm from the surgical resection margin. Microscopic examination revealed a carcinoid tumor composed of solid nests and acini demonstrating uniform cells with a speckled nuclear chromatin pattern (Figure 1). Mitoses were rare and mucinous cells were identified. The tumor involved all layers of the appendiceal wall and extended to the overlying serosal surface. The base of the appendix was free of tumor. Immunohistological analysis demonstrated positive staining of tumor cells for neuroendocrine markers including chromogranin and synaptophysin (Figure 2). An inflammatory cell infiltrate, predominantly composed of neutrophils, was extensively present within periappendiceal tissue.

DISCUSSION

First recognized in 1867, carcinoid tumors are rare malignant neuro-endocrine tumors. It is the most common tumor of the appendix, occurring in 0.226% of appendectomies performed at all ages [1]. Carcinoid of the appendix occurs in 1:100,000 to 169:100,000 children [1,2]. The tumor is more common in white female children with a median age of 12.3–13 years [3–5], but

it has been reported as early as three years of age. Acute appendicitis is more common in pre-teen and teen-age boys, while female to male occurrence in carcinoid of the appendix is 2:1 [4].

Most carcinoid tumors in children arise in the appendix; however, they can also occur in other primary sites including the small intestine, bronchus and others [3]. Clinical presentation of carcinoid of the appendix is similar to acute appendicitis, but it can be an incidental intra-operative finding during appendectomy or other surgical procedures. The majority of tumors are discovered on histological examination of the surgical specimen. Clinical symptoms of carcinoid syndrome including flushing, diarrhea, and wheezing are usually not found except in large tumor mass or distant metastasis [1]. This malignancy should be considered in the differential diagnosis of children, particularly pre-teen females presenting with right lower quadrant pain, persistent or recurrent pneumonia or symptoms of carcinoid syndrome.

The tumor is localized at the apex of the appendix in 75% of cases, in the mid portion in 20% and in the following base in 5% [4]. The median tumor diameter is 6 mm (3–17 mm) [4]; the diameter of the tumor in our patient was 11 mm. Carcinoid tumors located at the tip of the appendix and measuring less than 10 mm usually present with a clinical picture identical to acute appendicitis, while tumors measuring more than 20 mm and located at the base of the appendix may present with clinical signs of peritonitis [5].

Serum chromogranin A is a useful immuno-histochemical marker which is reliable in the diagnosis of various endocrine tumors including carcinoid. Serum chromogranin A, serotonin and its metabolite 5-hydroxyindole acetic acid (5-HIAA) in the urine

should be measured when carcinoid tumors are suspected or when the tumor is diagnosed [1,3]. Urine 5-HIAA is a good marker of endocrine activity of the carcinoid tumor, and the level is significantly higher in patients with metastasis compared with those without metastasis. It is important for the patient to avoid foods high in serotonin such as bananas, tomatoes, pineapple, kiwis and others two days before the test. Octreotide or somatostatin receptor scintigraphy, CT of the lungs and abdomen, and bone scan are indicated to rule metastasis. The principle of the scintigraphy is that the majority of carcinoid tumors carry specific receptors on the cell surface which bind the somatostatin receptor analogue octreotide. Abdominal ultrasonography and angiography are additional supportive tests.

The etiology of carcinoid tumors is unknown. Quaedvlieg et al. [6] found female predominance before age 50, and they attributed this to hormonal influence. Family history in first-degree relatives and birth in large cities seem to be risk factors [7,8]. Karanjawala et al. [9] reported the first account of an individual with ileal carcinoid tumor and nonmosaic complete maternal isodisomy of chromosome 8. Kytola et al. [10] found that alterations of the SDHD gene seem to be involved in the tumorigenesis of midgut carcinoids.

Tumors localized to the tip of the appendix and found on incidental surgery are cured with appendectomy alone. Caution during appendectomy should be observed to avoid possible damage to the tumor. Tumors larger than 2 cm and invading serosa and mesoappendix without metastasis may be treated with a cecectomy [5]. Ileocecal resection may be indicated in patients where the tumor has infiltrated tissue beyond the cecum and in patients with incomplete gross resection. Right hemicolectomy is restricted to rare conditions such as very large tumors and vascular involvement.

Except for signet ring cell carcinoma and malignant carcinoid, the extent of disease at the time of diagnosis is a more important predictor of survival than histology [11]. Metastasis of carcinoid of the appendix occurs in 1.6% of cases [6]. Metastasis of carcinoid of the appendix is very rare in children probably because most reported tumors in this age group are small and less aggressive. Metastatic, however, has been reported as early as age 5 [12]. The tumor in our patient extended through the entire diameter of the appendix and involved all layers of the wall to the overlying serosal surface, but there was no distant metastasis. All patients should be closely studied

with CT of the abdomen and chest, bone scan and serum serotonin and chromogranin A determination to detect early metastasis. Curative therapy for non-resectable and metastatic carcinoid remains undefined. Administering octreotide and its synthetic analogs are palliative for the control of symptoms, and may contribute to increased survival in patients with distant metastasis [6]; however, there is no evidence that they produce tumor stasis [3,13].

CONCLUSIONS

Carcinoid tumors are rare, but are the most common tumors of the appendix. Clinical presentation is similar to acute appendicitis, but more commonly the tumor is an incidental finding on appendectomy. Localized disease has an excellent prognosis. The tumor usually has little metastatic potential, but patients with metastatic carcinoid fare poorly. Pediatricians should be aware of carcinoid tumors of the appendix since early diagnosis of these tumors is important in preventing morbidity and mortality.

REFERENCES:

1. Doede T, Foss HD, Waldschmidt J: Carcinoid tumors of the appendix in children—epidemiology, clinical aspects and procedure. *Eur J Pediatr Surg*, 2000; 10: 372-7
2. D'Aleo C, Lazzareschi I, Ruggiero A, Riccardi R: Carcinoid tumors of the appendix in children: two case reports and review of the literature. *Pediatr Hematol Oncol*, 2001; 18: 347-51
3. Spunt SL, Pratt CB, Rao BN et al: Childhood carcinoid tumors: the St Jude Children's research hospital experience. *J Pediatr Surg*, 2000; 35: 1282-6
4. Prommegger R, Obrist P, Ensinger C et al: Retrospective evaluation of carcinoid tumors of the appendix in children. *World J Surg*, 2002; 26: 1489-92
5. Pelizzo G, La Riccia A, Bouvier R, Chappuis JP, Franchella A: Carcinoid tumors of the appendix in children. *Pediatr Surg Int*, 2001; 17: 399-402
6. Quaedvlieg PFHJ, Visser O, Lamers CBHW et al: Epidemiology and survival in patients with carcinoid disease in the Netherlands. An epidemiological study with 2391 patients. *Ann Oncol*, 2001; 12: 1295-300
7. Hemminki K, Li X: Incidence trends and risk factors of carcinoid tumore: a nationwide epidemiologic study from Sweden. *Cancer*, 2001; 92: 2204-10
8. Modlin IM, Lye KD, Kidd M: A 5-decade analysis of 13, 715 carcinoid tumors. *Cancer*, 2003; 15: 934-59
9. Karanjawala ZE, Kaariainen H, Ghosh S et al: Complete maternal isodisomy of chromosome 8 in an individual with an early-onset ileal carcinoid tumor. *Am J Med Genet*, 2000; 93: 207-10
10. Kytola S, Nord B, Elder EE et al: Alterations of the SDHD gene locus in midgut carcinoids, Merkel cell carcinomas, pheochromocytomas, and abdominal paragangliomas. *Genes Chromosomes Cancer*, 2002; 34: 325-32

11. *McCusker ME, Cote TR, Clegg LX, Sobin LH: Primary malignant neoplasms of the appendix: a population-based study from the surveillance, epidemiology and end-results program, 1973–1998. Cancer, 2002; 94: 3307-12*
12. *Volpe A, Willert J, Ihnken K et al: Metastatic appendiceal carcinoid tumor in a child. Med Pediatr Onc, 2000; 34: 218-20*
13. *Rohaizak M, Farndon JR: Use of octreotide and lanreotide in the treatment of symptomatic and non-resectable carcinoid tumors. ANZ J Surg, 2002; 72: 635-8*