

classification of VVV

kees waaldijk

babbar ruga fistula hospital

classification of VVF

closing mechanism

Figure 58 Closing mechanism

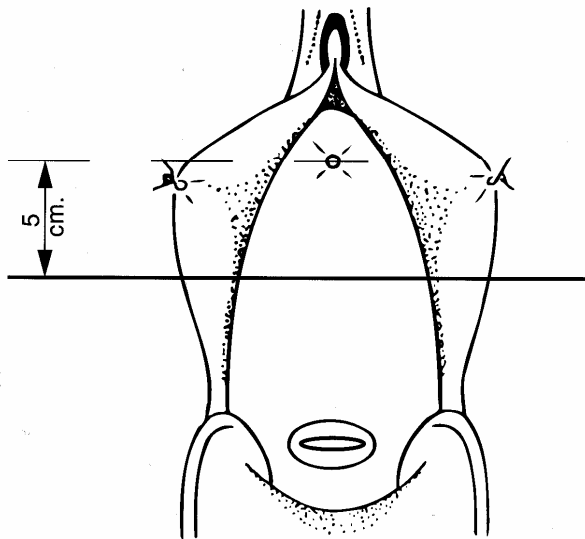


Figure 58-a Closing mechanism: frontal

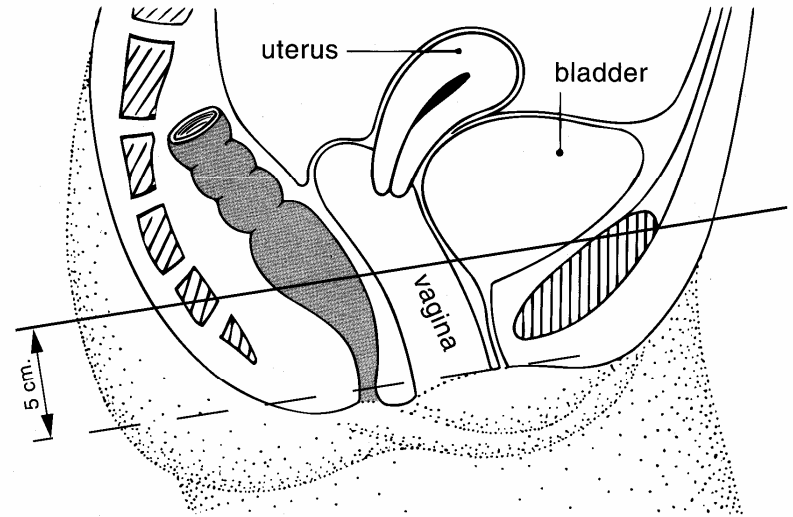


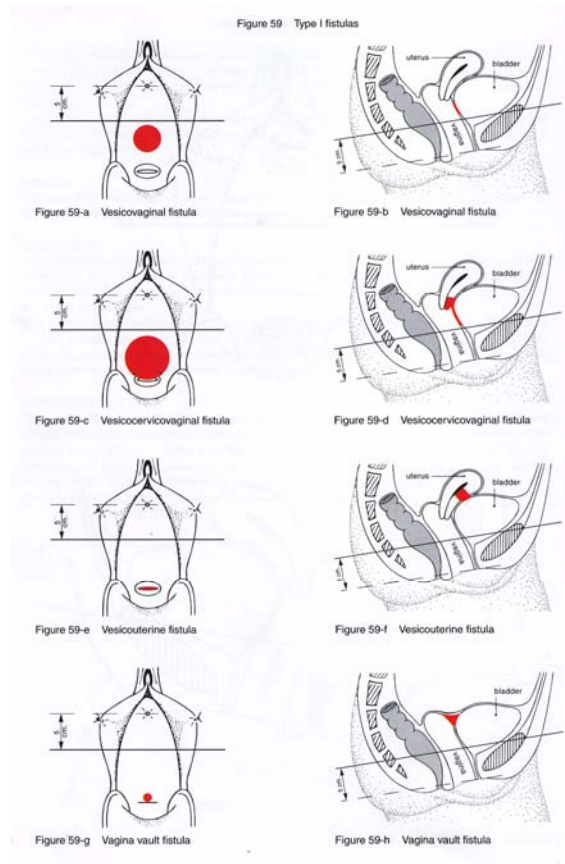
Figure 58-b Closing mechanism: sagittal

classification

according to anatomic/physiologic location

- type **I**: not involving closing mechanism
- type **II**: involving closing mechanism
 - **A**: not involving (sub)total urethra
 - **a**: without circumferential defect
 - **b**: with circumferential defect
 - **B**: involving (sub)total urethra
 - **a**: without circumferential defect
 - **b**: with circumferential defect
- type **III**: miscellaneous, e.g. ureter fistula

type I fistulas



type IIAa fistulas

Figure 60 Type IIAa fistulas

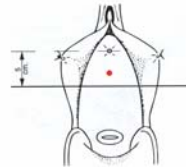


Figure 60-a Urethrovaginal fistula

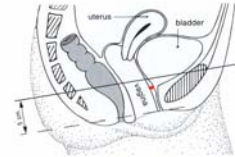


Figure 60-b Urethrovaginal fistula

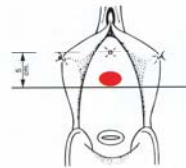


Figure 60-c Urethrovaginal fistula

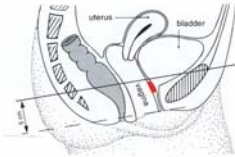


Figure 60-d Urethrovaginal fistula

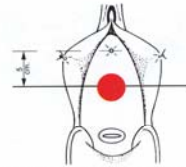


Figure 60-e Urethrovaginal fistula

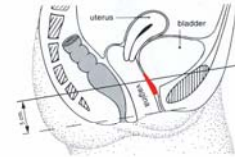


Figure 60-f Urethrovaginal fistula

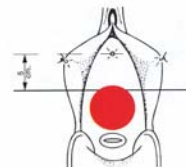


Figure 60-g Urethrovaginal fistula

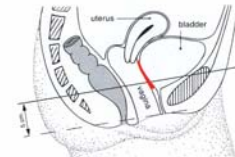


Figure 60-h Urethrovaginal fistula

type IIAb fistulas

Figure 61 Type IIAb fistulas

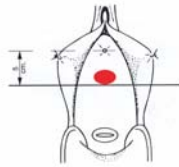


Figure 61-a Urethrovaginal fistula

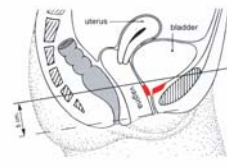


Figure 61-b Urethrovaginal fistula

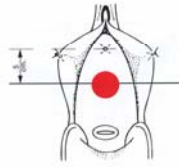


Figure 61-c Urethrovaginal fistula

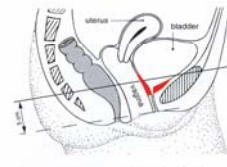


Figure 61-d Urethrovaginal fistula

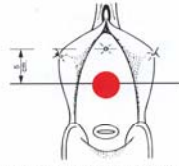


Figure 61-e Urethrovaginal fistula

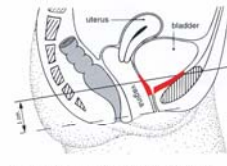


Figure 61-f Urethrovaginal fistula

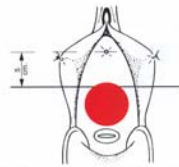


Figure 61-g Urethrovaginal fistula

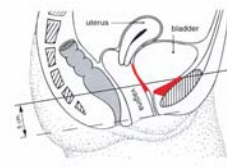


Figure 61-h Urethrovaginal fistula

type IIBa fistulas

Figure 62 Type IIBa fistulas

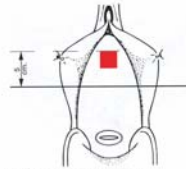


Figure 62-a Urethrovaginal fistula

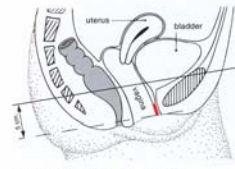


Figure 62-b Urethrovaginal fistula

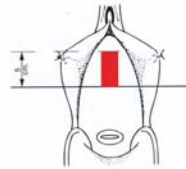


Figure 62-c Urethrovaginal fistula

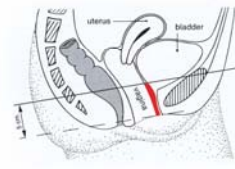


Figure 62-d Urethrovaginal fistula

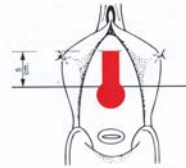


Figure 62-e Urethrovaginal fistula

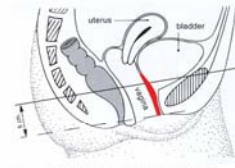


Figure 62-f Urethrovaginal fistula

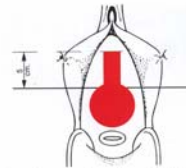


Figure 62-g Urethrovaginal fistula

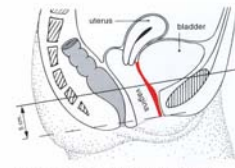


Figure 62-h Urethrovaginal fistula

type IIBb fistulas

Figure 63 Type IIBb fistulas

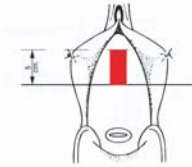


Figure 63-a Urethrovesicovaginal fistula

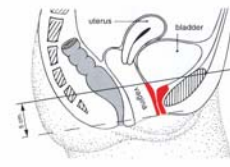


Figure 63-b Urethrovesicovaginal fistula

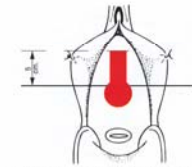


Figure 63-c Urethrovesicovaginal fistula

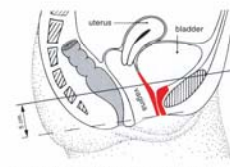


Figure 63-d Urethrovesicovaginal fistula

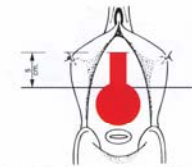


Figure 63-e Urethrovesicovaginal fistula

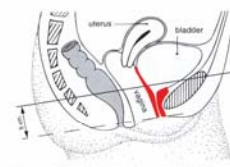


Figure 63-f Urethrovesicovaginal fistula

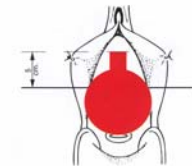


Figure 63-g Urethrovesicocervicovaginal fistula

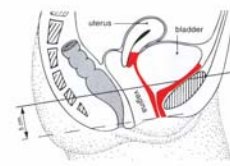


Figure 63-h Urethrovesicocervicovaginal fistula

classification

according to size

- **small** < 2 cm
- **medium** 2-3 cm
- **large** 4-5 cm
- **extensive** ≥ 6 cm

classification of VVF

according to size

